V.29

DOMINA RERUM SAPIENTIA

Library
of the
Academy of Medicine
Toronto.
14083

Presented by

R. A. Reeve Fund.
1923

The Ophthalmic Review

THE

Ophthalmic Review

A Record of Ophthalmic Science.

Editor:
J. B. LAWFORD
(London).

Assistant Editor:
E. ERSKINE HENDERSON
(London).

Vol. XXIX., 1910.

LONDON:
SHERRATT & HUGHES
Manchester: 34 Cross Street
1910.

LIBRARY
NOV 2 1 2001
UNIVERSITY OF TORONTO

INDEX.

Items set in Capitals are Original Articles.

A.

Accommodation, Helmholtz theory of, 117.
Adam. Action of dionin, 63; ectropion of iris, 83; glioma, 352.
ALEXANDER. AN ERECT IMAGE OF THE FUNDUS BY INDIRECT OPHTHALMOSCOPY, 193.
Alling. Transplantation of fat in Tenon's capsule, 199.
Alypin, 60.
Amaurosis with cupping of disc in youth, 191.
Angiolella. Sero-therapy, paraspecific, 186.
Anterior chamber, formation of fistula of, 48.
ANTERIOR CHAMBER, DELAYED REFORMATION OF, 257, 266.
Atrophy, complicated hereditary, 45.
Atrophy, optic, with oculo-motor palsy, 93, 256.
Atrophy, optic, following use of orsudan, 190, 223.
Atrophy optic with oxycepaly, 126.
Atlas of external diseases of the eye, 219.

B.

Bacillus perfringens, infection from, 166.
Bacteriology of conjunctiva after removal of lacrimal sac, 21.
Bacteriology of panophthalmitis, 128.
Batten, F. E. Bilateral ophthalmoplegia externa, 90.
Beauvois. Vertical and oblique hand-writing, 123.
Behr. Complicated hereditary family optic atrophy, 45.
Bentzen. Iridencleisis for glaucoma, 247.
Best. Hemianopia, 304.
Birsch-Hirschfeld. Action of light of short wave length, 184.
Blair. Errors of refraction, 188.
Bonsignorio. The absorption of senile cataract, 146.
Bordley and Cushing. Colour fields in brain tumour, 142.
Botlazzi and Scalinci. Chemico-physical investigation of lens, 298.
Brain and spinal cord, surgery of, 158.
Brain and sympathetic, 83.
BREWERTON. TUBERCULOUS IRIDO-CYCLITIS, 225.
Bribach. Central canal of vitreous, 341.

Buphthalmos, congenital malformations in, 91, 180, 206.
Buphthalmic eye, subconjunctival rupture of, 221.
Bonner. Hypopyon keratitis treated with pyocyanese, 192.
Burge. Ash of normal and cataractous lens, 71.
Buri. Is chalazion acne, 215.
Butler Harrison. Delayed Reformation of Anterior Chamber, 257.

C.

Cabannes. Buphthalmos, 180; trephining in cerebral tumour, 26.
Calderaro. Bacteriology of conjunctiva after removal of lacrimal sac, 21.
Caspar. Annular contusion lesions of the lens, 23.
Cataract, anterior cortical, 255.
Cataract congenital, 126.
Cataract caused by electric currents, 50.
Cataract operation, corneo-conjunctival bridge in, 15.
Cataract operation in old people, 245.
Cataract operation in unripe and stationary conditions, 143.
Cataract senile, absorption of, 146.
Cataract senile, beginning in lower part of lens, 145.
Cataract, Smith's operation for, 244.
Cerebro-spinal meningitis, optic tract in, 316.
Cerebral visual tracts, pathology of, 107.
Chesnau. Unilateral ophthalmomalacia in Graves' disease, 370.
Choked disc, genesis of, 288.
Choroid, endothelioma of, 256.
Choroid, sarcoma of, 89.
Choroiditis, family, 31, 189, 224.
Cilia in the anterior chamber, 63.
Ciliary body, behaviour of to antibodies, 214.
Clark and Tyson. Pontine lesions with seventh nerve palsy, 251.
Clarke. Optic atrophy following use of orsudan, 190, 223.
Clausen. Transplantation of the cornea, 159.
Clausnizer. Is monocular vision injurious to eye?, 79.
Cluckie. Corneo-conjunctival bridge in cataract extraction, 15.
Coats. Marginal Keratectasia, 381; Colloid Excrescences of Bruch's membrane, 382; Coloboma of lens and iris, 383.
Colour blindness, 157.
Colour Blindness, Congenital, 65, 78.
Colour fields in cerebral tumour, 142.
Connective tissue formation on the disc, 95.
Conjunctiva, epithelioma of, 176.
Conjunctiva, granuloma of, 90, 95.

Conjunctiva, pigmentation of, 64.
Conjunctiva, tumour of, 64.
Conjunctivitis, forms of, 30, 56, 60.
Conjunctivitis, histology of gonorrhœal, 139.
Conjunctivitis, Parinaud's, 379.
Cords. The action of Scharlach red in corneal disease, 230.
Cornea, immunisation of, 63.
Cornea, epithelioma of, 96.
Cornea, peripheral and central bulging of, —.
Cornea, ring abscess of, 253.
Cornea, vertically elliptical in old keratitis, 127.
Corneal disease, scharlach red in, 230.
Corneal epithelium, regeneration of, 296.
Corneal opacities, 29, 74, 95.
Corneal ulceration, bacteriology of, 376.
Coutela and Velter. Traumatic hemianopia, 234.
Cyclitis with bilateral parotitis, 94.

D.

Dark adaptation, injury to, 248.
Dazzling, 181.
Dehenne. Measurement of visual acuity, 116.
Delord and Revel. Epithelioma of the bulbar conjunctiva, 176.
Deschamps. Sero-therapy of rheumatic disease of the eye, 300.
Deutschmann. Detachment of the retina, 203; pupillary reflex, 375.
Diabetes, infection liability in, 307.
Diabetes, influence of in operations, 168, 170.
Diabetic lipæmia, fundus in, 288.
Diabetic origin of toxic amblyopia, 199.
Dionin, action of, 63.
Diphtheria bacillus, differentiation of, 175.
Doyne. Conjunctivitis, 30; myopic degeneration of the lens, 30; iritis, 31; family choroiditis, 224.

E.

Edridge-Green. Colour-blindness, 157.
Electric shock and cataract, 314.
Elschnig. Researches on sympathetic ophthalmia, 275.
Elschnig and Ulbrich. Post-operative inflammation of eye, 131.
Elliott. Glaucoma, a filtering cicatrix in, 26.
Embolism of a cilio- retinal artery, 204.
Exenteratio orbito-sinualis, 148.
Exophthalmos and facial deformity, 88.

Extirpation of the tarsus, 11.
Eye-glasses, orbital frame for, 29.
Eye-hygiene, importance of, 319.

F.

Fat transplantation, 61.
Filtration of intraocular fluid, 50.
Fischer. Nature of glaucoma, 72; corneal opacities, 74.
Fisher. Differentiation of diphtheria bacillus, 175.
Fisher, J. H. Congenital word blindness, 192.
Flemming. Trachoma bodies, 87.
Foreign bodies in the interior of the eye, 74, 220, 365.
Forti. The fields of vision during gestation, 240.
Foster. Reflex asthenopia from nasal pressure, 18; congenital blenorrhœa of the lacrimal sac, 262.
Freysz. Cataract caused by strong electric current, 50.
Fritsch, Hofstätter, and Lindner. Trachoma researches, 371.

G.

General paralysis, vision in, 185.
Gestation, fields of vision in, 240.
Glaucoma, pathology of, 72, 84, 114.
Glaucoma, operations for, 26, 191.
Glaucoma Problems, 289.
Glaucoma secondary to swelling of the lens in senile cataract, 367.
Glioma, 352.
Goldzieher. Treatment of pannus, 135.
Golovine. A new type of orbital inflammation, 269; exenteratio orbito-sinualis, 148.
Gonorrhœal subconjunctivitis, 14.
Graves' disease, acute unilateral ophthalmomalacia, 370.
Greeff. Atlas of external diseases of the eye, 219.
Gunn, R. M. Obituary notice, 1.
Gutmann. Eye symptoms in accessory nasal sinus disease, 160.

H.

Hæmorrhage, subretinal, 127.
Halben. Myopia as a pressure deformity, 284.
Hamburger. Circulation of intraocular fluid, 63, 311; acute glaucoma, 83.
Handmann. The beginning of senile cataract in lower part of lens, 145.
Hand-writing vertical and oblique, 123.

Hayashi. Infection liability in diabetes, 307; pathology of phlyctens, 10.
Heilborn. Eye hygiene and the state, 319.
Hemianopia, 234, 335, 351.
Hemiachromatopsia, 287.
Hepburn. Xerosis and night blindness, 197.
Herrfordt. Gonorrhœal subconjunctivitis, 14.
Herbert. A new operation for glaucoma, 191.
Herzog. The trachoma organism, 318.
Hess. The yellow colouration of the lens, 37.
Hessberg. Congenital colour blindness, 78.
v. Hippel. Deutschmann's serum, 12.
Hirsch. An ophthalmic case book, 59.
Hird Beatson. Optic neuritis in cerebral tumour, 374
Hoeg. Annular contusion lesion of lens, 23.
Horsley. Optic neuritis, 195.
Hutchinson. Syphilis, 82.

I.

Iris, hetero-chromia of, 190.
Iris, ectropion of, 83.
Iris, neoplasm of, 384.
Iris, superficial atrophic areas of, 88.
Iris, unusual yellow patches in, 222.
Iritis, 31, 221.
Ionisation, 207.
Intraocular fluid, circulation of, 63, 83, 311.

J.

Jacqueau. Family keratitis, 150.
Jackson. Measurement of Low Degrees of Nystagmus, 4; glaucoma, 114.
James. Panophthalmitis due to a Gas-forming Organism, 161; a Case of Hemianopia, 335.
Juler. Congenital Total Colour Blindness, 65; Neoplasm of Iris, 384.
Jusélius. Regeneration of the corneal epithelium, 296.

K.

Karpus and Kreidl. The brain and sympathetic, 83.
Keratectasia, Marginal, 381.

Keratitis, family, 150.
Kerato-conus, congenital defects in, 206.
Kilkelly. Smith's operation for cataract, 244.
de Kleijn. Optic nerve in nasal sinus disease, 301.
Konoto. Cataract from electric shock, 314.
Köllner. Optic nerve in orbital tumours, 62; pigmentation of conjunctiva, 64; hemiachromatopsia, 288.
Koster. Drainage between lacrimal sac and nasal cavity, 118.
Krause. Surgery of brain and spinal cord, 158.

L.

Lacrimal gland, tumours of, 32, 64, 89, 223.
Lacrimal sac, congenital blennorrhœa of, 262.
Lacrimal sac, drainage of into nasal cavity, 118.
Lafon and Bonnet. Voluntary nystagmus, 218.
Landman. Conjunctivitis, a form of, 56.
Lapersonne and Cantonnet. Pituitary tumours without acromegaly, 200.
Lauber and Adamuk. Lipoid in albuminuric retinitis, 155.
Lawford. Optic atrophy and oculo-motor palsy in pituitary tumour, 93, 256.
Lens, ash of normal and cataractous, 71.
Lens, annular contusion opacity of, 23.
Lens, chemico-physical investigation of, 298.
Lens, yellow colour of, 37.
Lenses, prescription of spherical, 120.
Lenz. Pathology of cerebral visual tracts, 107.
Leukine, action of, in ophthalmias, 172.
Levinsohn. Exterior muscles of the eye and intraocular tension, 220; Corpora quadrigemina and pupillary reflex, 57; choked disc, 288.
Lewis. Ophthalmic origin of otic disturbances, 16.
Light, Injurious Effects, 97, 158, 184.
Lindner. Trachoma bodies, 372.
Lohmann. Genesis of myopia, 243.
Löwenstein. Bacteriology of corneal ulcers, 376.
Lymph currents of the eye, 63.

M.

MacMullen. The Injurious Effects of Light on the Eye, 97.
McNeill. Tuberculin reactions, 76.
Mackay. Intrafascicular endothelioma of choroid, 2665.
Macula, hole at, 94.
Macula, hæmorrhage at, 88, 255, 29.

Majewski. Scotoma helioplegic, 272.
Martindale and Westcott. The extra pharmocopeia. 317.
Mayer. The prescription of spherical lenses, 120.
Maynard. Increased intra-ocular tension in epidemic dropsy. 198.
Mayou. Ophthalmic operation, 82; sarcoma of orbit, 31; buphthalmos, 91; sarcoma of lacrimal gland, 32.
Medical Annual, 1910, 188.
Meller. Embolism of cilio-retinal artery. 204; intra-ocular sarcoma and sympathetic inflammation, 40; sclerectomy, 109.
Microscopical anatomy of eye, 154.
Mongolian imbeciles, 309.
Monocular vision and injury to eye, 79.
Morax. Ocular metastases in staphylococcal infections, 346.
Munro. Myopia Developing at 26, 265.
Mydriasis and glaucoma after needling for high myopia. 127
Mydriasis persistent, 125.
Myopia as a pressure deformity, 284.
Myopia Developing at the Age of 26, 265.
Myopia, genesis of, 243.
Myopia, High, the Operative Treatment of 321.
Myopic lens degeneration. 30.
Myosis transient associated with headache, 126.

N.

Nasal pressure and reflex asthenopia, 18.
Nasal sinus disease and eye symptoms, 160, 301, 343.
Natanson, tubercle of posterior segment of eye, 267.
Neurofibroma from frontal nerve, 179.
Nicati. Ocular physiology, 121.
Nystagmus and Formic Acid, 229. 340.
Nystagmus, the Measurement of Low Degrees of, 4.
Nystagmus, voluntary, 218.

O.

Obstruction of inferior temporal branch of central artery, 96.
Ohlemann. Miner's Nystagmus and Formic Acid, 340.
Opsonin-Technique in ophthalmology, 124.
Ophthalmic operations, 82.
Ophthalmic origin of optic disturbances, 16.
Ophthalmological Society of Berlin. 62, 83, 158, 220, 255, 287.

Ophthalmological Society of the United Kingdom, 28. 88, 125, 189, 221, 381.
Ophthalmoplegia bilateral total, 19.
Ophthalmoplegia externa bilateral in an infant, 90.
Ophthalmo-diaphanoscopy, 160.
Ophthalmoscope, a New Simple, 193.
Ophthalmoscope without reflexes, 287.
Ophthalmoscopy Indirect, Erect Image of the Fundus by, 193.
Optic nerve affections in tumours of the orbital wall, 62.
Optic neuritis in cerebral tumour, 26, 195, 197, 374.
Orbit, sarcoma of, 31.
Orbit, secondary schirrus of, 223.
Orbit, tumours of, 151.
Orbital inflammation, a new form of, 269.
Oreste, Infection by bacillus perfringens, 166.

P.

Paderstein. Foreign body in lens, 220.
Pagenstecher. Kerato-conus, congenital defects in, 206.
Panophthalmitis due to a Gas-forming Organism, 161.
Paralysis of external rectus in an infant, 189.
Paralysis of external rectus with herpes ophthalmicus, 159.
Paterson. A Case of Congenital Paralysis of Third Nerve with Cyclical Contraction of Pupil, 129.
Papilla, swelling near, 96.
Pascheff. Origin of trachoma, 133.
Paton. Optic neuritis in cerebral tumour, 197.
Pearce, Rankin, and Ormond. Mongolian imbeciles, 309.
Percival. Miner's Nystagmus and Formic Acid, 229.
Pharmocopeia, the extra, 317.
Physiology ocular, 121.
Phlyctens, pathology of, 10.
Pigmentation of one eye, 28.
Pituitary body, visual disturbances in tumours of, 93, 190, 200, 256.
Polariscope for testing colour vision, 383.
Pontine lesions and seventh nerve palsy, 251.
Post-operative inflammation, 131.
Priestley Smith. Glaucoma Problems, 289, 353; A New Simple Ophthalmoscope, 33.
Ptosis, operation for, 315.
Puerperal amaurosis, 238.
Pupil, voluntary dilatation of, 159.

Pupillary reflex and corpora quadrigemina, 57.
Pupillary reflex, unusual phenomena in, 375.
Pyocyanese in keratitis, 192.

R.

Raynaud's disease, retinal hæmorrhage in, 223.
Reber. Toxic amblyopia in diabetics, 199.
Refraction, errors of, 188.
Retina, detachment of, 203.
Retinal changes, traumatic, 89, 95.
Retinal disease with massive exudation, 125.
Retinal disease, an unusual form of, 94.
Retinal naevi, 28.
Retinitis albuminuric, lipoid in, 155; meaning of degeneration spots in, 368.
Retrobulbar neuritis, etiology of, 59.
Rheumatic eye affections, sero-therapy in, 300.
Rodier and Pansier. Vision in general paralysis, 185.
Roche. Helmholt's theory of accommodation, 117.
Rollet. Operation for ptosis, 315.

S.

Salus. Ciliary body and antibodies, 214; biology of the lens, 212; Glaucoma secondary to swelling of the lens in senile cataract, 367.
Scalinci. Parinaud's conjunctivitis, 379.
Schanz and Stockhausen. Dazzling, 181; Reaction of eye to light of short wave length, 158.
Schieck. Ætiology of retrobulbar neuritis, 59; albuminuric retinitis, 368.
Schneider. Leukine in infective ophthalmias, 172.
de Schweinitz. Ocular manifestations of sinus disease, 343
Sclerectomy, Herbert's, 191, 383.
Sclerecto-iridectomy, 109.
Scotoma helioplegic, 272.
Stereoscopic scotomagraph, 90.
Sero-therapy, paraspecific, 186.
Serum, Deutschmann's, 12.
Smith. Subconjunctival injection of cyanide of mercury in trachomatous pannus, 303.
Stargardt. Injury to dark adaptation. 248.
Stedman Bull. Post-operative history of giant magnet cases, 365.

Stephenson and Herringham. Puerperal amaurosis. 238.
Straub. Extirpation of the tarsus, 11.
Stock. Opsonin-technique in ophthalmology, 124.
Sympathetic ophthalmia, 40, 277, 285, 382.
Staphylococcus infections. ocular metastases in, 346
Syphilis, 82.

T.

Tenon's capsule, transplantation of fat in, 100.
Tension intraocular, effect of external muscles on, 220.
Tension intraocular, increased in epidemic dropsy, 198.
Terrien and Bourdier. Optic tract in cerebro-spinal meningitis, 316.
Tertsch. Ring abscess of cornea, 253.
Thompson. Operative Treatment of High Myopia, 321.
Thorner. Visual acuity, 220; Ophthalmoscope without reflexes, 287; fundus in diabetic lipæmia, 288.
Trachoma, pathology of, 25, 54, 87, 153, 318, 371, 372.
Trachoma, treatment of, 135, 303.
Troncoso. Filtration in the living eye, 50.
Trousseau. Non-reestablishment of anterior chamber after cataract extraction, 266; cataract operation in the aged, 245.
Tubercle of choroid, 28, 383.
Tubercle of episclera, 93.
Tubercle of posterior segment of eye, 267.
Tuberculin reactions in skin and eye, 76.
Tuberculous Iridocyclitis, 255.

U.

Uhthoff. Cataract operation in diabetics, 168.

V.

Valude. Neuro-fibroma from frontal nerve, 179.
Van Duyse. Tumours of the orbit, 151.
Verhoeff. Staining of trachoma bodies, 25.
Visual acuity, measurement of, 116, 220.
Vitreous, central canal of, 341.
Vortex veins, 63.

W.

Waldstein. Gonorrhœal conjunctivitis, 139.
Weekers and Heuvelmans. Slerectomy, 48.

Weigelin. Sympathetic ophthalmia, 277.
Weinstein. Buphthalmos, 206.
Wells and Mayou. Sarcoma of lacrimal gland, 32
Westoff. Bilateral total ophthalmoplegia, 19.
Wicherkiewicz. Operation in unripe and stationary cataract, 143
Word blindness, congenital, 192.

X.

Xerosis and night blindness, 197.

Y.

Year Book, Ophthalmic, 81, 349.

Z.

Zahn. Ionisation, 207.



ROBERT MARCUS GUNN,
M.A., M.B. (EDIN.), F.R.C.S. (ENG.).

ROBERT MARCUS GUNN.

M.A., M.B., C.M. (Edin.), F.R.C.S. (Eng.).

Robert Marcus Gunn, whose death is so deeply deplored by his professional brethren, passed away on November 29th, 1909, after a painful and distressing illness borne with splendid courage. Descended from an old Norse stock, he was born at Dunnet, Sutherlandshire, in 1850, and was the last survivor of a family of two sons and two daughters. He leaves a widow and two daughters. He received his early education at the late Mr. Thomas Fraser's school at Golspie, and proceeding subsequently to Edinburgh University he graduated there with distinction, obtaining the degree of M.A. in 1871 and that of M.B., C.M., in 1873. The history of his professional life and achievements has been already told by those who knew him well.* Here we can only give a brief record.

Gunn's professional career was very closely associated with the Moorfields Eye Hospital, to which institution he was deeply attached, and to which he gave many years of willing and valuable service, not less valuable in reference to teaching than in the care of patients.

At the time when he became incapacitated by his last illness, Gunn was Senior Surgeon to the Hospital. He was also Ophthalmic Surgeon to the National Hospital for the Paralysed and Epileptic, and in July last completed his term of office (two years) as President of the Ophthalmological Society of the United Kingdom.

* See *Lancet* and *British Medical Journal*, Dec. 11th, 1909.

Greatly to the sorrow of its members, he was unable to occupy the chair at the last few meetings of the Society over which he had presided so ably and so successfully.

Gunn's connection with Moorfields Hospital began in 1873 when he became a student there, attending especially Mr. Couper's practice. From December, 1874, to June, 1875, he studied at Vienna under Jaeger, a period of studentship of which he retained very happy memories. In August, 1876, he was appointed Junior House Surgeon, and in December of the same year, Senior House Surgeon to Moorfields Hospital. The latter post he occupied for two years. He was an extremely efficient House Surgeon and during his term of office many important and lasting reforms were effected in the hospital work.

In 1882 Gunn obtained the diploma of F.R.C.S. (Eng.). He was elected Assistant Surgeon to Moorfields Hospital in 1883 and Surgeon in 1888. In 1886 he was appointed Ophthalmic Surgeon to the National Hospital for the Paralysed and Epileptic.

In 1898 he was Vice-President of the Section of Ophthalmology of the British Medical Association, in Edinburgh, and in 1906 he was President of the same Section at the meeting of the Association in Toronto. In the same year he delivered an address before the American Academy of Ophthalmology and Oto-Laryngology. In 1907 he delivered an interesting address on the value of Ophthalmic symptoms in general diagnosis and prognosis,* and had arranged to take part in the Belfast meeting of the British Medical Association, but was too ill to attend.

Gunn was not a voluminous writer, but published a

* *British Medical Journal*, 1907, Vol. i, p. 1353.

considerable number of papers, chiefly in the Transactions of the Ophthalmological Society, and the Ophthalmic Hospital Reports. He was also the author of several important articles on the Eye, in Treatises on Surgery and Anatomy, etc. His published papers all bear the stamp of great care and accuracy in their preparation and are written with marked attention to clearness of expression.

Gunn was greatly beloved, and respected in an equal degree, by those who knew him. Mr. Nettleship to whom we are indebted for much of the information in this notice, writes in these words: "Marcus Gunn's character might be described as little removed from that of the perfect knight—courageous and pure in mind and body, modest, but clear and strong in his convictions, sweet of temper, ready always to see the better side, scrupulous in giving credit where credit was due. He was a man of considerable intellectual gifts and brain power and an exceedingly keen and accurate observer; his mental grasp was strong, his judgment careful and well-balanced: a certain matter of fact simplicity was set off by a ready sense of humour. His influence with colleagues, students, and patients depended largely on the conviction that he was true and loyal to the core and never satisfied with slipshod methods or imperfect knowledge. Himself singularly guileless he was a good judge of character and motives in others."

THE RECOGNITION AND MEASUREMENT OF LOW DEGREES OF NYSTAGMUS.*

By Edward Jackson, M.D., Denver, Colo.

High degrees of nystagmus are noted by family and friends; and on account of the movements many patients come to seek relief. Pronounced excursions of the eyeball, 2 mm. or upward, can be measured with sufficient accuracy by holding a rule in front of the eye, or noting the movement of the eye with reference to the reflex from a fixed light. Low degrees of nystagmus, excursions of 1 mm. or less, are more difficult to measure; and sometimes it is not easy by ordinary examination to decide whether or not nystagmus is present. Nystagmus of low degree is probably more frequent than nystagmus of high degree, and is of equally important significance.

Most ophthalmologists have observed, while making the ophthalmoscopic examination, low degrees of nystagmus that have not before been noted. Direct ophthalmoscopy, in which we watch the highly magnified image of the ocular fundus, will furnish a simple and sufficiently exact method for measuring the extent of the nystagmic movements.

In looking at the erect ophthalmoscopic image, if the eye of the surgeon be placed close enough to the eye of the patient, one may see the area of the optic disc, and a certain proportion of the surrounding fundus. As the surgeon withdraws his eye farther from that of the

* Read before the American Academy of Ophthalmology and Oto-Laryngology, October 3rd, 1909.

patient the visible fundus area diminishes; and at a certain distance from the patient's eye the image of the optic disc appears to occupy the whole area of the pupil. Farther away only a portion of the disc can be seen. At the distance between surgeon and patient where the image of the disc just fills the pupil, the pupil area presents a portion of the fundus image corresponding to a definite area of the retina, a circle about 1·5 mm. in diameter, the usual diameter of the optic disc. The movement of any given point across this space indicates an extent of movement in the eyeball that can instantly be known with practical accuracy; or calculated with still more minute exactness, if this be desired.

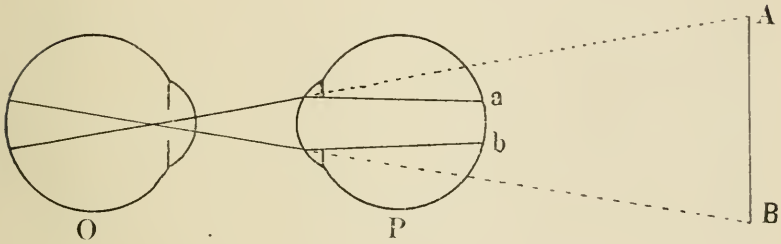

Relations of eyes of surgeon and patient for the measurement of nystagmus. *O*, eye of the surgeon. *P*, eye of patient. *a b*, the part of the fundus visible in the pupil. *A B*, part of enlarged fundus image corresponding to *a b*, and to the projection of the pupil.

Under these conditions if the movement were wholly in the ocular fundus the actual displacement of a point moving across the pupil would equal the diameter of the optic disc, 1·5 mm. But while the fundus moves in one direction the pupil moves in the opposite direction so that the actual movement is only a fraction of 1·5 mm. Take the case of an emmetropic eye having a pupil 6 mm. in diameter. Conceive the fundus image (as do Snellen and Landolt, Traité Complet d'Ophtalmologie,

De Wecker and Landolt, Vol. i, p. 800) projected on a plane 30 cm. behind the nodal point of the observed eye, and therefore magnified 20 diameters. The image of the optic disc will be $1.5 \times 20 - 30$ mm. in diameter. In order that the 6 mm. pupil shall be projected of the same size, 30 mm., upon the same plane, it must be $^6/_{30} - ^1/_5$ the distance of the plane of projection from the observer's eye. Disregarding the distance (4 mm.) between the plane of the pupil and the nodal point of the patient's eye, the distance of the pupil from the plane of projection 30 cm. will be the other $^4/_5$ of the distance of the surgeon's eye from the plane of projection. Hence the distance of the surgeon's eye must be one-fourth of 30 cm. or 7·5 cm., or 3 inches.

Viewing the erect ophthalmoscopic image of the fundus from this distance, an actual movement of a point on the retina equal to 1·5 mm., the diameter of the disc, would cause such a point to appear to move across the width of the pupil if the pupil remained stationary. Or, a movement of the pupil equal to its own diameter would cause a point in the fundus to appear to move across the width of the pupil, assuming that such point remains stationary. In nystagmus both the fundus and the pupil are displaced. The apparent movement of a point across the pupil is the effect of the actual movement of the point, plus the effect of the actual movement of the pupil.

The pupil and the ocular fundus move about the centre of rotation of the eyeball which for practical purposes lies half-way between them. Hence the actual movements of the fundus and the edge of the pupil are practically equal. But the movement of the fundus of 1·5 mm. under the conditions assumed produces just as much effect in the apparent displacement of its image as

does the movement of the pupillary margin, the whole diameter of the pupil. Taking the case assumed above, 1·5 mm. movement of the fundus produces the same effect as 6 mm. movement of the pupillary margin. Since the actual movement of the two points is the same, the share that each produces in the apparent movement of a given point across the pupil is inversely as these distances. That is, the apparent movement produced by fundus displacement, is to the apparent movement produced by pupil displacement; as the diameter of the pupil is to the diameter of the optic disc. In the above case of a pupil 6 mm. in diameter the relative size of pupil and optic disc are 6 : 1·5 or 4 to 1. If the total apparent movement across the pupil be represented by 5, four-fifths of this is due to movement of the fundus, and one-fifth to movement of the pupil. Table I, based upon the assumptions that the eye is emmetropic and the diameter of the optic disc 1·5 mm., gives in column one, different diameters of the pupil; in column two, the distance of the surgeon's eye (nodal point) from the patient's pupil; in column three, the percentage of actual displacement for the point in the fundus as compared with its movement in millimetres of a point of the fundus that seems to move across the pupil.

Table I.

(Pupil including area the diameter of the optic disc.)

Pupil.	Bet. eyes.	Percentage.	Actual movement.
2 mm.	21 mm.	·57	0·85 mm.
3 ,,	33 ,,	·67	1·0 ,,
4 ,,	46 ,,	·73	1·1 ,,
5 ,,	60 ,,	·77	1·15 ,,
6 ,,	75 ,,	·80	1·20 ,,
7 ,,	91 ,,	·82	1·23 ,,
8 ,,	109 ,,	·84	1·26 ,,
9 ,,	128 ,,	·85	1·28 ,,

If a given point of the fundus image moves just the apparent width of the pupil, the actual movement of the eye is indicated in column four of the table. If it moves only a fraction of this distance then a similar fraction of the number of mm. given in column four of the table represents the real movement. For instance, with a pupil 3 mm. in diameter the point of the fundus appears to move one-fourth of the way across the pupil, the actual movement is only one-fourth of one millimetre.

This method is also capable of modification so as to measure higher degrees of nystagmus. By bringing the surgeon's eye closer to the eye of the patient, a portion of the fundus having a diameter twice that of the optic disc can be brought into view, and in this way oscillations of greater amplitude can be measured. Table II gives the same data as Table I, but for the pupil projected on the plane of the fundus image so as to correspond to a portion of the fundus 3 mm. in diameter.

TABLE II.

(Pupil including area double diameter of the optic disc.)

Pupil.	Bet. eyes.	Percentage.	Actual movement.
2 mm.	10 mm.	·40	1·2 mm.
3 ,,	16 ,,	·50	1·5 ,,
4 ,,	21 ,,	·57	1·71 ,,
5 ,,	27 ,,	·62	1·86 ,,
6 ,,	33 ,,	·67	2·0 ,,
7 ,,	40 ,,	·70	2·10 ,,
8 ,,	46 ,,	·73	2·19 ,,
9 ,,	53 ,,	·75	2·25 ,,

For practical purposes it is sufficient to remember that with the pupil projected on the plane of the fundus image, with a fundus area of 1·5 mm. diameter, the actual displacement causing a given point to move across

the pupil varies from 1 mm., with a small pupil, to 1·25 mm. with the pupil widely dilated. With the surgeon's eye brought closer to render visible a 3 mm. area of the fundus the actual movement which appears to carry the point across the pupil varies with the size of the pupil from 1·5 to 2·25 mm.

In addition to the actual diameters of the optic disc and pupil, it is evident that the relations of apparent with actual movement will be influenced by the refraction of the eye, whether the ametropia is axial, or curvature ametropia; the lens used to secure a clear fundus image, and its position between the observed eye and the eye of the observer. These all influence the enlargement of the fundus image. Elaborate calculations based upon the refraction of the eye and the extent to which the ametropia is axial, or is ametropia of curvature, might give the exact value of the apparent fundus movement in each case. But the simple and practical method is to make the observation with correcting lenses placed before the patient's eye at its anterior focal point. Such lenses reduce the problem in any case to that of simple emmetropia, and permit us to deduce the actual rotation of the eye by the method above indicated.

The above applies to all rotations made about axes perpendicular to the antero-posterior axis of the eyeball, as in lateral or vertical nystagmus. For the rotations around the antero-posterior axis, rotary nystagmus, we also have in the optic disc an available test. The disc may be taken as a circle, the rotations of which around the antero-posterior axis of the eyeball may be compared with any fixed meridian. The disc would serve better if the antero-posterior axis pierced its centre. With a dilated pupil vessels converging to the macula may be used in place of those diverging from the centre of the

disc, to estimate the rotation about the antero-posterior axis. These observations on rotary nystagmus do not require that the observer should place his eye at any particular distance from the eye of the patient. The angular movement in a plane perpendicular to the line of sight can be observed from any convenient distance.

Briefly the method of observing nystagmus here described consists in noting the character of the movements executed by definite structures in the ocular fundus as seen in the erect ophthalmoscopic image. Withdrawing the observer's eye until the optic disc appears to occupy the whole of the pupil one observes the apparent extent of the movements, whether a given vessel appears to pass entirely across the width of the pupil with each excursion of the eyeball, or only one-half or one-fourth of that distance. From this, by brief calculations, or from the tables given above, the real extent of lateral or vertical movement is to be deduced. Perhaps it is not necessary that all cases of nystagmus shall have the extent of movement exactly measured. Yet this can properly be required for cases reported to take their place in the literature of the subject; and it will be found very satisfactory, in attempting to judge by the extent of the movements as to the progress of any case under treatment.

REVIEWS

Hayashi (Tokio). **On the Pathological Anatomy of Phlyctens and Phlyctenular Processes.** *Klinische Monatsblätter für Augenheilkunde*, November, 1909.

The author, after a brief summary of the results of previous work on this subject, comments on the lack of harmony displayed, and proceeds to give the results of his own researches in five cases of keratitis, and six cases of conjunctivitis, all of a

phlyctenular character, in all cases the material having been obtained by excision during life.

Hayashi submits the following points with regard to corneal phlyctens. The first changes are found in the parenchyma of the cornea, under Bowman's membrane and the epithelium, both of which however sooner or later undergo a process of necrosis: he contradicts absolutely von Michel's view of vesicle formation, and he is unable to find in fresh foci any new formed vessels. One case, that of an obstinately recurring keratitis in a patient aged thirty-two, showed a caseating nodule under Bowman's membrane surrounded by granulation tissue, but it was impossible to demonstrate any micro-organisms in it, and inoculation experiments gave negative results.

In another case, that of a girl of sixteen years of age, obviously, according to his account, riddled with tubercle, he found several isolated phlyctens, one of which he excised; glands in the neck excised subsequently showed typical tuberculous changes, and the histological appearances in the excised phlycten were similar to those in his former case; one other case in a twelve year old girl showed similar results.

Hayashi discusses the possibility of ectogenous and endogenous infection, and apparently is of the opinion that phlyctenulæ in general result from an infection with the toxines of tubercle bacilli, a view which seems reasonable enough when applied to some cases, such as numbers 4, 5, and 6 in his own series, but which can hardly be said to apply to all cases of phlyctenular ophthalmia.

R. R. James

Straub (Amsterdam). **The Extirpation of the Tarsus in the Curative Treatment of Entropion from Trachoma.** *Klinische Monatsblätter für Augenheilkunde*, October, 1909.

The author describes his method of operation, which is as follows. The upper lid having been everted and fixed by means of a clamp, an incision is made through the conjunctiva of the lid parallel with, but on the fornical side of, the horizontal subtarsal trachoma scar. The fornical part of the conjunctiva is separated through this incision from the tarsus and three mattress sutures are passed through its free margin in such a way that the loops of the stitches lie upon the ocular surface of the conjunctiva. An incision is now made between the lid margin and the marginal scar through the conjunctiva and the whole thickness of the tarsus, and the portion of the tarsus

lying between this incision and the true upper edge of the cartilage is dissected out and removed. The needles attached to the free ends of the mattress sutures are next passed between the narrow strip of tarsus which remains and the skin of the lid, and are made to emerge between the cilia, care being taken that the lateral sutures lie near the angles of the lids. The operation is completed by tightening and tying the corresponding suture ends in such a way that the lid margin is tilted forwards.

The author states that he has met with some trouble owing to the uneven character of the conjunctival scar which may result. He does not specify the material which he employs for his sutures.

A. C. Hudson.

---

v. Hippel. **The Therapeutic Value of Deutschmann's Serum.** *v. Graefe's Archiv.*, 72, 2, October, 1909.

A polyvalent serum capable of counteracting numerous infective processes, not only in the eye but elsewhere in the body, and in itself perfectly harmless, may be a chimæra; nevertheless when we are told that a discovery of this sort has been made, and when the claim is supported by a mass of clinical evidence, we are bound to consider it. It was in 1907 that Deutschmann published an account of his serum, obtained from the blood of yeast fed animals.[1] Experimentally he found that virulent cultures of staphylococci, streptococci, pneumococci and tubercle bacilli had less effect when injected into the anterior chamber of yeast fed than of control animals. Clinically he claimed specially good effects from the injection of his serum in cases of hypopyon ulcer, iritis and cyclitis.

The subject was debated at the Ophthalmological Congress at Heidelberg in 1908 and experimental evidence of an adverse nature brought forward, on the strength of which Axenfeld pronounced himself sceptical as to the use of the serum. Clinically, however, more or less favourable reports have been made from various quarters,[2] including a series of 40 cases published by von Hippel. This author now publishes a series of 100 fresh cases in which the remedy has been used, in some cases with good results.

Taking, first, cases of ulcus serpens, 306 cases were treated at

1. *Ophthalm. Review*, 1908, p. 80.
2. *Ophthalmoscope*, 1908, p. 940; 1909, p. 532.

Göttingen during the six years prior to the introduction of Deutschmann's serum, the mild ones by hot fomentations and iodoform (atropin is not mentioned), the severe ones by the actual cautery or by corneal section. The percentage in which vision amounting to one-tenth of the normal was retained was only 48. Taking the severe cases alone it was only 33. In 8 per cent. enucleation was necessary. After the introduction of the serum treatment the results were distinctly better. 39 cases of ulcus serpens were treated, all of them severe and most of them with iritis, pupillary exudation and synechiæ. In no case was the cautery used, in 22 serum injections alone, in 17 serum injections in addition to corneal section was the treatment; the ordinary treatment with atropin and fomentations is mentioned as having been used in some cases. Of the 39, 20 recovered with sight of one-tenth of the normal or better, which makes 51 per cent. as compared with the 33 per cent. of the severe cases treated without the serum. In only two out of the 39 cases was enucleation necessary. In some cases a single injection of 2 cc. was sufficient. In others many injections were given, but in the worst cases they were useless. These figures, while not very convincing, yet give some ground for supposing that the serum injections exercise a favourable influence. Besides cases of ulcus serpens, the serum was employed in 5 cases of infective corneal ulcer which differed from ulcus serpens, in 15 cases of severe plastic iritis, and in 9 cases of perforating wound of the globe. In many of these cases the disease was entirely unaffected but in some a marked improvement took place after the injections—whether or not on account of them there is nothing to show. The following two cases are cited as favourable examples.

(1) Five days after the extraction of a senile cataract the patient knocked his eye and had a hæmorrhage in the anterior chamber. Four days later injection was severe and there was a yellow exudation in the anterior chamber extending to the pupil. A dose (2 cc.) of serum was injected and two days later the injection was repeated. Thenceforward the exudation began to absorb and by dint of a subsequent iridectomy and another operation for secondary cataract a vision of 0·3 was ultimately obtained. What other treatment was adopted is not stated.

(2) A cataract was extracted without iridectomy in a patient who had had an epiphora (not purulent) which had been probed. Four days after the extraction there was iritis with an exudation reaching to the pupil. 4 cc. of serum were in-

jected in the same day. The next day the pupil was covered with exudation and the injection of serum was repeated. This was followed by immediate improvement and three weeks later the exudation was absorbed.

In neither of these cases does there seem to be sufficient proof that the remedy had anything to do with the cure, and yet the rapidity of the cure is remarkable enough to demand that we should suspend our judgment until the remedy has been subjected to more extensive tests. There is this to be said in favour of it. It does not pretend to be able to cure every disease of the eye. In the last class of cases in which it was tried—perforating wounds of the globe—it is not pretended that any good effects followed. As to the mode of action of the remedy it is entirely a matter of speculation, the only positive facts about it being negative. By itself it is non-bactericidal, non-antitoxic and has no effect on the opsonic index. Its influence, therefore, if any, must be indirect or only active in combination with other factors derived from the blood.

A. H. T.

HERRFORDT. **"Gonorrhœal Epibulbar Subconjunctivitis."** *v. Graefe's Archiv.*, 72, 2.

DIRECT infection with the gonococcus is not the only cause of conjunctivitis in the subjects of gonorrhœa. In certain cases it appears as the result of a systemised infection in the same way that arthritis and iritis appear in gonorrhœal subjects. All cases of gonorrhœa treated at the Copenhagen Municipal Hospital during the five years ending with the end of 1908 were observed from this point of view, 2,310 in all, and the "endogenous" form of conjunctivitis was found to occur in 23, just one per cent. The proportion was smaller in women than men, and relatively larger in cases of recurrent or chronic gonorrhœa. It was associated relatively often with arthritis. Gonococci were only very exceptionally found in the conjunctival secretion. Compared with the ordinary or "exogenous" form these cases run a mild course and are easy to cure though apt to relapse so long as the gonorrhœa lasts. The inflammation affects the bulbar more than the palpebral conjunctiva, is usually bilateral and may be either diffuse with much superficial injection or localised with deeper episcleral injection. It is very apt to take the form of a phlyctenular conjunctivitis and in these cases the cornea may become affected as in phlyctenular keratitis. The treatment recommended for cases without secretion is daily

massage with yellow ointment, for cases with secretion copper sulphate solution $\frac{1}{4}$ per cent. As the cases are rare their cause may easily be overlooked and the important thing is to remember that an uncured gonorrhœa is liable to produce this among other ill effects.

A. H. T.

NEVEN GORDON CLUCKIE. **A Corneo-Conjunctival Bridge. A New Method of Cataract Extraction.** *Lancet*, October 9, 1909.

THIS is a modification of von Graefe's extraction, the end in view being to reduce the risks of infection and the danger of non-closure of the wound. In order to prevent the sudden removal of nourishment from fully one-third of the cornea the author makes a von Graefe's section up to a point that leaves a connecting flap between the cornea and conjunctiva about 4 millimetres broad. Instead of completing the corneal section in the usual way the Graefe's knife is carried further up under the bulbar conjunctiva for from 10 to 12 millimetres and is then withdrawn without cutting through the conjunctiva. A corneo-conjunctival bridge which may be broad or narrow is thus obtained. The author maintains that the broader and longer the conjunctival attachment to the cornea the greater are the chances of success and speedy recovery. The object of having a large corneo-conjunctival band is to allow sufficient bulging or gaping of the wound to take place for the escape of the lens and to close immediately after pressure is withdrawn. If an iridectomy is to be done at this stage it can be performed up and out. It is claimed by this method that the nutrition of the cornea is not interfered with to the same extent as in the usual method of complete section. The parts are kept in more accurate apposition favouring rapid union and an earlier re-establishment of the anterior chamber is obtained. The contingency of the upper eyelid getting between the lips of the wound or the conjunctival flap turning in upon itself is rendered impossible. It is also less likely that the iris, vitreous, or cortical substance will be caught in the wound as the "bridge" method gives more freedom for thorough examination. The "bridge" method supplies a barrier preventing prolapse in vomiting after the operation. The author also believes that corneal astigmatism is less likely to be produced. In conclusion, the author points out that should there be any difficulty with the extraction the bridge can be divided with scissors.

J. F. CUNNINGHAM.

F. Park Lewis (Buffalo, N.Y.). **The Ophthalmic Origin of Otic Disturbances with the Cerebellar Control of the Eyes.** *Annals of Ophthalmology*, January, 1909.

The object of this paper, as the author states at the commencement, is: "1st.—To call attention to the fact that clinical evidence shows that such relationships exist between the eye and the ear that an irritation or improper functioning of the former may be manifested in a disturbance of some character in the latter. 2nd.—To show anatomically what these relationships are. 3rd.—To show that a complex of symptoms closely resembling those of Ménière's disease may be produced through incoordinate action of the eyes; and 4th.—This is of especial importance—to show that in the physiology of vision the cerebellum exercises governing functions."

By way of demonstration of this elaborate thesis he first instances various cases in which correction of refractive errors led to cures of "tinnitus aurium," "repeated and increasing attacks of dizziness," "sensation of burning with a feeling as of wind in the ear" and "vertigo."

The cure of tinnitus aurium accords with an instance in the reviewer's own experience, in which this symptom was relieved entirely, though only for a few days, after the patient had adopted the use of appropriate glasses, and which undoubtedly appeared as a case of "propter hoc." It occurred in a case of otosclerosis, the condition of aural disease with which tinnitus is perhaps par excellence associated, and for this most intractable and unresponsive disorder any methods of treatment or suggestions as to alleviation will be universally welcomed. The avoidance of all overstrain and worry and the removal of any incidental disability as far as possible has been the generally recognised form of treatment in these cases and the suggestion that one should insist on the correction, in addition, of even the smallest errors of refraction accurately corresponds with the advice usually given to sufferers in this respect. It will be interesting to note the effects and watch further reports of the treatment of tinnitus carried out in this direction, and though one cannot expect the associated deafness to be appreciably affected thereby, it is of the distressing "noises" that those afflicted with otosclerosis almost always chiefly complain.

It is a little difficult to appreciate the author's reason for referring to "symptoms closely resembling those of Ménière's disease" as in the opening remarks in his commentary he quotes the views of Prof. Politzer on the subject, with which he

apparently agrees, " all subjective disturbances of hearing associated with noises and giddiness have been called Ménière's disease or Ménière's complex of symptoms, disturbances of hearing which, as we have seen, are also frequently observed in accumulations of cerumen, vegetations in the external meatus, in affections of the middle ear, in many temporary congestions of the labyrinth or brain, after injuries or tumours of the brain," and it is probable that the trend of modern clinicians is to relegate Ménière's description to the shelves of historical classics and to discuss such symptoms in terms of the pathological lesion responsible for their production.

It is worth while repeating a quotation which is given of the conclusions at which Dr. Marcel Rollet arrived in a paper read before the Société Francaise d'Oto-Rhino-Laryngologie in December last as it really embraces the whole gist of the article under consideration:—" There exist between the organs of vision and those of audition certain relations—both direct and indirect—relations which the nervous connections, both central and peripheral, of the two organs suffice to explain, and it must be admitted that in the case of objects which may be recognised by the two organs the excitation of the one of them may awaken through the association fibres the images of the memory belonging to the other organ."

As regards the relation of the cerebellum to the physiology of vision Lewis correctly remarks that apart from sub-occipital and cervical pain, which is the most uniformly common symptom of cerebellar growths, nystagmus is probably the next most frequent phenomenon to be observed. This subject of cerebellar nystagmus has recently centered a large amount of original work with which the names of R. Barany of Vienna and Sidney Scott of London are perhaps most intimately associated, and the causal relation between labyrinthitis and cerebellar disease and nystagmus has been undoubtedly established, though their exact anatomical connections remain somewhat obscure.

Still, the matter is engrossing a great deal of interest and those who are conversant with the work done in this direction will agree with the concluding prophecy of the article " that it will be shown that, when in examining the eyes, we become habituated to looking for cerebellar and auditory relationships, we will be astonished to find how commonly they will be found to exist."

Two semi-diagrammatic schemes (after Edinger), showing the

possible connections between the auditory nerve, the oculo-motor centres and the cerebellum, accompany the paper.

ALEX. R. TWEEDIE.

FOSTER (New York). **Reflex Asthenopia from Intranasal Pressure.** *Annals of Ophthalmology*, October, 1909.

THIS article forms another contribution to the subject of referred orbital pain and ocular symptoms attributable to intranasal disabilities and disease. A good deal has been written of late years on this matter, principally from the pens of nasal surgeons, and "perhaps," as the author says in his opening remarks, "this is to be the era in which the symptomatology of these associated conditions is to be recognised," and his plea in brief is for the more intimate collusion of the eye specialist and rhinologist in all cases of asthenopia which do not respond to their "correction" with glasses. He quotes several cases which illustrate the value of his contention, in most of which, as indeed one would expect from one's own experience, some disease or abnormality in connection with the middle turbinal was found to be the whole cause or a contributory agent in the production of symptoms for which the patient primarily sought relief from the ophthalmic surgeon.

That such an interdependence does exist is of course well known, and numerous other instances might easily be cited in its support. Possibly the rhinologist has the opportunity of becoming better acquainted with these cases, since patients suffering from intra-nasal troubles very usually complain of ocular or supra-orbital headache, "watering" of the eyes, etc., whilst in the eye specialist's practice it is apparently rare for patients to refer to any impairment of the nasal functions even when such are known to exist; and it is of course much more natural for the sufferer from pain in or around the eye to regard the eye as the probable seat of the symptoms.

Still the intimate topographical association of these two organs is in itself quite sufficient to connote an overlapping of symptoms when one or other of them is diseased and in addition the common origin of their innervation is a simple elementary anatomical fact which all surgeons dealing with this portion of the body should of course keep constantly in view. Nevertheless the point is of prime importance, though possibly in drawing attention to the subject it may be rather difficult under the circumstances to avoid the appearance of having rather laboured the point, for the merest glance at the

many possible structural dispositions of the nasal accessory sinuses and the relation of the middle turbinal to their ostia suggests at once a large group of symptoms, in the case of their disease, even to one with little or no experience of the ills to which all flesh is heir.

As Foster in part observes, the conclusions at which one arrives after consideration of the subject may be summarised as follows:—

Apparent affections of the eye may be either wholly or partially dependent on some intra-nasal condition.

In vague symptoms of headache, neuralgia, fatigue, etc., the cause may lie either in the nose or the eye.

As regards treatment, should there be any doubt as to the source or principal source of such complaints, errors of refraction should first be corrected and the effect watched.

To the author's statement that the ophthalmologist should also be a competent rhinologist and practice as such most specialists will take decided exception, though all will agree with his suggestion of harmonious collaboration, and that each specialist should take out a course or have had some training in the other's particular sphere of work—a condition of affairs which indeed already obtains in England and probably in most other countries as well.

Alex. R. Tweedie.

C. H. A. Westhoff (Java). **A Case of Bilateral Total Ophthalmoplegia.** *Centralblatt für praktische Augenheilkunde*, December, 1908.

The circumstances under which this condition—rare in any case—arose in a patient who came under the care of Westhoff are sufficiently exceptional to call for publication. The author first saw his patient in July, 1907, on account of a smart but not very severe attack of gonorrhœal conjunctivitis, at least we must suppose that that was the origin of the purulent opthalmia from which he suffered, for he at the same time had a recent gonorrhœa; Westhoff does not say whether he looked for the gonococcus in the discharge. At any rate under treatment by washing with a lotion of corrosive sublimate, use of protargol in 20 per cent. solution, and internally by means of Sandalwood oil, he recovered. He notes particularly that the patient did not appear to be very ill at all, nor did he feel ill. There was no great rise of temperature and the surgeon was satisfied that

malaria was not an element in the case; as a matter of fact malaria is not common in the part of Java served by Dr. Westhoff, and the patient came from a mountain district where it does not occur. The type of fever was much more like enteric. He was given both aspirin and quinine till he began to have singing in the head. Rather more than a month after the first consultation the patient complained that he was seeing only dimly, and the doctor who was treating him, noticing that the pupil of his good (left) eye was dilated, imagined that perhaps atropin had been supplied by mistake, but that was not the case. The same day patient vomited a very acid material; the temperature came down, but the quinine was given; in the evening he vomited again, felt ill and had no appetite. In a few days he was better, but soon returned with the left pupil dilated and bilateral ptosis; the fundus was normal, there being no suggestion of the pallor which quinine poisoning is apt to produce. The eyes were directed straight forward and were quite immobile; there was no muscular action whatever in any direction and accommodation was completely paralysed. His lower jaw, too, was apt to drop, and chewing became very fatiguing as though from weakness of the muscles attached to the jaw. The tongue was protruded in the middle line, and swallowing was quite easy; the limbs were not affected. His speech became somewhat nasal. He had never had syphilis. Under iodide of potassium he gradually improved, one of the earliest signs being the cessation of the headache which had demented him, and in three months the condition had practically returned to normal.

As regards the etiology, the conclusion to which Westhoff comes is a somewhat unusual one: he considers that there are three possibilities. (*a*) Gonorrhœal toxin he rejects because of the rapid and complete recovery from the urethral and the conjunctival affections and the absence of any joint lesion, iritis or other manifestation. (*b*) Malaria he rejects on the ground that the patient did not live in a malaria district and that his type of fever was not suggestive of that disease. He believes the lesion to have been (*c*) the result of typhoid fever, which is fairly common in the Indies, but if so, why did symptoms so severe occur after a comparatively mild and benign type of fever as he had? He finds the explanation in the large amounts of antipyretic and other medicines given, which caused a heaping up in the system of the non-eliminated toxins. But does not—for example—post-diphtheritic paralysis frequently follow the milder types of fever? He need not, one would

think, invoke the theory of "bottling-up" of toxins by medicine. If he is right in his suggestion as to the origin the case has the interest that this must be a very rare sequela of enteric.

W. G. S.

Calderaro (Rome). **The Bacteriological Condition of the Conjunctiva before and after Excision of the Lacrymal Sac.** *La Clinica Oculistica,* August—September, 1909.

In a long and interesting paper Calderaro gives an account of ten cases in which the bacterial flora of the conjunctiva was investigated before excision of the sac and contrasted with that found subsequent to the operation. In each case the necessity for excision of the sac arose in consequence of chronic dacryocystitis; in two of the cases, it is right to mention, trachoma was also present. For the actual details of the methods of investigation employed the original paper had better be consulted. His conclusions may be stated thus:—

(1) After excision of the sac the organisms present in the conjunctiva are always reduced in number, and there is further a very considerable difference in the result according to the period which has elapsed—a few days to some months—since the operation.

(2) When the examination is made a few days (10 to 15) after the operation there is to be observed (*a*) a very decided fall in the number of organisms present, and along with this a diminution of the virulence of such as are to be obtained; (*b*) that the cultures remain sterile for some hours (3 to 6), then the growths begin to become manifest of the same organisms as had been present before the operation, and in particular certain pathogenic ones whose virulence seems to be intensified, from which fact one derives the clinical conclusion that it is well not to proceed to any operation on the eye without allowing a full fortnight to elapse from the time of excision.

(3) When the examination however is made, after a period of two months has elapsed from the date of the operation, the results are quite different, for only in one case out of five did he find a pathogenic organism—diplococcus—though saprophytic bacilli were fairly plentiful: that was when the eye was treated in the open, but when it was kept under bandage pathogenic organisms were found in every case, not perhaps in a state of sufficient activity to kill the animal used for experi-

ment but sufficient seriously to hamper the healing of a corneal wound.

(4) A very similar result was true also of a bacteriological examination made three, four, five, or six months after the excision: such germs as might be present had lost their virulence. But if the eye was bandaged, say for six hours, pathogenic organisms appeared in a third of the cases, and if the bandage was kept on for twelve hours they became more copious and more virulent, while at the same time the saprophytes diminished.

(5) In cases in which trachoma was present the reappearance of the organisms and their increase of virulence was more rapid: three hours' bandaging was quite sufficient to bring this about.

(6) Abolition of the ablution of the tears by obliteration of the duct brings about an increase in the microbic flora of the conjunctiva, but if the eye is kept without dressing the saprophytic organisms are in much greater profusion than the pathogenic, while the opposite is the case if the eye is kept dressed, when, further, the virulence of the organisms is increased.

(7) Division of the stricture and the passing of probes are very much less effective means of preventing infection than is removal of the lacrymal sac, for in it there are always pathogenic organisms if the sac has been purulent.

(8) In cases in which the lachrymal gland is also removed the risk of infection is enhanced.

(9) When, under such conditions as have been spoken of above, it becomes necessary to perform any operation implicating the cornea, and most of all, operations for cataract, it is best (*a*) to let sufficient time elapse after the excision of the sac before proceeding to extraction, (*b*) to treat the eye by the open method and eschew bandaging, and (*c*) to wash out the conjunctival sac three times a day with normal saline: this is sufficient to maintain sterility of that membrane.

The reviewer has learned with much interest the views of Calderaro upon this subject, and his results, for he himself believes that bandaging is done too much in various conditions of the eye, and he constantly treats all his cataract cases by the open method, no bandage whatever being applied even on the operation table.

W. G. S.

Niels Höeg. **Annular Opacity (Trübung) of the Anterior Surface of the Lens following Contusio Bulbi.**

L. Caspar. **The Causation of Annular Contusion-Lesions of the Lens.** *Klin. Monatsblätter für Augenheilkunde*, June, 1909.

In the year 1903 Vossius described two cases of injury to the eye in which he found a ring of slight opacity concentric with the pupillary margin situated on or close to the anterior surface of the crystalline lens; during the two succeeding years he observed and published several cases. The condition had not been previously described. In 1906 Vossius's cases—six in number—were embodied in a thesis by Keller, who gave a full and careful description of the clinical appearances and a report of Vossius's views as to the nature of the changes. Since Keller's paper was published, six more cases have been reported by various observers, and now Höeg publishes the notes of another case occurring in Bjerrum's clinic, in which he is an Assistant. Caspar also reports a case which is important in relation to the immediate causation of the changes in the lens.

Thirteen examples have thus been published and the description in all of them is very similar and fairly typical. The lesion appears to be rare or at least rarely observed, and in all instances has followed a severe blow on the eyeball; other lesions of the eye have resulted in several of the cases, *e.g.*, rupture of iris, or of choroid, but they apparently bear no causal relation to the condition first noted by Vossius.

After such an injury, examination of the eye reveals in the centre of the anterior surface of the lens and concentric with the margin of the pupil a delicate, regularly circular opacity with a diameter of 3 to 4 mm. It is always seen most distinctly by transmitted light and then has a rather dark appearance; by focal illumination it is often scarcely recognisable or shows only as an exceedingly delicate grey circle; occasionally it has a brownish colour or else the grey opacity is speckled with brown particles and is then more easily seen. On more careful examination with a magnifier exceeding fine dots and streaks are visible. The periphery of the circle is sharply defined, the inner border less so. The area enclosed by the ring is sometimes slightly blurred and the appearance is then that of a disc-shaped opacity with a denser periphery. The circle is nearly always complete and regular, but in one instance, only a semi-circle could be detected, and in two or three others there was an incomplete gap in the ring.

How soon after the injury the lenticular changes can be seen is still uncertain; they have been present at the first examination of the eye, and have not increased in degree. The shortest interval between the injury and the discovery of the annular opacity has been one of "several" hours. After remaining unchanged for a period which is very variable the lenticular changes become less and less noticeable and, in most cases certainly, and in all cases probably, disappear entirely. As a rule the ring begins to fade within a day or two, but in some instances has shown no diminution for 6 to 18 days. Its complete disappearance may not occur for several weeks.

The acuity of vision is apparently unaffected by the lenticular lesion: in several cases it was quite normal, while in those with diminished acuity other damage to the eye fully explained the loss. The changes in the lens are, as a rule, not the only result of the blow upon the eye. In nearly all the cases there was also hæmorrhage into the anterior chamber and often a superficial or deep wound of the cornea, while in a considerable proportion rupture of iris or choroid and damage to other structures occurred. The nature of the injury varied, but it was generally a slight or moderately severe contusion; no conclusion can be drawn from this however as such slight changes may occur in severe injuries and be easily overlooked.

What is the exact nature of the annular opacity in the lens? Vossius expressed the opinion that it was an impress of the pupillary margin on the anterior lens capsule: the brownish appearance he considered as a cast of the iris margin and its pigment on the lens capsule by fibrin. The grey opacity he thought was due to degenerative changes in the subcapsular epithelium or in the most superficial layers of lens fibres, induced by the pressure of the edge of the iris. Similar changes have been produced by Schirmer in experimental contusions of the lens, and microscopic examination has shown degenerative changes in the subcapsular epithelium, and when the contusion was severe, slight superficial changes in the lens fibres.

Höeg is in agreement with Vossius and other observers as to the nature of the changes seen on the surface of the lens in the cases under discussion, but he thinks that the explanation that the iris is squeezed between the lens and the incurved cornea at the time of the injury, is incorrect. He believes that the pressing of the pupillary portion of the iris against the lens capsule is effected by a sudden increase of pressure in the anterior chamber brought about by the blow upon the eyeball.

Caspar publishes brief notes of a case recently under his observation because it appeared to him to demonstrate unusually well the production of the lenticular changes by pressure of the pupillary margin of the iris against the anterior surface of the lens. His patient was struck on the eye by a nail an hour before Caspar saw her. There was a perforating wound of the cornea with prolapse of iris in the lower-outer part. The anterior chamber was filled with blood. In the course of several days the blood became absorbed and examination with a loupe revealed the changes on the lens surface described by Vossius. The changes did not, as usual, form a complete circle but had an egg-shaped contour with a gap in the lower-outer part corresponding to the defect in the pupil caused by the prolapse of the iris. The opacity in the lens had entirely disappeared on the tenth day after the injury.

The ovoid shape of the opacity, the narrow end of which was situated behind the deformity in the iris, and the break in its continuity at this part seem to show clearly the relation of pressure by the iris to the changes on the surface of the lens.

J. B. L.

F. H. Verhoeff. **A Rapid Method of Staining the Trachoma Bodies of Halberstaedter and Prowazek.** *The Ophthalmic Record*, October, 1909.

Verhoeff considers that, though it is still doubtful whether the cell inclusions, first described by Halberstaedter and Prowazek and later by Greef, are the infective organisms of trachoma, their great diagnostic importance is no longer open to doubt. He states that he has succeeded in staining the bodies by Wright's modification of Leishman's stain; the technique employed being the same as for staining blood films. He recommends this method of diagnosis which takes only a few minutes, being employed while the patient waits: he has found it especially valuable in differentiating from trachoma cases of lymphoid hypertrophy complicated with acute conjunctivitis. Judging from the micro-photograph reproduced, the results by this method compare favourably with those obtained with dilute solutions of Giemsa's stain, and the mixture, recently recommended by Greef, of watery solutions of azure I, II, and eosin. If uniformly excellent results can be obtained with Wright's stain, the advantage over the methods previously employed, which take several hours, and are frequently unsatisfactory, will be considerable. The statement that "the great diagnostic importance of these appearances is no longer open to doubt,"

seems at least premature. Many observers have succeeded in demonstrating "cell-inclusions" in cases diagnosed on clinical grounds as early or acute trachoma; some have failed: one or two claim to have seen similar appearances in cases of follicular conjunctivitis and spring catarrh. Further evidence obtained by the examination of a large number of cases, and of various conditions, seems desirable before the diagnostic value, either of the absence or presence of "cell inclusions," can be decided.

B. H. Wedd.

Cabannes (Bordeaux). **Trephining in Cerebral Tumour with Optic Neuritis.** *Annales d'Oculistique*, Aug., 1909.

The author here describes a case which emphasises the necessity of early decompression in cerebral tumour.

The patient was a man, aged 53, who had suffered from Jacksonian epilepsy for six years, with failing sight for four years.

When seen the vision of the right eye had sunk to counting fingers at $1\frac{1}{2}$ metres, and that of the left to perception of light only. Both discs showed advanced post-papillitic atrophy. The skull cap over the right hemisphere was opened and a tumour found which could not be completely removed. The vision improved so that with the right eye he could count fingers at $3\frac{1}{2}$ metres. The fits continued in a modified manner, consciousness no longer being lost. The tumour was found to be a psammoma.

The case is important as it shows the possibility of improvement of vision even in the late stages of the disease. At the same time, even if the tumour cannot be removed, the other cerebral symptoms, headache, vomiting, vertigo, and epileptiform attacks, will be greatly modified and the patient's distress more or less completely relieved. The one disadvantage of the operation is the cerebral hernia which so commonly results.

E. W. Brewerton.

Elliot (Madras). **A Preliminary Note on a New Operative Procedure for the Establishment of a Filtering Cicatrix in the Treatment of Glaucoma.** *The Ophthalmoscope*, December, 1909.

In this paper Major Elliot describes a simple method of obtaining a permanent filtering cicatrix between the anterior chamber and the subconjunctival space. The operation consists in removing with a corneal trephine a disc of sclerotic close up to

the limbus, after previously dissecting back a long strip of conjunctiva to form a flap. The iris may or may not be cut off as it presents in the wound. He has now performed the operation in fifty cases and has never failed to relieve tension, nor has he met with any serious accident. He claims for the procedure that, although it gives as satisfactory a filtering scar as the operations of Lagrange or Herbert, it is free from the dangers of the former and the difficulties of the latter. The only difficulty he has met with is the failure to open the anterior chamber as a result of not keeping close enough to the limbus. This only occurred in three of the earlier cases.

In an account of a similar operation given by Freeland Fergus at this year's meeting of the British Medical Association, in which no attempt was made to enter the anterior chamber with the trephine, the operation was combined with a cyclodialysis. The impossibility of making a trephine of this type really sharp is a serious objection to the operation. The author describes his paper as only in the nature of a preliminary note, and possibly we may hope to hear something more of the later results, the absence of which in so many of the Indian operative statistics renders them of little value for comparative purposes.

E. E. H.

The Illuminating Engineering Society.

Professor Sylvanus Thompson presided at the opening meeting of the above Society on the 11th of November last.

He delivered an inaugural address in which he defined the object of the Society to be the bringing together of all those interested either in the production of light or in its proper use.

The establishment of a universal standard photometric unit was one of the first problems to be attacked. Professor Thompson expressed himself as in favour of the foot candle. As examples of the physiological problems of interest to the Society he instanced the questions of whether the amount of contraction of the pupil depended on the total amount of light entering the eye or upon the illumination of one part of the retina only, and how great was the specific brightness of surface that could be regarded without discomfort.

Referring to public questions, he instanced the question of proper lighting in schools, insisting that the illumination of the desks should be exactly measured by means of an illumination photometer, and a fixed numerical standard demanded. He stated that ophthalmic surgeons are agreed that insufficient illumination is the prime cause of myopia. This statement requires a good deal of qualification.

W. H. McMullen.

THE OPHTHALMOLOGICAL SOCIETY OF THE UNITED KINGDOM.

Thursday, December 9th, 1909.

Vice-President, Mr. W. H. H. Jessop, *in the Chair.*

A case of Tubercle of the Choroid, shewn originally on October 17th, 1907.—Mr. S. Stephenson.

This case was shewn as one of tubercle of the choroid, a description of which will be found in the Transactions of the Society, Vol. xxviii, Fasc. I, and the condition of the fundus at that time is illustrated.

Mr. Stephenson shewed the case again, and noticed the improvement that had taken place in the meantime; the treatment adopted was fresh air, and a tonic of iodide of iron; tuberculin injections had not been used. The vision in both eyes was $^{6}/_{12}$. The right optic disc was pale as compared with that of the other eye, and the original changes were replaced by two contiguous greyish-white masses lying a short distance above and to the outer side of the disc; the inner part was speckled with pigment. There was still a defect for white involving the greater part of the lower and inner quadrant of the field of vision.

The left eye shewed only slight retino-choroidal changes.

Abnormal Congenital Pigmentation of One Eye.—Mr. N. Bishop Harman.

Winifred B., aged $2\frac{1}{2}$, shews the iris in the right eye almost black, so that at a short distance it is difficult to distinguish between the pupil and the iris. The fundus is a deep slaty blue black colour, and the sclera in all parts shews many deeply pigmented blotches. The ocular and palpebral conjunctiva is not pigmented. There is nothing characteristic in the family history; the father has dark brown hair and light brown irides, and the mother has both dark brown hair and irides.

Mr. Harman referred to a similar case shewed by himself in 1905, and reported in the Transactions, Vol. xxv, p. 318. He also remarked on the frequent occurrence of unusual pigmentation in the sclera of black-haired dogs.

Retinal Nævi.—Mr. N. Bishop Harman.

Mary C., aged 61, attended the West London Hospital with the history of having lost consciousness in July of this year, though on recovery there was no loss of power or speech. There was some thickening of the arteries in the limbs. The vision in the right and left eyes with correction (which was +9 and +11 respectively) was $^{6}/_{18}$ pt. Both fundi shew indistinctness of the edge of the disc, with some development of connective-tissue which in places follows the course of the vessels for a short distance; the latter are thickened and tortuous. The right fundus, in addition, shews 2 patches of red colour which were

considered to be either nævi or hæmorrhages; one, perfectly circular in shape, was situated over the lower nasal vein 2 P.D. from disc; and another smaller oval one a short distance from a cilio-retinal vessel.

The fact that these patches had existed for some time without altering their characteristics led Mr. Harman to consider them nævi of the retina in spite of the presence of vascular changes.

An Orbital Frame for Eyeglasses, and its adaptation for a Ptosis Prop.—Dr. Rayner D. Batten.

These orbital eyeglass frames depend for their attachment to the face on two rigid or nearly rigid wires attached to the lower part of the frame and accurately adjusted to the nasal margin of the orbit, and terminate in a free end lying immediately beneath the upper margin of the orbit. They are dependent, not on a spring, but on the accuracy of their fit; and by virtue of their application to the orbital margin require a more or less prominent eyebrow and a deep set eye.

Opacities of the Cornea of unusual character.—Mr. A. H. Payan Dawnay.

M. R., aged 21, came for advice regarding the condition of her left eye. The vision in the right was $^{6}/_{6}$ with correction, and that of the left perception of light with indifferent projection. The conjunctiva of the left eye was healthy, the pupil inactive and incapable of dilatation owing to the presence of posterior synechiæ; the lens is cataractous, shrunken, and calcareous.

All over the surface of the left cornea are a number of elevations, some round and others oval-shaped 2 or 3 mm. broad, containing semi-translucent material. There was no vascularity and no infiltration of the corneal tissue.

When 5 years old this patient sprained her ankle, which was followed by an affection of knees, elbows, and some joints in the hands, resulting in ankylosis and permanent deformity. Not long after this the left eye "became bad," though no definite history of injury or disease could be obtained. There is no tubercular history in the family or in the patient herself, but there is extensive pyorrhœa alveolaris. The general opinion was that the corneal condition was of a degenerative nature, as a result of some quiet cyclitis.

A Hæmorrhage at the Macula.—Mr. Malcolm L. Hepburn.

Charlotte S., 41, complained that, on November 22nd, 1909, she woke up and found all objects appeared red to the left eye, and this condition had lasted ever since. There was no history of any serious illness, but she felt she had not been quite so strong as formerly since a bad confinement 10 years ago, and she was decidedly anæmic.

On December 1st, when first seen, the vision in the right eye was $^{6}/_{9}$, and that of the left $^{1}/_{60}$; the pupils were equal and acted well to light.

On examination of the fundus of the left eye, there was present in the macula a perfectly circular dark-red hæmorrhage about 1½ disc diameters in size; the margin was distinctly darker all round the circumference than the other parts of the extravasation, and exactly in the centre of the patch was a brilliant white reflex. The relation of the retinal vessels to the hæmorrhage could not be accurately determined; and the field for white shewed a central relative scotoma.

On December 8th, the hæmorrhagic area was decidedly smaller, and had diminished concentrically all round, the same well-defined edge being still present. The vision, however, remained the same.

The question arose as to whether this hæmorrhage was an ordinary subhyaloid or whether it was a hæmorrhage into the retinal substance, and if the latter whether the blood had its origin from the retinal or choroidal vessels. There was some difference of opinion on these points, but the view expressed by the majority was in favour of a subhyaloid hæmorrhage owing to the presence of the symptom of red vision.

Papers.

(1) *Description of a form of Conjunctivitis.*—Mr. R. W. Doyne.

The onset of this particular variety of conjunctivitis was characterized by tickling in the eye, congestion of the ocular conjunctiva, more especially over the part exposed in the palpebral aperture, and generally spreading later over the rest of the bulbar conjunctiva; this is accompanied by pain and great irritability. There is little discharge, but the attacks were noticed to be accompanied by secretion from the Meibomian glands. Cultures were obtained, with the result that staphylococcus aureus was cultivated, and Mr. Doyne regarded the conjunctivitis as due to an infected condition through the Meibomian glands. These attacks recurred about every 10 days, and took from 6 to 12 days to clear up.

The treatment adopted was staphylococcal injections once every 10 days, and local application of argyrol to the conjunctival sac. For 3 months afterwards no attack occurred, and the patient went to West Africa, where the condition again relapsed. When home on leave he was treated in the same way and kept free for 6 months.

(2) *Myopic Degeneration of the Lens (with a patient).*—Mr. R. W. Doyne.

On December 13th, 1888, Mr. Doyne shewed a case of "Peculiar form of degeneration of the lens" in a lady of 70; the refraction through the periphery being −3 D, and that through the centre −14 D. At the time the case was criticized and regarded as one of posterior lenticonus, but Mr. Doyne considered that the condition described as degeneration was characteristic though not generally recognized. With oblique illumination there appears to be a dense opacity in the centre of the lens which

at first seems difficult to regard otherwise, but this opacity is really only apparent, and is produced, according to Mr. Doyne, by the reflection of the rays of light from the sudden increase in the refractive index towards the centre of the lens. On ophthalmoscopic examination the retinal vessels are distorted.

(3) *Note on a Form of Iritis.*—Mr. R. W. Doyne.

The type of iritis here alluded to has been given the name of guttate iritis, and is characterized by small spots resembling drops of lymph on the pupillary margin; it is a rare condition but a definite type, generally seen in elderly people more commonly women, who are obviously gouty. These spots arise without any obvious sign of inflammation, and it is only when they adhere to the surface of the lens that inflammatory symptoms arise, though it is not uncommon for iritis to occur at parts other than where the spots exist. Apparently cases shewing this condition are liable to attacks of iritis. Mr. Doyne thinks they may be due to exudation between the epithelial layers of the iris which are reflected at the pupillary margin, and he also finds that these guttate spots do not readily become adherent to the lens with which they are in contact.

(4) *A note on Family Choroiditis (with patient).*—Mr. R. W. Doyne.

A patient was shewn illustrative of cases of family choiroiditis; several coloured drawings were brought before the Society in March, 1899, representing the fundi of four members of a family shewing this variety of choroiditis. The appearance is one of guttate choroiditis affecting the disc macula region, the spots being closely grouped, separated sometimes by pigmentation, but more often by none. The disease comes on in adult life, and there appears to be no special family diathesis associated with it.

A Congenital Sarcoma of the Orbit.—Mr. M. S. Mayou.

A. P., aged 12 days, attended the Central London Ophthalmic Hospital on March 13th, 1908. This was the first child, and apart from the eye it presented no congenital abnormalities. The right eye was perfectly normal, but filling up the left orbit and protruding from it was a red, slightly œdematous, mass; it was irregular on the surface and covered by conjunctival epithelium except in one part where it was exposed in the palpebral aperture, and here some ulceration had commenced to take place. There was no enlargement of the pre-auricular gland.

The orbital contents were eviscerated, and the diminutive globe, situated behind the tumour, was cut into at the time of the operation. On June 16th of the same year the child returned with a

recurrence filling the entire orbit. Evisceration was again performed, and four weeks later the child was lost sight of and has not been heard of since, though no record of death can be found from official returns.

On microscopical examination, the anterior parts of the globe were found to be normal; the posterior part was intimately connected with the tumour. The growth itself consisted of cell bundles which were arranged in different directions and shewed no mitosis; the character of the cells and their arrangement were typical of spindle-celled sarcoma. Sarcoma of the orbit is by no means uncommon in young children, but congenital tumours of this nature are distinctly rare.

A Round-celled Sarcoma of the Lacrymal Gland.—Messrs. A. P. L. Wells and M. S. Mayou.

M. A., a female, aged 66, was admitted into the Central London Ophthalmic Hospital on January 14th, 1907, with a swelling at the upper and outer part of the left orbit which had lasted about 4 months. The tumour was about the size of a walnut with irregular surface, soft and almost fluctuating. By April 8th it had increased in size so much that the eye was displaced downwards, but the neighbouring glands were not enlarged, and there was no dissemination. The tumour was excised and found to be encapsuled.

On microscopical examination, the growth was surrounded by a capsule which in places was infiltrated with round cells of the size of ordinary lymphocytes, and these formed the bulk of the tumour. There were no signs of degeneration, but mitosis was well marked. Scattered throughout the specimen were remains of glandular epithelium which had undergone changes; some new vessels were observed, and others which obviously belonged to the original gland tissue.

Tumours of the lacrymal gland are difficult to classify owing to the difficulty in recognizing their source of origin, as well as to the fact that secondary changes have altered their structure. According to whether they arise from the epithelial elements, the fine mesoblastic supporting trabeculæ, or the lymphoid tissue, so we meet with adenomatous carcinoma, myxosarcoma, or lympho-sarcoma.

Mr. Mayou entered into the literature of sarcoma of the lacrymal gland, of which nine cases appear to have been described, all in patients over 38; one probably only attacked the gland secondarily from the orbit, and 2 others were bilateral and of the nature of endotheliomata. The characteristics of these tumours are that they occur late in life, are of very slow growth, do not tend to infiltrate rapidly, and do not lead to glandular enlargement. MALCOLM L. HEPBURN.

A NEW SIMPLE OPHTHALMOSCOPE.

By Priestley Smith.
Professor of Ophthalmology in the University of Birmingham.

This ophthalmoscope, though very simple in form, as shown in the illustration (Fig. 1), is to some extent new in principle. The body or handle is a flat strip of black celluloid, this material being used because it is tough and not brittle. It carries two mirrors, one *plane*, the other *condensing*, though not concave. A white concave disc inserted in the handle near to the condensing mirror distinguishes it from the other at a glance, or by touch when the instrument is in the hand. Behind each mirror is a socket in which any lens from the ordinary trial case, up to about + or − 10.D., can be placed. The instrument is intended chiefly for the shadow test, for examination of the media, and for the indirect method of examining the fundus. In the consulting room, where the trial case is at hand, it answers well for the direct method also. Elsewhere, at the bedside for example, it must be supplemented by a few trial lenses if it is to be used for this latter purpose.

The chief novelty of the instrument lies in the construction of the mirrors, which, though not perforated, are free from a disadvantage hitherto inseparable from the non-perforated form. A perforated mirror has the advantage that the sight-aperture cannot become clouded by dust or moisture, but it has the disadvantage that the sides of the tunnel in the glass, however skilfully this

may have been bored and blackened, are apt to reflect light into the observer's eye; this drawback is usually minimised by making the mirror extremely thin, but such mirrors are easily broken. A non-perforated mirror has no tunnel to cause confusing reflection and need not be thin, but, as hitherto made, it presents a difficulty as to cleaning. If the back of the mirror is unprotected, as in the Simple Ophthalmoscope for the Shadow Test described by myself many years ago (O.R. 1884, p. 266), the silver coating is soon injured by the necessary wiping, while if it is protected by a metal back, the hole in this latter forms a pit which collects dust and prevents thorough cleaning of the glass.

In the new instrument the back of each mirror is protected by cementing upon it with Canada balsam a disc of glass of the same diameter as the mirror itself, so that the combination forms practically a solid glass disc having a reflecting film of silver embedded in it like a fly in amber. Figure 2 shows a plane mirror protected in this way. A concave mirror, the back of which is of course convex, could be protected in like manner by using a concave instead of a flat protecting glass, but the desired result is obtainable in a better way. A condensing mirror is not necessarily concave.

If an ordinary bi-convex lens be placed immediately in front of a plane mirror, light reaching the mirror through the lens will be reflected as from a concave mirror, and the power of this compound reflector will be double that of the lens, for the light passes through the lens twice. Applying this principle for the purpose of an ophthalmoscope, we take a plano-convex lens of 2 D. (50 cm. focus), silver the plane surface, blacken the free surface of the silver, remove the coating from a small central area, and cement a flat disc of glass upon

it (Fig. 1, b). This gives a condensing mirror of 25 cm. focal length, and when it is used as an ophthalmoscope the observer has a lens of +2.D. before his eye. The solid combination has an advantage over a perforated concave mirror of equal strength with a supplementary convex lens behind it. In either case there is one thickness of glass before the eye, but the new mirror has no tunnel, is practically unbreakable, and can be wiped as easily as a trial lens. For the presbyope who habitually needs a convex lens behind his mirror for the indirect method, such a permanent combination is very convenient.

The condensing mirror can be made of any desired focal length by using a plano-convex lens of twice that focal length. The effect of this lens in relation to the observer's eye can be neutralised, or it can be increased or diminished to any desired extent, by substituting for the flat protecting glass a suitable plano-convex or plano-concave lens (Fig. 2, c and d.). If the observer be ametropic and desire to have a correction of his refraction embodied in the instrument, this can be effected by using a plano-spherical, a plano-cylindrical, or a toric lens, in the same way, though where the two eyes are unequal and both eyes are used in ophthalmoscopic work the same instrument would not be suitable for both.

The maker of this ophthalmoscope is Mr. R. Bailey, Bennett's Hill, Birmingham. He has devoted much time and skill to its details and has taken steps, with my approval, to protect it from incorrect imitation.

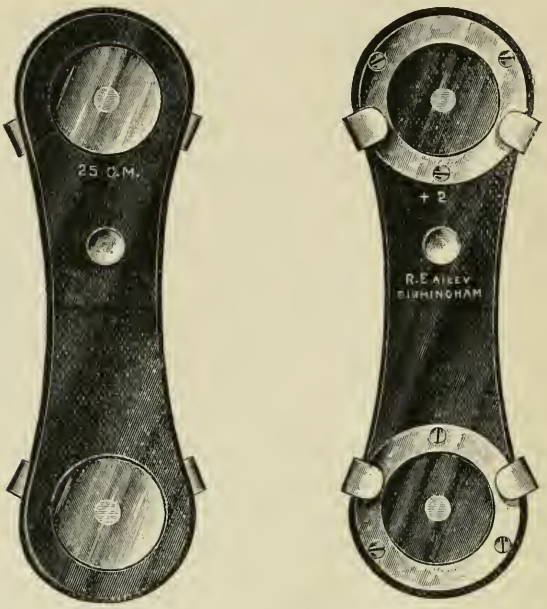

Fig. 1.

Two-thirds of actual size.

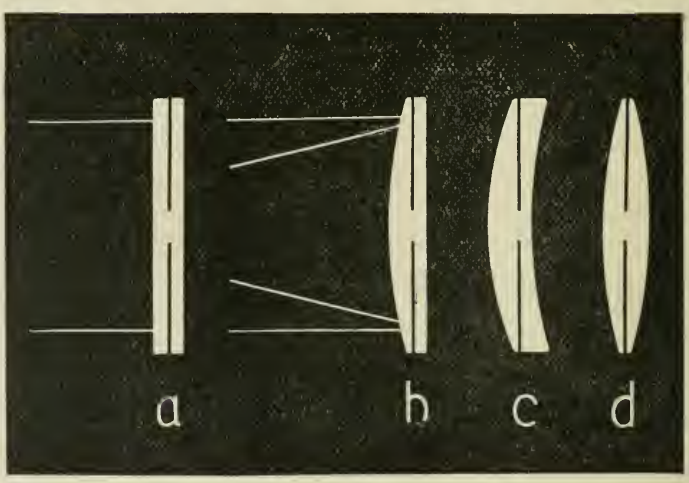

Fig. 2.

REVIEWS

Carl Hess (Würzburg). **The Yellow Colouration of the Human Lens; its Estimation and its Influence on Vision.** *Archiv für Augenheilkunde*, lxiii, 2, p. 164.

It is well known that the lens has frequently a yellow tint, and in advanced life a yellowish-red tint, sometimes of considerable intensity. It has been surmised that the relative perception of certain colours is modified thereby, and some have asserted that this influence is manifest in the pictures painted by certain artists late in life. Hering, examining lenses removed after death, demonstrated an absorption of violet, blue and blue-green rays, increasing with age. Helmholtz regarded the colour of the lens as negligible in relation to colour perception in healthy eyes. Proof of its influence has hitherto been wanting. Hess has now supplied it. In a previous article he showed that the colouration of the lens may reach such a degree as to involve blue-blindness, although visible opacity and defect of ordinary vision are absent. He now describes a subjective method by which the effect of the lens-colour in the living eye can be accurately measured, and an objective method by which the colour can be rendered manifest.

To an eye well adapted for darkness, all coloured light, when of sufficiently low intensity, appears colourless. The spectrum, for example, appears throughout as a colourless band brightest in the region of the green. To such an eye a feebly-illuminated white surface, reflecting blue rays only, will appear grey, and will appear darker or lighter according to the amount of the blue light which is absorbed during its passage through the crystalline lens. A similar surface reflecting only red-yellow rays will likewise appear colourless, but its apparent brightness will not be affected by the greater or less colouration of the lens, for such rays are little, if at all, obstructed thereby. By means of a very simple apparatus Hess applies this principle to the problem in question.

The instrument is a long, horizontal, closed wooden box, emitting light through an aperture in the middle of one side. One-half of the aperture is covered by a blue glass, the other by a red-yellow glass, the line of junction being vertical. Standing behind each coloured glass, and meeting it at the line of junction at an angle of 45°, is a white reflecting surface,

illuminated by an electric lamp in its own half of the box. The illumination of either can be increased or diminished by sliding the lamp along a scale, and can be lowered to any degree. Above the main aperture is a much smaller one serving as a fixation point for the eye under examination, so that the main aperture is pictured near to the macula, but not on it, and the influence of the macular pigment is avoided. The test is made in a dark room, the eye being adapted to darkness, and the light proceeding from each half of the aperture so feeble as to appear colourless. If the position of the lamps be so adjusted that for one observer the two halves of the aperture appear equally bright, then an observer with more yellow colour in his lens will see the blue half darker than the red, while one with less with see it lighter. In all tests the illumination of the red half remains constant, while that of the blue is varied until apparent equality is reached.

The margin of error, determined for several eyes separately, was found to be small. The average blue illumination giving apparent equality having been found, the extent to which it could be varied without apparent change was ascertained. For Hess himself an increase of 0·11 and a decrease of 0·18 were always recognisable; for some others the margin of error was still smaller.

By examining in this way a number of lensless eyes properly corrected—cases of cataract extraction with good vision—Hess obtained a standard by which to measure the absorption power for blue in normal lens-containing eyes. This *specific absorption* is expressed by the formula $\frac{n-1}{n}$ where n shows the number of times which the standard blue illumination must be increased for the eye in question in order to give apparent equality. Hess found that his own lens had a specific absorption of 0·248; in other words, that it is absorbed nearly one-fourth of the blue light employed. This being ascertained, he could at any time, by adjusting the lamps for his own eye and then making the necessary reduction of the blue, re-obtain the standard for the lensless eye, and thus avoid errors which might have arisen through variations in the power of the electric lamps.

A series of healthy eyes belonging to different life periods were tested. The yellowness of the lens varied considerably, even in persons of the same age, but on the whole increased decidedly with the advance of life. Among eight persons over

50 years of age, seven showed an absorption of more than half of the blue light employed, in some cases much more; among twelve persons under 50 years of age, it was less than one-half in every case. In this whole series the minimum absorption was 0·10, the maximum 0·85. For example, an artist (painter), aged 57, was tested with regard to the comparative colour perception of his two eyes, one of which was normal, the other lensless through cataract extraction. His remaining lens absorbed more than 2-5ths of the blue light employed. In another case of the same kind, at the age of 74, the remaining lens absorbed more than one-half.

Hess was able to establish a scale of visible colour, corresponding with the various degree of colour in the living lens as estimated by the test described, by using a graduated wedge of yellow glass. That part of the wedge which absorbs the same amount of blue as does the lens of a given eye has presumably the same colour as the lens of the eye in question.

Further, he found it possible to demonstrate the colour of the living lens by employing strong focal illumination with blue light obtained by placing a blue glass over an aperture in an opaque chimney surrounding a Nernst lamp. In the spectroscope this glass transmitted some green and some of the extreme red in addition to the blue. Under such illumination the pupil in early life appeared dark and nearly colourless; at 20 to 30 years of age it presented a shimmer of green; at later stages this became stronger and stronger. Between 50 and 60 the pupil of a perfectly normal eye was often surprisingly green, and sometimes decidedly brighter than the surrounding iris, especially was this so in brown-eyed people. When a lighter blue, which transmitted also some green and yellow-green rays, was used, the pupil in advanced life looked dark yellow. The phenomenon depends on the fact that the blue rays penetrate the lens a certain distance and are then reflected, thus passing twice through the layers which they penetrate.

These researches in "Xanthometry" of the lens prove beyond question that the colour of the lens in advanced life does modify colour perception to a considerable extent, and this fact may be confirmed without apparatus by any good observer whose one eye has been operated upon for cataract. The artist, aged 57, already mentioned, when shown a strip of white paper on a dark ground, declared it to be "white" to the lensless eye, "yellow" to the other; a blue paper appeared considerably brighter to the one than to the other. An architect, aged 51,

saw a white paper "white" with the lensless eye, "cream-coloured" with the other; a dark grey strip on a bright ground appeared "grey" to the operated eye, "sepia" to the other. A patient, aged 74, said, 14 days after cataract extraction, that he saw with his operated eye "as through a blue glass."

The specific absorption in each case being known, a young person can form a judgment of the colour perception of an elderly person by looking through a suitable yellow glass; on the other hand, an elderly person can recover the colour perception proper to early life by looking through a suitable blue glass and increasing the illumination by the necessary amount. Hess suggests that an accurate estimate of their loss of blue perception, such as his test offers, should be of interest to artists. He notes the case of a celebrated artist who in advanced life painted by the electric arc light which combines great intensity with an excess of blue rays.

(These interesting researches do not, of course, justify the supposition that a painter whose lens is yellow will necessarily use false proportions of blue and yellow in his pictures. If his lens absorbs, say, one-half of the blue light entering his eye from his model, it will absorb also one-half of that coming from his canvas, although the illumination of the two be different, provided that the two blues be of the same nature. Both model and canvas will appear less blue to him than to a younger man, but if the one correctly represent the other to him, it will do the same to the younger man. But there seem to be two possibilities of error. If, instead of accurately reproducing the feeble blue which he sees in his model, he strives to represent the stronger blue which he used to see, and would still like to see, he will be likely to overload his picture with blue; whereas, if his perception of blue is so far diminished that the fainter blues in his model pass unnoticed, his picture may conceivably be deficient in blue.)

P. S.

Meller (Vienna). **Intraocular Sarcoma and Sympathetic Inflammation.** *V. Graefe's Archiv für Ophthalmologie*, 72, 1.

Probably no pathological problem, certainly so far as the eye is concerned, has presented so many difficulties in its solution as that of sympathetic ophthalmia. It was with a view to the elucidation of this complicated and obscure condition that Dr. Meller took up the study of those cases of

intraocular sarcoma in which the eye containing the tumour, as well as the other eye, became affected with sympathetic inflammation. He seeks to add a new theory to the many which have gone before.

He begins by giving a summary of our present knowledge on this subject, which may be briefly stated as follows:—

Sympathetic ophthalmia, whether occurring spontaneously or, as is more commonly the case, after a wound, is a specific disease of the uvea, with certain histological characteristics, viz., granulation tissue consisting of lymphocytes, epithelioid and giant cells; it is specific, just as tubercle or syphilis is specific, and is due to a definite virus. Not only is the histological picture, but the site of the disease also, peculiar to this affection. It is the uvea which forms the soil where the germs first grow both in the primarily and secondarily affected eyes.

Meller deplores the fact that so much time has been devoted to the explanation of the mode of infection of the second eye. The first question to be settled is, "How does the first eye become infected?" In considering this question Meller points out that *à priori* there are two ways, the one *via* a perforating wound, the other endogenous. Indubitable proof of the former is wanting, whereas no one can deny the possibility of an endogenous infection attacking a previously damaged eye. Wishing to confine his investigation to those cases of sympathetic ophthalmia which have arisen without any possibility of ectogenous infection, he examined eyes suffering from intraocular sarcoma in which sympathetic ophthalmia had supervened, and he gives the details of such a case.

His patient was a waiter, 28 years of age, who had been blind in the left eye for seven years. The right eye had recently become painful and the vision misty. There was no evidence of syphilis, inherited or acquired. There was no articular rheumatism, and the urine was normal.

The right eye was obviously suffering from an irido-cyclitis; there was dusky ciliary injection, muddy iris, and copious deposit on the cornea; the tension was normal. Its vision was counting fingers at 4 metres, and the fundus could not be seen.

In the left eye there was conjunctival and ciliary injection, and the cornea presented a peripheral vascular haze. The iris was congested, and at its lower outer part showed some white specks on a markedly hyperæmic ground. Through the dilated pupil could be seen a distinct mass of yellowish-green colour.

The tension was normal, and the fundus was not visible. The eye was blind. Both eyes went gradually from bad to worse. The left eye became more inflamed, presented corneal infiltrates and precipitates on its posterior corneal surface, and was ultimately removed because of pain.

The enucleated eye was submitted to a very careful examination, the details of which are minutely described: we can only mention the more salient features. The hinder part of the globe was occupied by a nodular mass which had perforated through the sclera behind. Histologically, the cornea presented infiltration at the limbus with numerous vessels, and lying in its deepest layers, immediately adjacent to Descemet's membrane, was a mass of lymphocytes enclosing epithelioid cells similar to other masses found in the iris and ciliary body. The original tissue of the iris had almost disappeared, and it was more vascular than usual. There was a mass of connective-tissue behind, which had drawn the iris backwards. The filtration angle was occluded by the root of the iris, which was adherent to the posterior surface of the cornea. The ciliary body was also infiltrated. There were plasma cells and typical epithelioid and giant cells as well as lymphocytes. This had extended into the interior of the eye, and the posterior chamber was filled with infiltration. There was an anterior capsular cataract, and a thin layer of exudate lay on its surface. The lens indeed was embedded in a fibrous tissue mass and separated at its equator from the ciliary body above by a space occupied by spindle-shaped cells. Bounding the posterior surface of the lens below was an old extravasation of blood. The choroid anteriorly was infiltrated and destroyed almost beyond recognition. The posterior part of the globe was filled with nodules of varying size and well defined. Histologically, these proved to be spindle-celled sarcomatous masses, extremely cellular, with very little intra-cellular tissue. The blood-vessels were scanty, and some necrosis had taken place. The sclera behind merged into a firm fibrous mass in which nodules of the growth were situated. The sarcoma was observed to arise from the inner part of the choroid, and this latter also contained nodular infiltrates of inflammatory origin. The cells indeed invaded the growth so that the boundary between the two was entirely destroyed. Other nodules showed less intimate relationship to the inflammatory infiltration. Old blood-clot gave evidence of previous hæmorrhage. No bacteria were present.

The evidence is in favour of the eye blinded by intraocular

sarcoma, having become attacked, at one time, by a severe plastic inflammation. This arose from necrosis taking place in the tumour which had extended so far as to fill the whole of the globe. The sympathetic changes had existed at least three months and were probably not much older. Continuous serial sections were made, and no signs of any communication with the exterior could be found; anteriorly the coats were not perforated, and posteriorly the tumour was confined within the orbit and had not penetrated to the nasal cavity. The sympathetic inflammation was similar in every detail to the classical description by Fuchs, though the corneal infiltrate, extending in sector-like manner towards the centre of the cornea, had the clinical appearance of sclerosing keratitis. Meller believes that the sympathetic infiltration had only a recent relationship to the sarcoma.

Meller has examined the literature on this subject, and finds 8 cases recorded by Schirmer and 3 by Fuchs in which intraocular sarcoma in the one eye gave rise to sympathetic inflammation of the other, and in which any communication with the exterior could be definitely excluded. These cases gave undoubted proof of an endogenous infection, and therefore he considers that the endogenous mode of infection in all cases of sympathetic ophthalmia must be considered, even in cases following perforating injuries. He believes that the microbes are probably only occasionally present in the circulation. He further states that sympathetic disease always attacks an eye in which the uvea has been previously damaged and that the specific germs are unable to develope in a sound uvea. This previous injury is most frequently due to a perforating wound with its complications, such as adhesion of the iris to the cornea, etc. In the majority of these eyes evidence of a plastic inflammation is present, due to a previous intraocular inflammation which does not belong to the sympathetic inflammation. Further, the greater this previous inflammation the more the uvea is destroyed, and so less soil remains for the growth of the germs of sympathetic disease. This explains the rarity of sympathetic ophthalmia in cases of panophthalmitis.

Another important factor in bringing about uveal damage is an intraocular sarcoma, and in these cases too the uvea shows signs of a previous inflammation separate from the subsequent sympathetic infiltration. This antecedent plastic irido-cyclitis is due to extensive necrosis of the tumour.

Meller, therefore, sums up the above cases by stating that there is always present a previous tissue damage affecting the uvea, and this forms a favourable nidus for the specific germs.

What are the facts which speak in favour of an endogenous infection? Fuchs found in 200 eyes which had been removed on account of the danger of sympathetic ophthalmia definite histological evidence of sympathetic disease in only 29, and expressed considerable surprise thereat.

Heerfordt's opinion was that the eye becomes reinfected by germs entering, at a subsequent date, through the old wound in those cases when the onset of the disease is late; this supposition being required in order to provide an ectogenous source of infection. Meller considers this explanation decidedy forced, especially with regard to cases of subconjunctival rupture of the sclera, where the germs must be credited with considerable power of penetration.

Meller holds that all these hypotheses are unnecessary, and there is no need for surprise at the results of Fuch's examinations, if one bears in mind the cases of sympathetic ophthalmia occurring in eyes affected by sarcoma, and therefore thinks of the possibility of an endogenous infection. Although so many of these eyes, which had been enucleated for fear of sympathetic disease, showed no direct evidence of this; they were nevertheless capable of being attacked at any time, for they contained a soil fitted for the development of the disease. With rgard to the onset of sympathetic disease some years after the injury, Fuchs is again quoted as having shown the presence of quite recent infiltration in those eyes, in which also there was evidence of old plastic inflammation dating back to the time of the initial injury The explanations offered by Fuchs are discussed, and Meller once more offers endogenous infection as a possible and ready explanation. The germs in the circulation attack the damaged uvea, and sympathetic inflammation arises, which soon after leads to metastasis in the other eye. Should the originally damaged eye be enucleated just before the germs attack it, then of course, the histological findings would be negative, but if just after, then histological evidence of quite recent infiltration would be found.

In additional support of this theory of endogenous infection is quoted a case described by Fuchs where disseminated isolated choroidal infiltrates occurred in an eye enucleated five days after a perforating wound. This choroiditis Fuchs believed to be sympathetic, and he also considered that these foci had

arisen separately, and, like miliary tuberculosis of the choroid, were due to infection *via* the blood-stream. This similarity to miliary tubercle is strong evidence in favour of an endogenous infection. Again, sympathetic ophthalmia may arise in cases of phthisis bulbi even when no signs of irritation are present and the characteristic histological picture can be demonstrated. "Such cases," says Meller, "are easily understood, by the acceptance of an endogenous infection." In cases where the choroid is the seat of the disease there would be no pain or evidence of irritation, the eye remaining quiet until the ciliary body and iris took part in the disease.

How do the germs get into the body? Meller adds that he does not wish to deny that the germs may sometimes enter the body through the wound in the eye. Although he refers to endogenous infection, it is obvious that the germs must enter the body from without in the first place. This may take place either through a lesion of the skin or mucous membranes, and in some cases it may be through the wound in the eye itself, although he regards this as the exception rather than the rule. A solitary objection to the theory of endogenous infection is put forward by Schirmer, who says that the uveal inflammation which a splinter, introduced aseptically, produces, never gives rise to sympathetic inflammation. Meller considers that this statement has not been proved. On the other hand, many observers have reported cases where intraocular sarcoma led to phthisis bulbi and later on to sympathetic disease. In certain of these infection must have been endogenous beyond doubt. Meller sums up, therefore, that the primarily important factor is a tissue damage (of traumatic, bacteriological, or chemical nature), and the pathogenicity of the germs in this soil is so increased that the uvea of the sound eye can no longer offer resistance.

BEATSON HIRD.

DR. CARL BEHR. **Complicated Hereditary-Family Optic Atrophy of Childhood.** (A new symptom-complex.) *Klinische Monatsblätter für Augenheilkunde*, Aug., 1909.

IN a well-written and carefully-thought-out paper Behr describes six cases of a family disease of a nature never described before. The following is a typical history of one such case:—

Boy, 9 years old. Birth normal. His sisters all normal. Parents normal and not related to each other, and no nerve or

eye disease to be found in the family. No syphilis (blood reaction). Patient learnt to walk and speak in his second year. At about the same time the parents noticed that the boy could not see well and that his walking was stiff and unsteady. The boy had difficulty at school, and made no progress. He was easily annoyed and became angry on slight cause. No cramps or convulsions. The condition of the vision remained stationary. Occasional dribbling of urine.

Present condition: Pupils normal in appearance and reaction. Eyes emmetropic. There is a fine horizontal nystagmus, which becomes much more marked and coarser on monocular fixation. While at rest with both eyes uncovered the nystagmus disappears almost completely.

Ophthalmoscopically: Right, disc white on the temporal side, otherwise normal; left, disc totally atrophic.

Vision: B.E. $^{2}/_{50}$, no improvement with glasses.

Field of vision: Central scotoma for colours, and irregular concentric narrowing of the field.

Physically, the boy is moderately well-developed and nourished. Skull somewhat asymmetrical. Bilateral cryptorchism.

Musculature: Increased tone of muscles, especially of right side. Increased knee-jerk, right greater than left. Babinsky right well marked, left doubtful. No ankle clonus. Definite ataxia of right arm and leg. Left not so marked.

Sensation normal. No tremors. The boy walks stiffly, legs well separated. Body bent forward, but deviates from side to side with occasional dragging of toes. The instability of the body is more marked on walking with closed eyes.

Slight Romberg. Speech clear and distinct.

Intelligence: Defective memory—simple arithmetic cannot be done.

Cranial nerves normal. Condition becomes no worse after fatigue.

This history does for all 6 cases cited. The ages varied between 3 and 13. They were all boys. Two of the cases were brothers; and the child of 3 showed in one eye a slight optic neuritis, which in the course of time disappeared, leaving the temporal pallor of the disc seen in the older patients.

The cases, therefore, all show a bilateral, chiefly temporal, optic atrophy, central scotoma, much diminished visual acuity, mild spasm and increased reflex irritability in the extremities, without any pareses, mild ataxia, unsteady deviating walk,

weakness of the bladder, and a somewhat diminished intelligence.

In the consideration of these cases one finds three main systems involved. First, the optic system, and the affection must lie peripherally to the chiasma; secondly, the co-ordinating paths are affected, and, thirdly, the pyramidal tracts. In the various family or hereditary nervous affections so far described it is chiefly these three systems which are attacked; and these may be rapidly reviewed.

Leber's atrophy—and, as far as the optic system is concerned, this disease agrees exactly with the one at present under discussion, but the remaining nervous symptoms suffice to distinguish it, for in the true Leber cases these do not occur at all. The optic system only involved.

Family amaurotic idiocy of Tay. The earlier age of appearance and the ultimate fatal ending differentiates this sufficiently. The optic and motor tracts chiefly affected.

Friedreich's ataxia. Optic atrophy and bladder involvement occurs only rarely, and there is speech disturbance. Co-ordination and the pyramidal tracts chiefly affected.

Cerebellar Heredoataxia of Marie corresponds more closely with our cases, but generally it begins later (about 20). Bladder symptoms always absent, and generally there is paralysis of the 6th nerve and bilateral ptosis. Again pyramidal tracts and co-ordination chiefly affected.

Spastic spinal paralysis occurs between 20 and 30, and optic atrophy rarely occurs. The pyramidal tracts are chiefly affected.

Spastic diplegias. Optic atrophy rarely occurs, and the disease chiefly affects the cerebral portion of the pyramidal tracts.

Disease of the lateral and posterior columns, cerebro-spinal syphilis and congenital myelitis are similarly distinguishable.

Insular sclerosis. This disease may closely approach our form, but is extremely rare in childhood. It very rarely attacks several members of one family, and it occurs more frequently in females. And, further, very few get optic atrophy, and if this does occur, it is generally unilateral. Central scotomata are very rare, etc.

In considering these various diseases one or other of these three systems are affected—(1) Leber's family optic atrophy; (2) spastic spinal paralysis; (3) hereditary ataxia; or we find combinations of any two, like cerebellar heredoataxia, or a

combination of one of these with some other nerve lesion, but this form is a combination of all three. It is most closely related to the Leber type on account of the optic atrophy which is the most important manifestation; and if Leber be called simple juvenile optic atrophy, this disease could be termed *complicated infantile family optic atrophy.*

Of the etiology little can be said. There is probably an inflammatory basis, as in the Leber cases, in the form of a toxic retro-bulbar optic neuritis, and it must be an autointoxication with a congenital, or rather hereditary, basis.

A. Levy.

Weekers and Heuvelmans. **Experimental Formation of a Fistula of the Anterior Chamber by Sclerectomy.** *Archives l'Ophtalmol.*, Nov., 1909.

The experiments recorded by Weekers and Heuvelmans were undertaken by them with the object of obtaining anatomical evidence as to the establishment of a fistula by Lagrange's procedure. The evidence of the production of a permanent fistulous opening by this operation in human eyes has been, so far as the authors are aware, purely clinical, and anatomical evidence is much to be desired. The facts observed in experiment upon healthy rabbits' eyes, although valuable, can hardly be considered as wholly applicable to glaucomatous human eyes.

On Oct. 17, 1908, the right eye of a rabbit, weighing 3 kilogrammes, was operated upon by Lagrange's method of sclerecto-iridectomy. A portion of sclera 1 mm. in width by 1·5 mm. in length was excised close to the cornea, care being observed to remove the whole thickness of the sclera. The eyelids were then closed by a suture, to ensure protection of the wound, for 24 hours. On the next day the anterior chamber was reformed. For several days there was swelling of the conjunctiva about the wound, but after the fifth day the œdema was limited to the site of the sclerectomy; here the conjunctiva was slightly raised, and several spots of pigment were visible in it. This elevation of the conjunctiva persisted until the removal of the eyeball on March 29th, 1909, five months after the operation.

Examination of the eyeball proved that a genuine fistula of the anterior chamber had been established. A small gap existed in the sclera at the limbus and communicated directly with the anterior chamber; on the external surface of the sclerotic the tiny canal became enlarged and opened into a

small pouch in the subconjunctival tissue. The fistula in its intra-scleral course was bounded by scleral tissue, lined by a thin layer of fibrin, in which a little blood and some pigment could be distinguished. A few bands of fibrin stretched across the canal, but did not obstruct its lumen. The subconjunctival cavity was lined by a layer of fibrin containing small collections of pigment. At the opening of the fistula into the anterior chamber a few shreds of iris tissue extended into the canal, narrowing its lumen slightly. The subconjunctival tissue showed some large vacuoles, like dilated capillaries.

The presence of pigment granules in the fibrin lining the cavity under the conjunctiva and in the adjoining tissue, indicates a current of aqueous through the fistulous channel; the pigment cells carried from the iris tissue became entangled in the meshes of the subconjunctival tissue.

These observations show that the aim of Lagrange's operative procedure, viz., the escape of aqueous into the subconjunctival tissue can be attained.

The authors of this paper have performed sclerectomy on the eyes of rabbits 11 times. In some cases their technique has been somewhat different from that employed by Lagrange, and, in their opinion, less difficult. A conjunctival flap having been made and dissected carefully to the corneo-scleral limbus, the sclera is pierced by a cataract knife, passed obliquely about 1 mm. from the limbus, into the anterior chamber. The wound thus made is slightly enlarged and the knife quickly withdrawn and generally without loss of aqueous. The small flap of sclera thus made (on the corneal side of the incision) is excised and the conjunctiva replaced. In some instances sclerectomy without iridectomy was performed, but this procedure was not always successful in establishing a fistula.

The experiments here referred to have led Weekers and Heuvelmans to conclude, *inter alia*, that to establish a permanent fistula, it is essential to excise a portion of the sclera in its whole thickness; that the excision should be made as close to the cornea as possible, in order that there may be little or no risk of blocking of the internal opening of the channel; sclerectomy without iridectomy is likely to be followed by an inclusion of iris tissue in the scleral opening.

One of the writers mentions that in two cases of absolute glaucoma in man he essayed to perform this operation, but found the sclera and the conjunctiva so intimately adherent close to the corneal margin that it was impossible to separate

them. He thinks this condition will not infrequently interfere with the performance of Lagrange's operation in examples of glaucoma of long standing.

J. B. L.

Heinrich Freysz. **Cataract caused by Strong Electric Currents.** *Deutschmann's Beiträge zur Augenheilkunde*, Pt. 4, Dec., 1909.

In this paper the author attempts to reach some conclusions regarding the pathogenesis and development of electrical cataract by reviewing the experimental results of others, along with the clinical histories of published and unpublished cases.

Electricity, light and mechanical action are the factors which different observers have invoked to account for the development of cataract in persons exposed to the effects of powerful electric discharges. The author summarises the results of experiments done by Hess, Kiribuchi and others, to determine the part played by each of these. Then follow short accounts of six cases of electrical cataract, and one case in which the cataract, though observed after an accident with an electrical short-circuit, was believed to have been congenital.

The chief conclusions at which the author arrives are as follows:—Probably it is necessary, for the production of electrical cataract that the current should pass through the body of the injured person. The lens opacities are the result of an electrolytic change, *i.e.*, they are produced by the electric current itself, and not by the light or by mechanical shock. The opacities make their first appearance in from one to four months after the accident, and usually progress rapidly to maturity. The results of operative treatment are good.

A. J. Ballantyne.

Troncoso. **Filtration in the Living Eye and the Nature of the Canal of Schlemm.** *Annales d'Oculistique*, October, 1909.

Estimation of Filtration in the Living Eye.

In order to arrive at a just estimate of the amount of aqueous humour secreted and the exact channels of its excretion, Troncoso has devised an ingenious method by means of which the amount of aqueous secreted can be accurately measured, and the paths by which the secretion leaves the globe can be

made visible to the naked eye. Experiments made by means of his appliances go to support Troncoso's views, that Leber's estimates of the rate of filtration made with the manometer are unreliable. For the purpose of his experiments Troncoso found that rabbits' eyes were very suitable owing to the ease with which they can be luxated from the orbit.

The animal having been fixed, and the lids and neighbouring parts shaved and disinfected, the eye is dislocated forwards by means of forceps traction applied to the conjunctiva and the superior rectus. The conjunctiva is then cut all round the limbus and separated from the sclerotic as far back as the equator. The recti may be cut or not as desired, as that makes no difference in the experimental results. The eye is held in position by the closure of the lids behind it, but this may be made more secure by a stitch through the lids near the canthus. The slight hæmorrhage having been allayed the eye is plunged into a glass cup, a little larger in diameter than the eye, containing pure olive oil, and held vertically below the eye, which is so arranged that the cornea looks downwards.

The glass cup is connected below with a horizontal graduated tube—which, however, is not generally used for measuring the amount of secretion. This is clamped to a stand which holds the whole arrangement in position. The eye is immersed as far as its equator in the cup whose edge is made to fit the orbital margins accurately by means of a rubber membrane having a perforation just large enough to admit the globe. This membrane is not absolutely necessary, but it has the advantage that it more completely isolates the eye and keeps out any liquids oozing from the lids and conjunctiva, though it interferes somewhat with the view of the changes at the limbus.

A few minutes after the immersion of the eye in the oil the slight hæmorrhage from the limbic vessels becomes arrested, but continues a little time longer from the muscular vessels from which two or three big drops hang down, and after about ten minutes let fall into the oil large drops of slightly rose-tinted lymph. The aqueous also escapes in the form of very small transparent drops arranged in a circle like a string of pearls around the corneal limbus. These generally fuse and also fall into the oil, but occasionally they have to be shaken off by stroking the eye with a spatula. Both large and small drops gravitate to the bottom of the cup and form a clear or slightly rose-coloured globule. Its volume is further

increased by detaching the liquid and clots, still adherent to the eye, by stroking with a spatula or by means of forceps. The oil and the exudate are centrifugalised so that all the fine drops dispersed through the oil join the rest of the lymph, which is then measured in a graduated tube and its respective ingredients estimated. As a rule the lymph is allowed to exude for half an hour to an hour. The experiments can be repeated after the eye has been cleaned and fresh oil placed in the cup. In the repeated experiments the amount of blood and fibrinous clot is negligible.

Troncoso finds that the rate of filtration in the same eye is remarkably uniform—about 5 cubic millimetres per minute—but the rate of filtration in the eyes of different animals may vary from 3 to 8·9 cubic millimetres per minute.

As the amount of blood and fibrinous clot varied in different animals careful calculations for these factors had to be made in each case. The liquid in the graduated tube forms three layers, viz., (1) blood-clot; (2) aqueous humour and blood serum mixed; (3) very small layer of fibrinous clot. To find the amount of pure aqueous humour the quantity of serum which represents the amount of blood-clot registered is subtracted from the reading of the second layer. The relative quantity of corpuscles and serum in the rabbits' blood is determined beforehand by means of a hæmatocrite, or, more accurately, by running blood direct from a vein in the rabbit's ear into a graduated tube containing oil. When centrifugalised the relative amount of corpuscles and serum can be read off. The average amount of serum to clot is 62 : 100.

The technique of the experiments is such that the slight traumatism incurred in no way invalidates or impairs the accuracy of the results. This ocular demonstration of filtration in the living eye disposes of the doubts expressed by Weiss and Abadie, as to the existence of intraocular currents and the constant secretion and excretion of aqueous, and confirms the classical views on the subject.

The amount of aqueous excretion varies with intraocular pressure, and the secretion of the ciliary processes is dependent on the intravascular pressure. The discharge of lymph by the canal of Schlemm results from a veritable filtration through the membrane which forms its inner wall, and is due, as all filtration, principally to the pressure of the filtering liquids, which varies with intraocular pressure. The latter is the result of two factors—(1) the blood-pressure in the uveal and

retinal vessels; (2) the secretion of aqueous humour. The second is in direct relation to the first, but this relationship is not absolute, and the eye retains a certain autonomy of tension according to the quantity of liquids it contains. As the author has already pointed out (*Annales d'Oculistique*, February, 1907), intraocular tension may fall when the uveal blood supply is abnormal, as in the terminal stages of plastic or serous iridocyclitis. On the contrary, excretion and secretion are normally so well balanced that intraocular tension remains the same, notwithstanding variations of blood-pressure.

The paths of aqueous excretion include not only the canal of Schlemm, but also the anterior surface of the iris, as shown by Nisel and Benoît, but it is highly probable that the spaces of Fontana and the canal of Schlemm represent the anatomically and physiologically specialised path, and that under normal conditions the whole excretion passes this way. Assuming this to be correct, and that secretion and excretion are approximately equal, the experiments show that the average secretion in a rabbit is 5·2 cubic millimetres per minute.

By cauterising the anterior ciliary vessels the amount of lymph excreted was found to be 2·1 cubic millimetres per minute, and this may be regarded as the quantity passing through the perforating vessels at the limbus.

In one abnormal case the transudation at the limbus was practically absent, and the rate of filtration was 2·9 cubic millimetres per minute, which closely represents the quantity discharged by the anterior ciliary veins.

An examination of the blood in the anterior ciliary veins also shows that the proportion of serum to corpuscles is much higher than it is in blood taken from other parts of the body, indicating that there is a decided admixture of aqueous humour in the former.

The true nature of the Canal of Schlemm in the Living Eye. Leber and others regard the canal of Schlemm as a venous channel. Schwalbe's injection experiments led him to regard it as a lymph sinus. Histological examinations have not done much to settle the controversy. Blood is not found in it normally, and not in any quantity in any condition. These experiments of Troncoso show that the liquid which escapes through the perforating limbic vessels is practically free from blood. They also show what Thomson Henderson has shown histologically, that the number of these perforating vessels is not less than 30–40 (being so numerous that they almost touch

each other). In a state of stasis, as in glaucoma, or where the head has been in a dependent position after death, some blood may be found in the canal, but this is not a normal condition. Under normal circumstances, therefore, the canal of Schlemm contains almost pure aqueous humour.

That this canal, which has numerous communications with blood-vessels does not get filled with blood is due to several factors:—

1. The intraocular pressure is greater than that in the small intrascleral veins.

2. The aqueous humour which filters through the inner wall of the canal maintains a certain pressure in the canal which is due to the constant flow of liquid into it from the eye.

3. The anterior ciliary veins do not communicate directly with the canal, and the communications are long, narrow ($^1/_{24000}$ mm.) and often devious, so that it is more difficult for the blood to enter the canal of Schlemm than to continue in the direction of least resistance towards the anterior ciliary veins. It is only when the pressure is increased in the veins, as in glaucoma or post-mortem hypostasis, that a certain amount of blood finds its way into the lymph sinus.

J. Jameson Evans.

Contributions to Trachoma Research. Reprinted from *Naumann and Kirchner's Klinische Jahrbuch.* Jena, 1909.

This is a collection of six papers, including two by Prof. Greeff and two by workers under his direction.

In the first article, on the transferability of trachoma, Greeff reviews the experimental inoculation work which has been done on animals and men, and adds a little new material. The lower apes have proved more difficult to infect than have the anthropoid apes, but little is known of the conditions which favour infection in individual cases. Greeff thinks that the greater success which has been obtained in these inoculations in Italy, as compared with Germany, may perhaps be attributed to climatic influence. One result of the experimental work on man is the definite proof of the existence of an acute trachoma, developing the complete picture within several days. Greeff attempts to account for the supposed predisposition to trachoma, shown in certain localities, races and individuals, as explained by varying facilities for the transference of infection, provided by overcrowding, uncleanliness, habits of life, etc. Microscopical investigation supports the proposition

that it is chiefly in the earlier stages that trachoma is contagious. And in treated cases the characteristic trachoma bodies disappear very rapidly from the discharge for the time being, though they still persist in the tissues.

Drs. A. Leber and M. Hartmann present a joint paper based upon their examination of trachoma material collected by the former at Trieste, under commission by the Prussian Ministry. The material was from 56 cases of the disease, principally early cases, mostly in children and mostly untreated. The characteristic trachoma bodies were found even in the later stages of the affection, in cases where the whole conjunctiva had not undergone cicatricial changes. The special feature of the smear preparations was that they were fixed while still moist, either in sublimate alcohol or in Hermann's solution (platinum chloride, osmic acid, acetic acid). They were mostly stained with Heidenhain's iron-hæmatoxylin, later with Rosenbusch's modification of it. The fixation before drying gave a clearer picture than would otherwise have been obtainable.

Their preparations appear to show that the plastin mass in the epithelial cell, the first sign of the invasion of the cell, comes from the nucleus and contains chromatin. Rightly looked upon by Halberstädter and v. Prowazek as a reaction product, it is also a degeneration product. Single and double trachoma granules (parasites) can be seen frequently within the nucleus. Possibly this location of the organisms may account for the outflow of the plastin body from the nucleus. The granules vary considerably in size, some being so minute as to be barely visible with the highest powers (No. 18 Ocular). They frequently observed two granules connected by a thread in dumb-bell form. Such a mode of division supports Halberstädter and v. Prowazek's classification of the granules with protozoa, in opposition to Greeff's and others' acceptance of them as bacteria. This dumb-bell figure is a well-known one in the division of the nuclei of many small amœbæ and flagellates. A drawing is given from a preparation by Dr. Nägler showing an amœba containing numerous parasitic protozoa, quite similar in appearance to the trachoma bodies.

Dr. di Santo has succeeded in demonstrating the trachoma bodies in sections of affected conjunctiva. The tissues were fixed in absolute alcohol and embedded in paraffin. The sections were stained in Giemsa for 4–6 hours at 37°, washed in water, decolorised in alcohol or in acid-alcohol (HCl 1 per cent.), dried in the air, and covered with cedar oil. He has not found

the subepithelial trachoma granules situated especially within the follicles. Very many of them are seen in the connective-tissue spaces, immediately beneath the membrana limitans, with perhaps a predilection for the immediate neighbourhood of follicles. Grouped often in small heaps and in pairs, less frequently in short chains, they often lie in a clear space or capsule, either in the connective tissue cells or free. Here and there a space may be packed with the granules. The more deeply-situated bodies are always in close relationship with follicles.

Dr. W. Clausen discusses the diagnostic value of the trachoma bodies. Prof. Greeff follows with an enquiry into the introduction of trachoma into the Arnsberg district, and Dr. R. Buchwald, with a report upon the spread of the disease in the province of Posen. H. Herbert.

O. Landman (Toledo, Ohio). **Conjunctivitis and Purulent Inflammation of the Excretory Ducts of Meibomian Glands caused by an Encapsuled Gram-Negative Diplobacillus.** *Knapp's Archives of Ophthalmology*, July, 1909.

This report deals with a single case. The conjunctivitis was chronic, leading in the course of six months to some thickening of the palpebral mucous membrane. The discharge was muco-purulent and pustules formed at the mouths of the Meibomian glands. The case resisted ordinary treatment, but gave way finally to the use of a solution of acetozone, 1 in 2000. This treatment was suggested by the observation that the growth of the causative organism was "much interfered with" in acid bouillon.

The same diplo-bacillus was obtained in pure culture from the discharge at the beginning of the attack, and again six months later. It was a fairly thick, large bacillus with rounded ends, in the original smears averaging about 3 μ in length and nearly 1 μ in breadth, and presenting a definite capsule. The capsule, as wide as the body itself, was formed also in culture on certain media at low temperatures. There were some shorter forms, and threads of 4 to 6 cells were met with. Involution forms showing slightly enlarged ends were found in all cultures after forty-eight hours. The bacillus was found to be a facultative anaërobe, non-motile and non-sporing. It grew rapidly on common media at ordinary temperatures, and slowly at 10°C. in an ice-box; it did not liquefy gelatine.

Landman suggests that this new organism may have been seen by other observers in smear preparations from cases of conjunctivitis, and mistaken either for the Morax-Axenfeld diplo-bacillus or for Friedlander's pneumo-bacillus. From the former it is distinguished in secretion by the possession of a distinct capsule, and in culture by its ready growth on all media. Also it is pathogenic to mice and rats. Curiously Landman omits to state whether it liquefies ordinary blood-serum or not. It may be distinguished from the Petit diplo-bacillus by its inability to liquefy gelatine, among other characters. Friedlander's bacillus is smaller and does not occur so regularly in pairs. It is distinguishable finally by agglutination tests.

This new bacillus, by its relationship with the Morax-Axenfeld bacillus, serves to illustrate the fact that none of the common conjunctival organisms stand alone. Each is a member of a group of allied organisms, continued investigation tending constantly but slowly towards further subdivision.

H. Herbert.

Levinsohn. **Experimental Researches on the Relationship of the Anterior Corpora Quadrigemina to the Pupillary Reflex.** *v. Graefe's Archiv. fur Ophthalmologie,* 72, 2.

The afferent pupillo-constrictor path is one that has long been a field for experiment, and the question cannot yet be regarded as settled. The view that the fibres pass through the superior brachium to the anterior corpora quadrigemina and there make connections with the third nerve nucleus of both sides affords a satisfactory explanation of the facts of the consensual and hemiopic pupil reactions. The histological work of Held also lends some support to this theory. The fact that the removal of the anterior corpora quadrigemina by earlier experimenters was not necessarily followed by any interference with the pupil reflex could be explained by assuming that the pupil fibres form their new connections in the lateral part of the colliculus and so may have escaped destruction.

The author, after pointing out that no value can be attached to any of these experiments in which there has not been made a microscopical investigation of the exact limits of the lesion, states that though in a previous paper, after numerous accurate experiments on rabbits, he had been able to assert confidently that until the lesion had reached the level of the base line of the

aqueduct, there was no interference with the pupillary reflex; in view of the wide-spread belief in the connection of the colliculus with the pupil reflex he decided to repeat his experiments on an animal in which the mid-brain more nearly resembled that of man. For this purpose he experimented with three monkeys (Macacus Rhesus), making use of the same method as before in the technique of exposure and destruction of the colliculus. To judge from the photographs which accompany the paper, the method certainly does not err on the side of incompleteness. In the first monkey, after removal of the left colliculus, the left pupil was noted to be smaller and rather less active to light than the right. Five days later the pupillary reactions and size were completely restored to the normal. In the second monkey, both pupils were rather contracted but both reacted promptly to light. At the post-mortem examination on this animal which died on the following day, it was found that the part of the colliculus lying next the aqueduct was intact. In the third monkey immediately after the operation the pupil on the operated side was rather larger than its fellow and its reaction to light not so brisk. These differences had disappeared by the fourth day. In this animal examination showed that the colliculus had been removed down to the level of the aqueduct. The author explains the temporary alteration of the pupils on the assumption that the lesion is in the neighbourhood of the centrifugal pupil fibres, and produces either contraction or dilatation of the pupil as a result of stimulation or injury of these fibres. He sums up the result of his experiments as showing that we are unable at present to trace the afferent pupil fibres further than the external corpus geniculatum, and that in any case the anterior corpus quadrigeminum down to the level of the aqueduct has no connection therewith. It is to be regretted that Levinsohn has made no attempt to trace the degenerations that follow this lesion. Sir Victor Horsley with Clarke's stereotaxic instrument made some strictly localised lesions of the corpora quadrigemina, with only the most transitory effects on the pupil. In these experiments, however, there was no attempt at destroying the whole of an anterior colliculus, it being intended to trace the degenerations arising from a localised lesion. This work is not yet complete; but it is only by experimenting in this more delicate and exact way, that any real light will be thrown on the nature and functions of the anterior corpora quadrigemina in the higher animals.

E. E. H.

F. Schieck. **The Ætiology of Retrobulbar Neuritis.** *v. Graefe's Archiv.*, 71, 3.

The author in this paper reviews the German literature on the subject and gives his own experience at Göttingen in the endeavour to find an answer to the question of the identity of the two forms of retrobulbar neuritis, namely, that due to general disease of the nervous system, disseminated sclerosis and myelitis, and the affection secondary to disease of the nasal sinuses. He fails to find any clinical points of difference.

He has collected 33 cases, of which only four were due to disseminated sclerosis. He points out that the number of cases is too few to base any reliable opinion as to the ætiology of the disease, especially as the other observers referred to have found the number of disseminated sclerosis cases far more numerous.

One case occurred in connection with myelitis. The optic nerves and posterior halves of the eyes were obtained for microscopic examination, the results of which are detailed at considerable length, but do not appear to shew anything more than in previously recorded cases. The microphotographs which illustrate the paper are very indifferent.

In dealing with the cases secondary to nasal infection, the author states that in some of his cases the nasal affection was not of a severe nature, and that very rapid improvement followed simple treatment. E. E. H.

Georg Hirsch. **Case Index for Ophthalmic Surgeons arranged in Diagnostic Order.** Published by William Engelmann, Leipzig.

This index is intended to assist in the ready finding of cases illustrating any particular point in ophthalmology without the usual wearisome hunt through individual case book indices. It contains 192 pages, which are divided proportionately between the various ocular affections, these latter being separated as in the usual "where is it" type of note-book. The first column contains space for the number of case book and year, and following this is a column intended for any additional remarks. The names of the various affections are in Latin. The book seems a most useful one, and should prove of much assistance in the use of a good deal of clinical material, which is at present allowed to remain buried in the case books for want of a ready means of reference. It would be advantageous to make the second column a little wider.

CLINICAL AND THERAPEUTIC NOTES.

Metastatic Gonorrhœal Conjunctivitis.—There are three theories in regard to the origin of this infrequent manifestation of gonorrhœal affection of the eyes, viz.: that it is due to gonotoxin, to the toxin to which the organism gives rise and not to the organism itself; that the original infection is a mixed one and that the conjunctivitis is caused by one of the organisms other than the gonococcus; and that it is a true metastatic infection, the gonococcus being carried by blood-vessels or otherwise from urethra to conjunctiva. McKee (Montreal) believes that he has been able to settle the matter and prove the metastatic theory to be true by finding the organism in the conjunctival secretion. The case which afforded him his material was in most respects a typical one—the recent gonorrhœa, the sudden onset in both eyes at once of a muco-purulent conjunctivitis, the absence of any serious involvement of the cornea, the marked tendency to recurrence, the simultaneous development of joint involvement—all were recorded in this instance. The chief point lies in the success—all the more noteworthy because numerous good observers have failed—of the endeavour to determine the presence of gonococci in the conjunctival secretion. This was attended with great difficulty and necessitated enormous patience on the part of the observer. For example, at the first visit of the patient, McKee made and exhaustively examined eighteen slides unsuccessfully before he found one in which there were at one part a very few organisms resembling gonococci lying in leucocytes. Growth on hæmoglobin again (after failure with other media) showed a development after some time which consisted almost entirely of xerosis bacillus, but in it were a few small areas of different aspect from which the desired organism was obtained and gradually isolated in pure culture. This was by several tests distinguished from micrococcus catarrhalis (nose), from meningococcus, a urethral micrococcus, and saprophytic gram negative diplococcus. The observer failed to discover any organisms in a morsel of tissue cut from the conjunctiva during the stage of inflammation.—(*Ophthalmology*, July, 1909.)

Alypin as a Cycloplegic.—Scott-Moncrieff gives the results of his experience in the use of alypin as an anæsthetic in ophthalmic work. He finds, with Darier, that its weak action on the conjunctiva and iris prevent its being used as a routine anæsthetic for cataract extraction, and that it does *not* render subconjunctival injections painless. For corneal operations,

however, such as cauterisation, removal of foreign bodies, etc., it is very useful, as its effect is fully equal to that of cocain, its action is more rapid, and it does not cause exfoliation of the corneal epithelium.

Hypodermically, this drug acts more quickly than cocain, and it is less toxic. In a series of experiments on himself and his hospital assistant, Moncrieff finds that alypin used locally produces slight mydriasis and partial paralysis of accommodation, but that if exhibited by the mouth or by hypodermic injection it is a powerful cycloplegic. The paralysis of accommodation is complete, it comes on in a very short time, and passes off quickly, and the mydriasis produced is only very slight. These results lead Moncrieff to think that the drug may prove to be very valuable in the diagnosis of errors of refraction. Experiments performed at Cambridge (*B.M.J.*, 27 March, 1909) seem to show that alypin is more toxic than cocaine, but in Moncrieff's experience this is entirely at variance with clinical observation.—(*Indian Medical Gazette*, July, 1909.)

Fat Transplantation in Adherent Cicatrices of the Orbital Margin.—Verderame (Siena), after a passing reference to the transplantation of bone and periosteum, deals at greater length with the use of injections of paraffin for the removal of the unsightly appearance due to the presence of adherent cicatrices at the orbital margin, pointing out that this procedure cannot be considered free from danger since there are on record cases in which pulmonary embolism, thrombosis of the ophthalmic vein, embolism of the central retinal artery, extravasation of paraffin into the eyelids, necrosis of the skin and other more or less serious accidents have resulted.

For the cases in question he advises us to fall back on the procedure recommended at an earlier period by Silex and Axenfeld, namely, the subcutaneous transplantation of fat at the site of the cicatrix.

A small incision is made through the healthy skin in the neighbourhood of the cicatrix, after which, with the help of scissors, the attachments of the skin to the underlying bone are freely separated so as to allow the skin to be easily raised to its former level. A mass of adipose tissue of appropriate size is then taken from the subcutaneous tissue of the abdomen and inserted in the cavity and the wound carefully stitched.

Immediately after the operation there is some redness of the undermined skin, and a prominence in place of the original depression, but the parts gradually assume a more natural appearance and the cosmetic result is a good one.—(*Klin. Monatsbl. f. Augenhk.*, October, 1909.)

Berlin Ophthalmological Society.

Reported by Dr. Curt Adam.

November 25, 1909.

Affections of the Optic Nerve in Tumours of the Orbital Wall. Köllner showed preparations from three cases in which a malignant growth of the orbital wall had implicated the optic nerve. The first was a case of sarcoma of the middle fossa, reaching from the orbit to the petrous portion. Clinically the patient had complained of blindness for a period of seven weeks, though except for a slight congestion of the veins of the nerve-head there was no objective sign. Post mortem, the tumour was found to have compressed the nerve very severely, and to have almost completely destroyed the bone at the foramen opticum. The tumour was entirely extra-dural. The second case was an example of carcinoma starting from the sphenoid, but involving the whole bony base of the skull. There had been almost complete amaurosis, but with a normal fundus. The carcinoma was found to have destroyed both bones and dural sheath at the foramen, and to have made its way among the nerve bundles along the pial trabeculæ. The right cavernous sinus was filled up with tumour growth. The third case was one of sarcoma of the frontal bone, encroaching upon the left orbit. Vision had not been interfered with, nor were the muscles involved, but there was moderate choked disc. The sarcoma had not involved the foramen; but as it encroached upon the orbit had pushed aside the optic nerve into the cellular tissue; the nerve itself showed no anatomical changes.

A Note on the Lymph Currents of the Eye. Hamburger considered that Leber's opinion that the ciliary body was alone concerned in the physiological secretion of the aqueous humour was an error; even if the tension should continue normal when the iris was removed that was no proof, for we know that when one organ is removed another may vicariously take up its function, as, for example, after removal of a kidney, and Leber's experiment, in which, after removal of both iris and ciliary body, secretion of aqueous ceased, is not proof as regards either alone. After removal of the contents of the anterior chamber "ciliary secretion," which replaces the aqueous, is not the same as the normal contents, inasmuch as it contains fibrin, albumin and other bodies which are absent from normal

aqueous or are present only in the minutest quantity. Hamburger finds support for his view that the iris secretes the aqueous in the fact that if fluorescin be injected into the posterior chamber the pupil remains black; in other words, the fluid from the ciliary body is "excluded" physiologically from the pupil, unless the normal condition of affairs be disturbed by paracentesis of the anterior chamber, when the fresh "aqueous" becomes tinted. He also regards the iris vessels, and not Schlemm's canal, as the principal means of removal of the fluids from the eye; experiments in the rabbit with injection of a solution or suspension of indigo injected into the anterior chamber proved that the coloured particles were massed about and in the vessels of the iris, and not about Schlemm's canal.

Meeting of December 16, 1909.

Active Immunisation of the Cornea. Leber exhibited a rabbit in which he had succedeed in producing this by means of subconjunctival injection of a polyvalent serum.

Posterior Vortex Veins. Langenhan showed a boy, aged 9, in whose fundus, which was very feebly pigmented, numerous extraordinarily well-developed Posterior Vortex Veins could be seen; these were situated close to the disc. These have rarely been seen save in highly myopic eyes, but his patient was almost emmetropic.

Cilia in the Anterior Chamber. Paderstein showed a case: cilia do not in all cases give rise to serious reaction, but they sometimes, if mobile, set up "pearl" nodules in the iris, when it is uncertain whether it is the eyelash itself which is the cause, or the particles of epithelium removed which initiate the new formation. In discussion, Hirschberg recommended removal of the cilia, and Gutmann spoke well of the blunt hook for this purpose; von Michel agreed that cilia may be well tolerated in some cases.

The Action of Dionin on the Eye. Adam read a paper on this subject. The drug has been employed for nearly every possible disease of the eye. But it is distinctly harmful after recent injury or operation; its chief actions are as an analgesic and an absorbent. In the former capacity it is of service in painful diseases of the anterior portion of the eye, particularly in superficial losses of substance and in scleritis and episcleritis.

Though it may be used in iritis, this should be done with care in presence of arterio-sclerosis, as it may cause hæmorrhages when vessel changes exist. When used in glaucoma it may even dilate the pupil somewhat, but does not for all that appear to have any injurious influence upon the tension. As an analgesic it is unreliable, fails in one case out of every four, becomes tolerated very rapidly, smarts a good deal, and produces chemosis. His opinion of dionin as an absorbent is very low, unless of subconjunctival hæmorrhages. He employed it in a long series of cases of nebula of cornea and found little benefit to be got which could not equally well be obtained by other means.

Pigmentation of the Scleral Conjunctiva. Köllner showed a drawing of the left eye of a woman of 50 with extensive pigmentation. About three-quarters of the cornea could be made out with a lens to be invaded by a fine network of minute brown pigment dots lying quite superficially in the epithelium. Microscopic examination of a piece of excised conjunctiva showed that in it also the pigment granules were quite superficial in the epithelium, lying even in the old cells. The pigment sometimes filled the whole cell; it gave no iron-reaction. So far as regards the cornea the case is believed to be unique. In discussion Gutmann mentioned the case of a girl of 20, who presented a somewhat similar patch of pigment on the scleral conjunctiva, which looked exactly like a pigmented nævus, and had recently increased in size. He removed a piece, however, and, as in Köllner's case, there were no nævus-cells, and the pigment not in masses, but, as in this instance also, in the epithelium: it lay, however, in the deeper layers of it, disposed indeed much as the pigment normally lies in the tissue of the negro.

Tumour of the Conjunctiva. Napp showed preparations from a tumour which had been situated at the limbus, had existed for four years, and latterly had been growing slowly; it had a transparent aspect. Microscopically, it consisted of large polygonal cells in lax arrangement, with fine gaps between them in places. In among these lay a somewhat closer tissue of similar character; Napp regarded the case as one of alveolar sarcoma which had become œdematous.

Chondrosarcoma of the Lachrymal Gland. Napp also showed preparations; he had removed the tumour through the conjunctiva.

CONGENITAL TOTAL COLOUR BLINDNESS WITH DAY BLINDNESS.

By F. A. Juler, M.A., M.B., B.C., F.R.C.S.

Three patients, occurring in one sibship were brought to the Royal London Ophthalmic Hospital in August, 1909, on account of defective sight.

I. Charles H——, aged 8.

The mother states that the patient has always screwed up his eyes in bright light and that the eyes have always been shaky, but that these signs are not so marked as formerly.

P.C.—Irides, dark brown.

Pupils are sluggish, but react to light, dilating slowly in the dark.

Cornea and conjunctiva quite healthy.

Media clear.

Fundi.—The discs are of good colour and the vessels of normal calibre: a fine stippling is present about the macula, but this is not more than would be termed physiological: choroidal vessels are visible in the periphery.

Visual acuity.—Under atropine, V.R. with $+4S = {}^{6}/_{60}$, V.L. with $+2{\cdot}5S$, cyl. $+1{\cdot}5$ a.v. $= {}^{6}/_{60}$. In the darkened room and with decreased illumination patient could not read smaller type, but appeared more comfortable than in the light.

Colour Vision.—Total colour-blindness, the colours being grouped according to their light components. With Holmgren's wools I satisfied myself of the complete colour-blindness by telling him to pick out red, green, etc., in the usual way, and I then laid out the

various shades of grey and made the patient match these, with the following results:—

With white he placed light pink.

With very light grey he placed light yellow and light blue.

With light grey he placed light green.

With darker grey he placed blue.

With darker grey still he placed yellow and green.

With darker grey still he placed dark blue.

With darker grey still he placed dark orange and dark green.

With darker grey still he placed red.

With black he placed dark red.

On looking through a small spectroscope he said he saw "white in the middle with red on each side."

He and his brother knew they were colour-blind, and always asked the next boy at school which paint they had to use.

Photophobia.—Patient screws up his eyes if told to look at a bright light: left to himself, on a dull day the eyelids are at times well open, at others half closed: attempts at fixation only increase this closure of the lids slightly: in the darkened room the lids are kept well open.

Nystagmus.—This is intermittent, and when present occurs in both eyes, or in one only: it is oblique, and the excursions are small, in frequency about 300 to the minute: neither attempts at fixation nor increase of illumination start or increase the nystagmus: it is not more marked in any special direction of regard.

Visual fields.—There appeared some narrowing of the periphery, but the nystagmus and the youth of the patient prohibit any reliance on this: a central scotoma could not be demonstrated.

II. Samuel H——, aged $5\frac{1}{2}$.

Irides, grey shading to light brown at the pupillary margin.

Pupils react, but dilate very slowly when shaded.

Cornea and conjunctiva healthy.

Media clear and fundi normal.

Vision ? $^{6}/_{60}$. Refraction S − 1, cyl. − 2·5a.h.

Colour-blindness—as in Case I. In the spectroscope he declares he sees "white in the middle, green at each end."

Photophobia—similar to Case I., but slightly more marked.

Nystagmus—rotatory, both eyes moving together and in the same direction. The excursions are slightly wider than in I., but not quite so frequent, varying from 200–250 to the minute. Otherwise nystagmus is as in Case I.

III. Annie H——, aged 3.

Irides—dark brown.

Photophobia—more marked than in I. and II.

Nystagmus—intermittent, slower and slightly grosser than in I. and II.

Refraction—H = 2·5 D.

Colour vision test, not satisfactory.

Fundi normal and media clear.

Family.—The three patients are consecutive children in a sibship of seven. The unaffected four have healthy



eyes, and are sound in body and mind. The three

patients seem healthy and appear to possess average intelligence. There is no history of consanguinity in the parents: both parents come from large families, and there is no clue that any relatives are similarly affected, nor that there is any partial colour-blindness in the family. The mother and an aunt were found to have good colour-vision.

The mother, when eight months pregnant with Case I. was knocked down in a cycle accident and rendered unconscious for a few minutes.

Remarks.—The above cases have been deemed worthy of record, as very few have been published in English literature, and it is possible that similar cases have been to some extent overlooked.

In 1903 Grunert[1] published a paper with abstracts of forty-seven previously recorded cases and a full account of five new ones, in which he has studied the syndrome of symptoms in detail and explained each on the theory of absence or imperfection of the retinal cones.

Mr. Nettleship published the earliest English cases,[2] and referred shortly to the condition in his Bowman lecture last year,[3] when he stated that he had found records of thirty-two further cases besides those mentioned by Grunert. No light is thrown by the present cases on any hereditary taint, but the occurrence of several cases in one sibship appears to be fairly frequent.

No microscopical examination has yet been made, but, taking Grunert's theory of cone-blindness, the symptoms can be explained as follows:—The amblyopia is accounted for by the absence of cones, which are normally resident at and near the macula, causing a complete or relative central scotoma: it may be found that in some cases rods supplant the cones in this region.

The total colour-blindness is also explained by the absence of retinal cones. It is now well recognised that the cones possess the fine-form and colour-senses. The colour-blind rods permit only a small acuity of vision in a bright light from bleaching of the visual purple: in the dusk the accumulation of visual purple increases the capabilities of the rods, and thus the visual purple is the special apparatus for vision in the dark. There is, I believe, only one case[4] recorded of total congenital colour-blindness with normal visual acuity, but here yellow appeared the darkest colour and there was no photophobia.

The photophobia may be looked upon as an attempt to diminish the light intensity by narrowing the palpebral aperture so as to allow the rods to obtain their maximum perceptibility. These cases appear to be in a condition of more or less constant dark adaptation to avoid bleaching of the visual purple, which is possibly more active than normal. Grunert and others have demonstrated in their cases that the time necessary for dark adaptation is very short (a few seconds) and the light sense normal. In the cases now recorded the youth of the patient rendered attempts at investigating these finer points futile.

Day-blindness. With regard to the effect of illumination on the visual acuity, it has been shown in some cases (Uhthoff and others) that the best vision can be obtained with moderate illumination (12 C.P.). On increasing the light the vision of the achromatic eye decreased, that of the normal eye improved, whilst by decreasing it, both the achromatic and the normal vision diminished. The expression day-blindness is thus to some extent correct, but it refers more truly to the

discomfort which is experienced by these patients in a bright light; some say they are quite dazzled by a white central cloud on looking at a bright object.

The nystagmus is not always a marked feature: in my cases it is intermittent and in some cases, especially in elderly persons, it has been completely absent: it possibly decreases with age. It may be considered as partly due to the central scotoma and partly a phenomenon for relieving successive retinal points from the strain of fixation. Grunert describes two types of nystagmus which are sometimes present together; the first is comparatively slow and large, the excursions being inconstant in frequency and extent, and varying without obvious cause, such as change of illumination, attention of the patient, etc.; when the patient fixes hard the second type commences as a shorter and quicker nystagmus, quite regular in its excursions. In Grunert's five cases this double type occurred twice, the other three had the fine type only, quickened by the act of fixation. In my cases the nystagmus was not affected by fixation and showed only one type.

The visual field in most cases shows no peripheral contraction: out of eighteen cases examined for central scotoma eight gave a positive result; in some cases a very protracted examination is necessary, and it is often impossible to be sure of a negative result on account of the nystagmus. Grunert recommends fixation by a ring as the most suitable apparatus. It seems impossible that there cannot be an absolute or relative central scotoma in every case, for the limits of the field are normal, the peripheral acuity is not diminished, but the central vision is only $^1/_5$ to $^1/_{10}$ the normal. A ring scotoma has been found in a few cases.

It is through the kindness of the late Mr. W. Ilbert Hancock that I am able to publish these cases.

REFERENCES.

1. Grunert. *Archiv. f. Ophthal.*, Bd. xvi, 1903, S. 132; abstracted in *Ophthal. Review*, 1903.

2. Nettleship. *St. Thomas's Hospital Reports*, 1880, Vol. x, p. 37.

3. Nettleship. *Trans. Ophthal. Soc.*, Vol. xxix, p. cxxviii.

4. Raehlmann. *Woch. f. Therap. in Hygiene des Anges*, 1899, Bd. ii, S. 165.

REVIEWS

W. E. Burge. **The Analyses of the Ash of the Normal and the Cataractous Lens.** *Archives of Ophthalmology*, Sep., 1909.

This paper is very interesting, but it does not lend itself readily to abstraction. The greater part of it is a technical description of the various means of chemically analysing the Ash. Carefully drawn up tables of the results of analyses of the normal human, the pig's, and the cataractous lenses are submitted. Unfortunately, while it was possible to obtain a large supply of human cataractous lenses, great difficulty was experienced in obtaining normal human lenses. The pig's lens was found to be almost identical in the percentage of the ash with the normal human, and most of the comparisons are drawn from this and the human cataractous. The more important conclusions may be summarised as follows:—

(1) In senile cataract the percentage of potassium is greatly reduced, while calcium and sodium are increased, thereby bringing the lens nearer to the composition of the blood and the lymph.

(2) The normal lens in very old age compared with the embryo does not show any percentage diminution of potassium. From this the author argues that senile cataract is not premature senility of the lens, *i.e.*, the acceleration of the normal senile change; but is due to some cause which has interrupted the normal metabolism, and brought on a moribund condition of the tissue.

(3) This is perhaps confirmed by the curious fact that the cataractous lenses obtained from India contained a large

amount of calcium potassium and sodium *silicate*, while those from the United States were without *silicates*. Is there something in the diet of the East Indians to account for this curious condition?

P. C. Bardsley.

Martin H. Fischer. **On Swelling of the Eye and the Nature of Glaucoma.** *Pflüger's Archiv. für Physiologie.* Vol. 127, 1909.

In these very suggestive experiments the author deserts the well beaten track of connections between blood pressure, or lymph pressure, with all their bearing on the nature and amount of the intraocular fluid, and intraocular pressure.

In previous papers he has shewn that the presence of very small quantities of acids or alkalies produces a very great effect on the absorption of water by colloids such as fibrin. Not only is this the case but the absorption is also dependent on the condition of the colloid with regard to the presence of crystalloids. These latter can for this purpose be divided into two main groups, *i.e.*, electrolytes and non-electrolytes. The former producing a very considerable effect, the latter only a very slight one. If the artery and vein of a frog's limb are ligatured so as to entirely occlude the circulation, and the animal then placed in the water, the limb so treated will swell. Any theory of osmotic pressure fails to explain this result, which is however easily explained by the fact that minute traces of lactic acid produced in the limb and no longer removed by the circulation, immensely increase the affinity of the colloid for water, which is then absorbed directly through the skin.

In a series of experiments on freshly excised ox, pig and sheep eyes, Fischer has found that the conditions influencing the absorption of water by fibrin similarly effect that organ. These conditions he recapitulates as follows:—

(1) Fibrin swells more in acid or alkaline solutions than in plain water, but the swelling varies with the nature of the acid or alkali when used in the same molecular concentration.

(2) The presence of certain salts in the acid or alkaline solution lessens the tendency to swell. This also varies with the nature of the salt, provided the molecular concentration is the same.

(3) The water absorption by fibrin is for the most part a reversible process, but in general not completely so in the time allowed for the duration of these experiments.

(4) Non-electrolytes do not share with electrolytes the property of decreasing the water absorption in acid or alkaline solutions.

The amount of swelling was measured by weighing the eyes at definite intervals after drying them with filter paper. As soon as an eye had increased in weight by 30 per cent. it burst, the seat of rupture being practically always in the sclerotic, some way behind the limbus. The amount of acid present need be extremely small, in fact not to be detected by taste, and yet bring about a very great increase in the rate of absorption. The strength employed for comparing the powers of the various acids was 20 ccm. of a decinormal solution added to 200 ccm. of water. The greater the concentration of the same acid the greater was the effect produced, but owing to the rapid absorption causing the eye to burst it was not found practical to use solutions more concentrated than $^1/_{110}$ normal.

Similar results were obtained with alkaline solutions, but it was found that these were much less active than acid solutions of the same degree of molecular concentration.

In experimenting on the action of electrolytes in hindering this absorption, the author first used salts possessing the same anion but a different kation, and found that their order of activity, beginning with the least active, was as follows: lithium, ammonium, potassium, sodium, barium, strontium, magnesium, calcium, copper (ic salts), iron (ic salts).

In the same way using sodium as the kation and different anions he gives the following list, beginning with the least active: chloride, bromide, nitrate, acetate, phosphate, sulphate, tartrate. These results are all shewn graphically by means of curves in the accompanying diagrams.

Not only is the amount which can be absorbed under these conditions enormous, but also the rapidity with which the absorption takes place is extraordinary. As far as the author's observations have gone, all parts of the eye seem to take an equal share in the absorptive process.

The author states that in his opinion the condition of glaucoma is not due to excess of fluid poured into the eye under raised blood or lymph pressure, but to a change in the condition of the colloid material tending to increase its power of water absorption. He found that by injecting subconjunctivally in a case of absolute glaucoma a solution of between 4 and 5 per cent. of chemically pure sodium citrate, the intraocular tension was reduced to below normal in ten minutes. The previous tension and the amount injected is not stated. The

effect lasted for from three days to a week. Other salts were also tried, but the results with the sodium citrate were the best. The author does not suggest that the treatment of glaucoma by these salts, which he terms "abführmittel," can be in any way described as a cure. A real cure can only be obtained by removal of the cause which makes the colloid absorb fluid. While this theory is in no way applicable to all cases of glaucoma, it does seem to afford a possible explanation of those cases of glaucoma which follow interference with the intra-ocular circulation, as we may in these cases be regarded as having a condition somewhat similar to the ligatured frog's leg, in which the increased water absorption is brought about by the failure of the process of removal of the waste products.

E. E. H.

Martin H. Fischer. **On Corneal Opacities.** *Pflüger's Archiv. für Physiologie.* Vol. 127, 1909.

In the course of the experiments on glaucoma described in the preceeding review, Fischer was struck by the varying degree and varying rate of production of opacity of the cornea during the process of water absorption. He found that the transparency of the cornea was but little affected either by drying or by absorption of distilled water, but that the addition of acid or alkali produced an immense effect. The order of activity which the various acids displayed in bringing this about in no way corresponded with their power as regards the facilitation of water absorption. Further the non-electrolytes, glycerine, urea, or dextrose were effective in preventing the development of opacity of the cornea, while the electrolytes, which, it will be remembered, prevented the absorption of water, were found to assist the process of rendering the cornea opaque. The author suggests that this action must be due to destruction of some important part of the corneal proteid, and that some explanation of this nature underlies those opacities not only of the cornea but also of the lens which accompany such disturbances of metabolism as are found in diabetes. E. E. H.

Sweet (Philadelphia). **Third Series of Cases of Injuries from Foreign Bodies Examined by the Roentgen Rays with Results of Operation.** *Ophthalmic Record,* October, 1909.

There have been at least three papers, published recently, classifying and reporting considerable numbers of cases of foreign body within the eyeball in which the electro magnet has been used in their removal.

Dr. Sweet of Philadephia has published the most recent, and his paper deals with no less than 157 cases, and, what is more important, there has been a uniformity of treatment, since in all cases the hand magnet has been used. This means that when a chip of steel has come to rest in the vitreous, it has been removed by way of a scleral incision.

It was hoped that this fact would have been of value in deciding the point that has so often been raised as to whether such chips should be removed by way of the cornea using the Haab magnet for the purpose of dragging the steel into the anterior chamber, or by way of a scleral incision using the hand magnet as the attracting force.

Dr. Sweet raises this point and refers to Wharton's paper in the "Ophthalmoscope" for May, 1909, and Goulden's paper in the "Royal London Ophthalmic Hospital Reports for 1908." Unfortunately, owing to lack of detail, this comparison cannot be completely made, as in the paper under review cases are classified according to whether the foreign body was "anterior to," or "in the vitreous," disregarding the state of the lens which is of such great importance, as it has been shewn in Goulden's paper that a case in which a particle is embedded in the lens gives a far more serious prognosis than one in which a foreign body has gained the vitreous by way of the cornea or corneo-scleral margin, the lens remaining intact. Hence in settling the question this paper is not so valuable as it might have been. However, so far as a comparison is possible in the circumstances the cases published in the Royal London Ophthalmic Hospital Reports, where the Haab magnet was used to draw the foreign body into the anterior chamber and thence remove it, give much better results so far as final vision is concerned.

In the classification of cases on page 453 of his paper Dr. Sweet has made a slip in quoting the number of cases in Goulden's paper. In the latter the cases in which the chip was in the vitreous number 16, of which 10 gave $^{6}/_{12}$ of vision or more and 6 less than $^{6}/_{12}$ (not 8 and 9 respectively as quoted), whereas of Dr. Sweet's 86 cases only 24 gave $^{6}/_{12}$ of vision.

Of cases in which a foreign body was anterior to the vitreous the comparison of various methods of removal is not so important and the results are fairly uniform, although it seems to us that the preliminary use of the giant magnet renders future manipulation with the small magnet much simpler and less likely to injure the lens. These cases give a very favourable prognosis if the lens be uninjured, and if care be taken to

avoid an iridectomy by using an incision in the cornea above, and not at the limbus, then at least $^{6}/_{12}$ of vision should result.

When punctures are made through the sclerotic and uveal coats of the eye it is always possible to see the injury to the retina subsequently if it be within view of the ophthalmoscope. Such result is not necessarily detachment, but may be a proliferative retinitis or the formation of a membrane in the vitreous. Such results are to be expected, since it has been shown experimentally that if a perfectly aseptic Graefe knife be driven through the vascular coats of the eye there will be found, on pathological examination, fibroblasts and an exudate giving rise to fibrous tissue along the track the knife has taken in the vitreous; similar conditions are found when a wound of the sclerotic and retina has been caused by the entrance of a foreign body, and the eye has been subsequently removed. Again, it seems logical to argue that when a foreign body has gained the vitreous by way of the cornea and lens, or by the corneo-scleral junction with the lens intact, much less damage will follow should the particle be removed approximately by the path by which it gained entrance than by complicating the case with a fresh incision and that, in such a position as is shewn by pathological investigation to be full of danger.

Dr. Sweet shows how very valuable the X-rays may be in treating cases of intraocular foreign body, a field in which he has done such admirable pioneer work, especially when the fragment has come to lie broadside on to the aperture through which it is desired to remove it. He also refers to the difficulty of deciding whether a particle is just within or just without the globe, when it is very far back. Eyes vary in length, and the usually adopted number is 24 mm. from the centre of the cornea to the posterior pole of the eye. If, for instance, measurements give 23 mm. or 25 mm. in localisation, we may be in doubt. An excellent procedure is, after fixing the head, to make the patient fix a mark high up on the wall and expose the plate, and then make him look at a point far down the wall and expose again, when, should two separate shadows be shown on the plate, we have evidence that the foreign body is at least embedded in the coats of the eye if not within the globe.

C. B. Goulden.

Charles McNeill. **A Study of the Tuberculin Reactions in Skin and Eye.** *B.M.J.*, November 6, 1909.

The author gives an account of 153 consecutive cases. In all the skin reaction test (v. Pirquet) was performed, and in 78 of

these the conjunctival test (Wolff-Eisner or Calmette) was also employed.

His technique was as follows:—With the sharp point of a straight surgical needle the epidermis was chafed off exposing a small circular patch of pink cutis vera. Bleeding or oozing was expressly avoided. On this vascular surface the tuberculin solution was placed and rubbed in by rotation of the head of the needle. A control surface was similarly prepared and inoculated with 50 per cent. glycerine.

The author tested this modification against von Pirquet's original method, and satisfied himself of its superiority. Two characteristics—a papule of a peculiar deep livid hue, and its persistence for not less than a week after its appearance—were required for a positive reaction. The strong solution of Koch's "old" tuberculin was employed.

In the group of diseases of bone, lymphatic glands and joints the reaction was very clear, and either emphatically positive or negative.

In 13 out of 14 of the cases of simple pleural effusion in children a positive reaction was obtained.

In cases of tuberculous peritonitis there were 9 positive and 3 negative results.

In tuberculous meningitis and general tuberculosis the results were nearly always negative.

Two cases are mentioned where a negative reaction was obtained owing to an atack of measles and in which there had previously been a positive reaction. Two cases of clinically tuberculous skin affections gave a positive reaction.

In early chronic cases the results obtained were very much in favour of the reliability of the test. If repeated the test was always confirmed, provided the general condition of the patient remained unchanged. There were seven cases of late reaction. In one case the areola did not appear until 72 hours after inoculation, and the papule until 120 hours. These late reactions all occurred in cases of widespread tuberculous disease or where the local disease was complicated by another lesion. They form a group intermediate between the vigorous reactions in early or moderate cases, and negative reactions in late cases.

In 78 cases Calmette's and von Pirquet's reactions were tried in the same patient. A 0·5 per cent. solution of dried tuberculin was used. von Pirquet's test was negative in 47 of these cases, and in these 47 cases Calmette's test was also negative in every case. Calmette's test, however, did not react in 10 cases in which von Pirquet's test was positive. In each

extreme, both of incipient and advanced cases, von Pirquet's test gave reactions where the conjunctival test did not.

In comparing these two skin reactions the author points out that their essential similarity must be admitted. Both are vascular reactions depending upon close contact of toxins with the capillary circulation, and in the case of von Pirquet's test a stronger solution can be used with safety and brought more effectively into contact with the circulation.

J. F. Cunningham.

Richard Hessberg. **Contribution to the Study of Congenital Total Colour Blindness.** *Klinische Monatsblätter für Augenheilkunde*, Aug., 1909.

Hessberg reports two families in which congenital total colour blindness affected several members. In one case the parents were cousins and had four children, three of whom—two boys and one girl—were affected. In the other case the parents were not related, and three children—two girls and one boy—were affected.

The first family is described in detail. The three affected children were well-developed, nervous system normal, and of good intelligence. There was considerable photophobia, most marked in the youngest, and apparently tending to decrease as the children grew older. They all had a rotary nystagmus of varying degree. Ophthalmoscopically, there was a very marked reflex from the vessels and the retina generally, and at the macula this took the form of two well-marked rings. The field of vision in a darkened room was normal in extent, and in a light equal to 5 meter candles an absolute central scotoma of 2 to 3 degrees in extent could always be found. Refraction was a compound hypermetropic astigmatism of moderate degree, and vision in bright light $^{2}/_{60}$ to $^{4}/_{60}$, while in a darkened room it rose to $^{6}/_{36}$.

In the spectrum the patients saw the brightest part in the green near the blue. Adaptation for darkness was obtained very quickly (three minutes), and flicker also disappeared much earlier than normal—10 to 11 revolutions of the card, as against 35 to 40 for the normal.

The author thinks the fault must lie in the retina, especially in view of the absolute central scotoma; but whether in a total

absence of cones or an imperfect development of these, or in some abnormality of the retina as a whole, cannot be decided. He is of opinion that the absolute central scotoma would be found in all cases if carefully looked for. A. Levy.

T. Clausnizer (Tübingen). **Does Monocular Vision Involve Injurious Consequences for the Eye?** *Medicinisches Correspondenz-Blatt des Württembergischen-ärtzlichen Landesvereins*, 24 December, 1909.

On this subject there is very little information, or at least very little which is supported on a basis of definite fact, to be found in literature. Yet every ophthalmic surgeon, especially in these days of compensation, sees cases in which the patient who has lost the use of one eye more or less completely, complains of inability to work with the other, or of such "strain" as it is vaguely called, on an attempt at continued application of the other, as to debar him from work. Of course in dealing with this matter Clausnizer purposely excludes from his present field of discussion cases in which there is any indication of actual objective damage to the second eye. What tells to some extent against ready acceptance of this "strain," but to which undue weight must not be given, is the fact that a person may not experience the smallest discomfort of this sort in whose case one eye never has possessed any useful sight at all, or when *amblyopia ex anopsia* in strabismus is present, or where vision has been slowly and gradually and insensibly lost by disease in one eye. The impression that such disability of the remaining eye after an injury to the other does exist is strongly embedded however in the public mind and is a valuable asset of the claimant for compensation and of his advocate. Nor is this opinion confined to the laity by any means. The loss of one eye involves many things, such as loss of a portion of the field of vision, loss of stereoscopic vision, interference with coordination of movements, etc., but is there a further injury in the fact that during active life one eye is compelled to exert itself constantly and is therefore liable to "strain" and perhaps to actual damage in consequence. The author quotes the views of one or two writers, who are not quite in agreement among themselves but who seem to consider it at least possible that

genuine injury to the eye may be brought about by the simple fact of its being left to do unaided the work of two; Axenfeld, for example, suggests that glaucoma may be induced, and Wagenmann points to hyperæmia of retina and choroid, but most authors on such subjects avoid the question altogether.

In order to investigate the subject thoroughly Clausnizer went carefully into all the cases which he could find in the Tübingen clinique in which enucleation had been carried out, and those in which unilateral blindness had resulted from injury or disease; to these are added others in which sight was reduced to mere "hand movements" from similar causes. Of this large body of cases (there were more than 1300 enucleations) only those were regarded as suitable for investigation in which at the time of the enucleation or injury there was no pathological condition of the uninjured eye, and further, cases only which had been watched for a minimum period of one year. With the necessary eliminations from one cause and another the cases available for the enquiry dwindled down to 313; of the persons 200 were men, 113 women. In 221 of the cases the original damage was a trauma, and in 92 it was disease. An interesting fact which came to light in the course of the enquiry was that of all these one-eyed persons, whose history was known over a period of years, not one had met with any serious injury to the remaining eye in that time. The author considers that this fact has some value as indicating that there is not increased liability to accident on the part of a one-eyed man; but surely with so small a number and so uncertain a period of time the superstructure is rather more than the foundation can safely bear. Over the whole the author found in 12 cases, or 3·7 per cent., a diminution in visual acuteness; these were distributed in almost "correct" proportion between the cases of injury and those of amaurosis with retention of the eye. In these cases of diminished acuteness of vision the question at once crops up: Is the loss to be ascribed to an injurious influence exercised in consequence of use of one eye only, or may the cause not be a subsequent disease arising quite independently of the original injury or amaurosis? In 11 of the cases the latter appeared certain. In the majority of cases the fall in visual acuteness was but slight, and the objective appearances and subjective manifestations agreed; in one case this was not so, for along with diminution of vision there was no objective change to be made out. And this case was the only one in which the fact of there being but a single eye could be regarded as the source of the loss of sight. Yet another interesting point

in certain of the cases was the increase of myopia in the single remaining eye, but too much stress must not be laid on this in view of the fact that statistics show that, irrespective of age, myopia advances in something like 47 per cent. of cases. Spasm of accommodation has been described as occurring as one of the results of having to work with one eye alone, but Clausnizer did not meet with this condition even once.

As regards the complaints made of discomfort and "strain" of the single eye these have increased considerably since the introduction of the Compensation Laws!* To bring the matter to a point, there is no evidence to be deduced from the investigation thus made by Clausnizer that the continued use of a single eye acting alone has any injurious effect upon that eye. He considers himself entitled to deny that the visual power is lowered, that the tendency to myopia is enhanced, and that there is any injurious influence on any structure of the eye whatever.

The close of Clausnizer's article deals with the question of compensation for loss of an eye; he considers that the scale of 25 to $33\frac{1}{3}$ per cent., which seems to be the present allowance, is decidedly too high, and suggests rather 20 to 25 per cent.

W. G. S.

Ophthalmic Year Book. Edited by E. Jackson (Denver, Colorado), G. E. de Schweinitz and J. B. Schneidemann (Philadelphia). Vol. VI. Herrick Book and Stationery Co., Denver, Colorado, U.S.A., 1909.

Again we have to note in terms of high appreciation this annual record of all that is new in our knowledge of ophthalmology, new in the pathology, the therapeutics, the clinical and social features of diseases of the eye. It would be hard to find any omissions from what is really a wonderful record of the literature since the previous issue. Great skill has been shown in the presentation of the salient points brought out in the various articles and papers, and though the book is a compendium it is yet quite pleasantly readable and far from "dry." Take any subject you can think of and you will find in the Ophthalmic Year Book something you did not know, some little point brought out, some exceptions to a general rule, some new method of attacking a problem. Take at random optic atrophy

* Apparently neither Compensationitis nor Ergophobia is unknown in Germany.

with cranial deformity, ophthalmia neonatorum, wounds implicating the orbit, scleritis, atoxyl, you will learn facts with which you were not familiar, and by looking up the literature index at the end you will find the reference to the original article should you wish to go to the fountain head.

Sir Jonathan Hutchinson. **Syphilis.** Cassell and Company, 1909.

The second edition of this well-known text-book has been largely re-written and somewhat expanded. As the distinguished author points out in his preface, he has been enabled to watch the results of his theories, and treatment based thereon, for a longer period than usually falls to the lot of the surgeon. He states that he is, as a result, not disposed to depart from his belief in the amenability of the disease to treatment, and still holds the opinion that the most satisfactory treatment consists in the use of long-continued small doses of mercury by the mouth, and that that treatment should be resorted to as early as possible. With the newer methods of treatment by injection he is not in sympathy, and quotes cases showing the risks thereto attached. The chapter relating to the eye is not of very great length and does not call for much criticism. We do not like the term aquo-capsulitis, which he describes as "a form of insidious and chronic iritis, of which the most conspicuous phenomenon is the dotted condition of the posterior lamina of the cornea." In the description of diffuse retinitis and disseminated choroiditis on page 108 we notice a misprint; "no tolerance of light" being written for no intolerance of light.

The great value of the work is due to its being the conscientious record of one man's great experience, and not, as is only too common in such text-books, a compilation of quotations. The illustrations are well reproduced.

M. S. Mayou (London). **Ophthalmic Operations: being a section of Vol. IV. of "A System of Operative Surgery."** Oxford Medical Publications, 1909.

Mr. Mayou is to be congratulated upon the skill which he has shown in the selection of operations upon the eye which he has decided to describe, and in the short, clear, sufficient manner in

which he has brought out the indications for operation, the method of performance in its various steps, the difficulties, the advantages of this method or that, and its disadvantages, and the final result which may be looked for. No doubt every other surgeon would have left out certain of the modes of procedure described and have introduced others according to his personal preference, but it would be unfair to Mr. Mayou to complain of his choice, for he has acted judiciously. His brochure forms part of a volume in which surgical procedures on other parts of the body are described—one volume out of several forming an exhaustive treatise on Operative Surgery, edited by F. F. Burghard: if the other parts are as well written and illustrated as Mr. Mayou's the book as a whole will be a very valuable addition to the library of any surgeon.

Karplus and Kreidl (Vienna). **The Brain and the Sympathetic.** *Pflüger's Archiv. für Physiologie.* Vol. 129, 1909.

In this paper, which is only the preface to a longer paper to be subsequently published, the authors state that they have been able to find a definite spot in the base of the mid brain, stimulation of which by moderate currents is followed by maximal dilatation of the pupils on both sides, and also by other results of sympathetic action, which remain to be fully described in the next paper. This spot lies between the optic tract and the third nerve, lateral to the infundibulum. Section of the sympathetic nerve in the neck prevents these effects on either or both sides according to whether one or both nerves are destroyed. Provided that the crus is left intact, this centre may be cut off from all connections with the rest of the brain without interfering with the results of stimulation. To determine whether this spot really corresponds to a centre, or is only a tract, degeneration experiments are now being made by the authors. It appears to correspond roughly with the corpus subthalamicum. I shall hope to be able to give more accurate details when the complete series of experiments are published.

E. E. H.

Berlin Ophthalmological Society.

20 January, 1910.

Ectropion of the Iris. Adam showed a case of bilateral ectropion of the iris which had a two-fold interest: first on

account of the exact symmetry of situation, viz., inwards and slightly downwards. This appeared to support the statement of the patient that it had been present from earliest childhood and might be congenital, though as a matter of fact it was of inflammatory origin. Secondly, the case is noteworthy as affording a strong indication of the actual mechanism of its origin. Von Michel's explanation of ectropion of the iris attributes it to mechanical traction; Fuchs differs, and explains it as owing to atrophy of the stroma; in consequence of this the posterior (pigment) layer of the iris is enabled to grow round and encroach upon the anterior. Gallenga puts forward a somewhat complicated theory, attributing the condition to persistence of the sinus annularis (Szili), in virtue of which the pigment layer grows at the expense of the anterior layer. His theory has a good deal in common with that of von Michel. Lohmann describes a band of pigmented cells immediately underlying the surface of the iris, to which he attributes the ectropion. In this particular case the theory of a contraction cause could be considered to be almost proved, for at various parts, and especially just at the site of the ectropion, bands of contracting exudate could be clearly seen. This tendency to ectropion naturally would be increased when the pupil attempted to contract, and the eversion of the pigment layer would be enhanced. In one eye there was a calcareous cataract with amaurosis: in the other, in which a glimpse of the fundus could be obtained, there was glaucomatous cupping on account of the closure of the angle of the chamber. In the discussion on the case Guttman described and illustrated two cases of the same condition, one of which was certainly traumatic.

Persistent Pupillary Membrane. Napp showed a case in which a fine thread passed right across the pupillary area.

Acute Glaucoma. Hamburger showed the case of a man of 53 whose attack had come on 3 hours previously; two hours before exhibiting him Hamburger administered internally some fluorescin. Though the man's face, etc., was coloured by this his eyes were not. Had there been iritis his aqueous humour would have acquired a faint greenish tinge within half an hour, as has been proved; the absence of such tinting may therefore on occasion prove a valuable help in diagnosis.

Discussion of Hamburger's paper on the nutrient currents of the eye was then resumed.*

Türk said there were certain objections to Hamburger's

*See previous Report.

theory as to the nutrient stream, in particular this: Were the fluid in the posterior chamber to contain much albumin normally, when the pupil underwent physiological dilatation in the dark, the contents of the anterior and the posterior chambers must mix, and the aqueous must then contain albumen. This would be even more true of an iridectomised eye or of one under atropin, when albumen would be constantly present in the aqueous. There is no evidence whatever that such is the case, and if we are to believe that the characters of the fluids are different, proofs should be brought forward of these alterations of the aqueous. Hamburger is not justified in basing his opinion that the normal contents of the anterior chamber have no relation whatever to the activity of the ciliary processes, on the ground that when these can be shown to secrete the resulting fluid is rich in albumen and fibrin. The fact that the fluid obtained on puncture of an eye in an inflamed or congested state contained no albumen would not be a safe ground for an emphatic statement as to the physiological mechanism. Again the fact is against his theory that the fluid obtained after one single puncture contains almost no albumen. When the anterior chamber is thus emptied, the lowering of the tension involves that the fluid from the posterior chamber must necessarily pass forwards into the anterior and there the fluids from the (supposed) two sources must mix. There can be very little reason to doubt that the source is the ciliary processes, whose epithelium has been shown by Greeff to be swollen and œdematous—at all events after puncture of the globe. As regards the physiological exclusion of the pupil of which Hamburger speaks, it seems probable that if it does occur it can only be temporary, and must give way at intervals, allowing fluid to pass from posterior to anterior chamber. Some of Hamburger's previous investigations seem to assist in proving this opening up at intervals of the communication between the two chambers, for he has described how, after introducing fluorescin into the posterior chamber, he has seen a minute particle of the coloured matter after a longer or shorter interval approach the boundary line and suddenly with a jerk "step through." The same process goes on incessantly. Others also have watched it taking place, and Ulbrich described a very interesting case in which an incomplete coloboma of the iris existed: a delicate folded membrane appeared to close partially a gap in the iris, and from time to time this became bulged forwards, then after an involuntary wink had occurred, but not after every one, the membrane suddenly changed its

attitude and became concave forwards, bulging into the posterior chamber; this to and fro movement went on incessantly at varying intervals, and was held to indicate that when the membrane was bulged forwards there was relatively higher tension in the posterior than in the anterior chamber, fluid then, having slightly accumulated, rushed through into the anterior chamber, equalising the pressure: again the fluid collected, coming from the ciliary processes, and the cycle was gone through once more. If this interpretation be correct it seems distinctly to point to the ciliary processes as the source of the aqueous, at all events in part. Whether the iris itself may also have a share in its formation is not of course negatived by it. As to the absorption by the veins of the iris, the effect of miotics and mydriatics on the tension of the eye, increasing or diminishing as they do this supposed absorbing area, is too well-known to need comment, but it seems still probable that the main part in this work is performed by the filtration angle and Schlemm's canal.

Radziejewsky finds confirmation of Hamburger's views in the results of subcutaneous injection of uranin; a green fluorescent streak is seen running across the pupil from above downwards, above it may reach to the angle of the chamber, and it gradually tints the aqueous. The green fluid is not seen to enter the pupil and pass to the aqueous unless the anterior chamber has previously been tapped. Aqueous can only be secreted when there is some difference between the inflow and the outflow. Since the line or streak can appear even two hours after the death of the animal, the explanation must be that the process is one of simple diffusion, acting chiefly from behind forwards. Hamburger is however in error, according to Radziejewsky, in that the iris has been shown not to have any close adhesion to the lens; he compares the condition of the iris to that existing in the cardiac valves. He regards the broad surface of the iris as a very important absorbing surface, materially lightening the work of Schlemm's canal and helping to restore or to keep unchanged the normal tension. An iridectomy is specially of value in glaucoma when the iris has lost so far its contractility that the pupil remains unchanged of medium size; the fluid can thus reach the ciliary veins and be absorbed through the gateway made. Iridectomy is of little service on the other hand when the iris tissue is rotten and brittle.

Greeff pointed out how improbable it was that the iris should have the double function of secretion and absorption.

Abelsdorff drew attention to the fact that when the iris is removed from an animal in which this can be done without undue damage to the eye, no alteration in the normal fluid exchange appears to occur.

In the course of his reply on the discussion Hamburger pointed out, in opposition to Leber, that a tissue may quite well have the double function of absorption and secretion, for that is true of every mucous membrane, of the peritoneum, of synovial membranes. He had not denied the function of Schlemm's canal as an absorbing area, but regarded it as only one of several avenues. In some respects he could not accept Leber's investigations as conclusive in this connection, and defended the use of fluorescin in making physiological investigations. As regards the ciliary body being the origin of the aqueous, we know at present no other ciliary secretion than that which contains albumen and fibrin; it follows that the aqueous cannot be ciliary secretion.

Trachoma Bodies. Flemming had found trachoma bodies in the genital mucous membrane as well as in the conjunctival more frequently than merely in trachoma. This he asserted on the strength of more than 270 examinations in human beings and monkeys, and in blennorrhœa neonatorum, even in the gonorrhœal type. He recognised two forms which might perhaps be different stages of the same, but he admitted that he had never observed transition of one into the other. In 32 fresh cases of ophthalmia neonatorum he had found trachoma bodies 12 times, 6 times in gonorrhœal and 3 times in pneumococcal, 3 times without any bacterial excitant. He could not regard these bodies as the direct cause of trachoma, but what their precise influence might be no one was as yet in a position to say.

Halberstädter believed these bodies to be specific, but he also admitted finding them in non-bacterial blennorrhœa; he had never found them in the gonorrhœal variety. He had once obtained them from the maternal canal.

W. G. S.

THE OPHTHALMOLOGICAL SOCIETY OF THE UNITED KINGDOM.

Thursday, January 27th, 1910.

The President, Dr. G. A. Berry, *in the Chair.*

Multiple Superficial Atrophic Areas of Irides in old Kerato-Iritis of Inherited Syphilis.—Mr. N. Bishop Harman.

A. L., a female, aged 9; the subject of inherited syphilis, was practically blind owing to the effects of a severe kerato-iritis. In the right eye there was much interstitial scarring, particularly in the lower quadrant; the iris was bound down to the lens capsule, and there was also a fine strand adherent to the cornea above. In the left eye similar changes existed, but a small part of the pupillary border of the iris was free upwards and inwards. Both irides showed a number of brown oval and round spots, the colour being due to the pigment layer showing through atrophic holes in the overlying stroma; the areas varied greatly in size, from ·5 mm. in diameter to 1 or 2 mm. There were 22 holes in the right eye and 13 in the left.

Exophthalmos and Facial Deformity (as in Oxycephaly) without deformity of the Skull Cap.—Mr. N. Bishop Harman.

S. F., a girl, aged 10, was born of Jewish parentage, who showed no abnormality either in themselves or their other children. The patient showed the typical physiognomy of oxycephaly so far as the eye and face went, but there was no head deformity. Proptosis was especially well marked, and the lids only just met over the globe; some divergence of the optic axes existed, but no nystagmus. The child did not know her letters, but her vision appeared to be good and the fundus of each eye was normal, and the discs well shaped and of good colour. The head was rather small, but its contour was quite normal, and there was not the slightest suggestion of elevation along the frontal or sagittal sutures or anywhere else, nor was there any asymmetry. The body, hands, and feet were quite normal.

Hæmorrhage at the Macula.—Mr. M. L. Hepburn.

Charlotte S., aged 41, was the same case as that shown at the Society's meeting on December 9th, 1909. During the interval the hæmorrhage had undergone important changes; the blood had been completely absorbed, only a faint suspicion of redness on the temporal side still remaining; the whole area had become white, and, although retaining its original circular shape, was considerably smaller than the disc and had a slightly crenated border. The vision was only $^{2}/_{60}$. The mode of disappearance of this hæmorrhage after six weeks' interval pointed to

the fact that the view expressed regarding the origin of the blood, viz., from the choroidal vessels and in the substance of the retina, was the correct one.

Sarcoma of the Choroid.—Mr. G. Winfield Roll.

E. C., female, aged 64, came complaining of failure of vision in the left eye for six months; both eyes were normal in external appearance, and the tension was also normal. The right vision was $^{6}/_{6}$, and the left perception of light. There was defective visual field in the left eye, with some vitreous opacities and a detachment of the retina near the optic nerve concealing part of the disc; in places the retinal detachment was filled out and tense, and there were no folds; some flame-shaped hæmorrhages were also present. Both eyes showed some patches of choroiditis, but the areas were free of pigment; no new vessels could be seen anywhere. Pathologically a deeply pigmented sarcoma of the choroid was found which showed no evidence of invading any of the neighbouring structures, but was growing laterally along the lines of least resistance, and the membrane of Bruch was intact.

A case of Lacrymal Tumour.—Mr. Ormond.

Catherine S., aged 59, came, in May, 1907, complaining of "something soft" over the right eye. The vision in this eye was $^{6}/_{9}$, and that of the left $^{6}/_{6}$. Iodide of potassium was administered, but the swelling increased in size. In October, 1907, a piece was removed and subjected to microscopical examination, when it was pronounced to be ordinary hypertrophy of the lacrymal gland. In June, 1908, there was proptosis of the right eye which was displaced downwards and inwards, and the movement upwards was limited. There were some enlarged veins in the skin of the upper lid, and the whole of the conjunctiva was red and œdematous, while the pre-auricular gland was slightly enlarged. Eccenteration of the orbit was performed and the enlarged gland also removed. Later on tumours appeared in the upper arm, abdomen, and thigh, and in June, 1909, one situated just below the hip was removed.

Peculiar Retinal Changes due to Traumatism.—Mr. C. Blair.

F. R., aged 52, showed in the right eye (the vision being finger counting only) a bluish-white, well-defined, somewhat raised oval area situated in the macula region, and below this was a white, broad, irregular band; above and internal to this was an area of reticular appearance formed by a network of whitish deposit, and external to this was one large white patch with many scattered white dots round it. The retinal vessels were superficial to the patches.

Granuloma or Papilloma of the Conjunctiva.—Mr. C. Wray.

J. M., aged 15, came for treatment in April, 1909; and there appeared a sessile growth of a papillomatous nature, the size of a small pea, springing from the caruncle and inner surface of the lower lid immediately behind the punctum. The growth was excised and found to be an innocent papilloma; but after a few months a good deal of granulation-like growth was seen under the upper lid involving the inner third.

Scotomagraph with Stereoscopic Fixation.—Mr. J. H. Tomlinson.

This instrument, though primarily designed for mapping out blind or anæsthetic areas, can be used for general perimetry. The test object is a second image of the fixation point, obtained by reflection from a long narrow mirror hinged near the eye-piece of the instrument. The angular position of the second image, as seen by the retina, is determined by the position of the mirror which can be rocked about its hinge through a device inside the instrument. The whole apparatus can be rotated about its axis so that while the fixation point remains unmoved the second image makes a circular excursion, thus enabling the method of Bjerrum to be employed in testing for glaucoma. An automatic registration is obtained by means of a needle which is carried by the mirror and extended pneumatically by a mechanism similar to that used for operating a photographic shutter. The second eye looks down a tube at a small spot the same size as that already viewed by the eye under examination; the brain interprets this as the same spot and stereoscopic fixation is thus obtained.

A New Simple Ophthalmoscope.—Mr. Priestley Smith.

Described in detail in the February number of the *Ophthalmic Review.*

Papers.

Note on a Case of Bilateral Ophthalmoplegia Externa in an Infant.—Dr. F. E. Batten.

This paper was accompanied by photographs illustrating the condition. In March, 1909, the child, aged 10 months, attended Great Ormond Street with the history that a discharge from the right ear showed itself fourteen days after birth and ceased when the child was 2½ months old. When 7 months old a squint was noticed, and at 8 months there was weakness of the right side of the face; one month later the head was drawn to the right, and some twitching of the muscles of the face was observed. In all other respects the child was well.

In March, 1909, there was marked external strabismus and slight ptosis in both eyes, with almost complete paralysis of all the muscles supplied by the third nerve in the right side; a similar but less marked condition was seen in the left. There was no neuritis or optic atrophy, but slight weakness of the right arm and leg was present with constant rythmical movements; knee-jerks were equal and active; there was no ankle clonus, but some craniotabes over the left parietal region was noticeable. Von Pirquet's reaction was positive, and tubercle bacilli were found in the cerebro-spinal fluid, and this was confirmed on several subsequent examinations.

In April, 1909, there were right-sided convulsions, and the child by this time was drowsy and had to be fed with a nasal tube, while the third nerve paralysis was complete. Death occurred in June, 1909, and post-mortem a tubercular mass was found on the surface of the cortex in the left occipital region with a large tumour of the same nature in the region of the optic thalamus and corpora quadrigemina.

Congenital Anterior Synechiæ with Buphthalmos.—Mr. M. S. Mayou.

F. K., aged 7 weeks, was the third child in the family, all of whom were alive, and well with this single exception. There was no history of instruments being used at birth nor vaginal discharge previous to labour, and no other congenital malformation was discovered. The mother noticed the left eye larger than the right at birth. The child had obviously bad vision, there was well-marked nystagmus, and the right eye had eccentric fixation. The left eye was blind and buphthalmic, with a bombé iris, but the cornea was clear and there were no cracks in Descemet's membrane; the iris was closely applied to the back of the cornea, was atrophic, and showed white markings on its anterior surface; the pupil was small, round and inactive to light; the lens clear and well forward against the posterior surface of the cornea; no anterior polar cataract was present. Between the lens and the vitreous was a white mass with no vessels on its surface, and clinically the case resembled a pseudo-glioma.

The eyeball was excised and found to measure 1·5 cm. antero-posteriorly, and the cornea was 1·4 cm. across. The corneal epithelium was normal and the substantia propria of the cornea clear; the iris was adherent anteriorly and the pupillary margin had not separated off. Descemet's membrane covered the back of the cornea nearly up to the position where the iris was adherent, but this structure was absent in the position of the adhesion and over the whole of the pupillary area. The iris tissue actually at the adhesion was thicker than elsewhere, and resembled at this point more the substantia propria of the cornea than iris structure. The angle of the anterior chamber, the ligamentum

pectinatum, and ciliary muscle were all ill-developed, and the suspensory ligament of the lens was absent. The ciliary processes were adherent all round either to the sides or posterior surface of the lens forming a pigmented diaphragm between the vitreous and the posterior chamber, and wherever these processes were united to the posterior surface at these points the ora serrata had not developed, but this was not the case when the ciliary process was attached to the sides of the lens. Posteriorly there was a gap in the lens capsule which was filled in by loose atypically developed fibrous tissue. The retina showed both the ganglion cell layer and the rods and cones badly developed, while near the disc were found rosette arrangements similar to those seen in glioma of the retina and microphthalmos. The optic disc exhibited a coloboma of the nerve sheath.

Mr. Mayou considered that the defects in the posterior part of the globe were due to failure of separation of the mesoblast forming the iris and the cornea; therefore there was no anterior chamber, thus leading to absence of filtration and so buphthalmos. The ciliary body was not displaced forwards owing to its attachment to the lens and the failure in development of the suspensory ligament accounted for the adhesion of the ciliary processes to the lens. The anterior lenticonus was due to the lens being adherent to the cornea and thus being pulled forwards. Dragging of the ciliary processes produced rupture of the posterior capsule and so atypically developed fibrous tissue proliferated into the opening.

The other eye was amblyopic, and it is possible that some of the malformations seen in the retina in the one eye might also have been present in the other.

In the remarks that followed on this paper,

Mr. Collins said that this case proved that congenital anterior synechiæ might be due to developmental defect apart from ulceration. He commented on the effect of non-development of the suspensory ligament in producing lenticonus. He said that the gaps in the posterior capsule were due not to rupture but to failure of development.

Mr. Parsons said that there were obviously many points in this case which were due to faulty development; he regretted the term buphthalmos, as intra-uterine inflammation often left very few signs of its previous existence, and having once occurred it might seriously interfere with the normal process of development. He agreed with Mr. Collins in his interpretation of the presence of gaps in the posterior capsule of the lens.

Mr. Coats considered that Mr. Mayou's case should be regarded as an entirely different type to the ordinary congenital anterior staphyloma, and for this reason he considered the term buphthalmos a good one.

This case satisfied all Mr. Collins' points in regard to mal-development, but it was for this very reason that it should not be classed as a congenital anterior staphyloma such as those already described by himself and others.

Thursday, February 10th, 1910.

Vice-President, Mr. Hartridge, *in the Chair.*

Optic Atrophy and Oculo-Motor Palsy due to Intra-Cranial New Growth.—Mr. J. B. Lawford.

H. D., male, aged 40. Came to St. Thomas's Hospital in Nov., 1909, complaining of blindness in the left eye for three weeks, and failing sight in the right for the same time. The vision in the latter was $^{6}/_{60}$, the pupils reacted well, there was moderate proptosis with defective movement downwards and inwards; the fundus appeared healthy. In the left there was only perception of light with a dilated and inactive pupil, and only slight reaction to accommodation; there was some proptosis, and upward rotation was lost, while the upward movement was defective. The optic disc was markedly pale and the retinal vessels were reduced in size; sense of smell was lost. An X-ray examination revealed "rather deep erosion of the floor of the middle fossa of the skull; the pituitary fossa and sella turcica are destroyed." Since admission the condition has got steadily worse, so that the vision in the right was bare perception of light, and that of the left none whatever. All the other symptoms were more marked, and the both optic discs were pale.

Drawing of Episcleral Tubercle.—Mr. J. B. Lawford.

J. W., a male, aged 10, came to St. Thomas's Hospital on May 27th, 1902; the boy was one of ten children, eight of whom were living; a maternal aunt died of phthisis. This child had glands in the neck and had suffered from sacro-iliac disease. In the lower temporal part of the right globe was a sharply-defined prominent nodule about the size of a split pea, covered with dilated veins. The nodule was adherent to the sclera. Another smaller nodule appeared between this and the limbus. On May 29th both were removed, and it was proved experimentally by inoculation that the nature of the growth was of tubercular origin.

Lenticonus Posterior with Opaque Membrane behind the Lens.—Mr. E. Treacher Collins.

Irido-Cyclitis with Gross Keratitis Punctata.—Mr. N. Bishop Harman.

Cases from Families with Hereditary Anterior and Posterior Polar Cataract.—Mr. N. Bishop Harman.

The drawing was shown of these cases, but the patients themselves did not come to the meeting.

Posterior Polar Lens Defect (? Lenticonus).—Mr. N. Bishop Harman.

John S., aged 66, came under treatment for failure of sight. The vision in both eyes was $^{6}/_{60}$, and the nuclei of the lenses in both eyes were dense to focal illumination. The opinion was expressed that this was really a case of nuclear sclerosis, and to this Mr. Harman agreed.

A New Form of Lantern for Testing Colour Perception.—Dr. F. W. Edridge Green.

An Unusual Form of Retinal Disease.—Mr. A. C. Hudson.

Harold N., aged 9, came to the Central London Ophthalmic Hospital on Jan. 27th, 1910. There was no family history of any importance. When the child was one month old he suffered from spasmodic bronchitis ushered in by epistaxis and unconsciousness; at $2\frac{1}{2}$ he also had whooping cough. The vision in both eyes was $^{6}/_{6}$ with +1·5. In the left eye at the lower middle portion of the fundus were a number of bright shining translucent plaques like white paint scattered about having no special relation to any particular retinal vessels and evidently on a more anterior plane; white lines appeared along some vessels in places. Mr. Hudson considered the cause of this condition was due to a hæmorrhage which had taken place earlier in life and produced by irritation the changes which were present.

A Case of Bilateral Parotitis and Cyclitis.—Mr. E. W. Brewerton.

F. E., aged 17, came on Nov. 18th, 1909, with a rash on the face and arms; he had suffered for five days from a sort of nettlerash, and as it was subsiding a hard lump appeared on the right side of the face about the size of a marble; soon afterwards a lump also appeared on the left side; and there was no pain or difficulty in masticating. Not long after the parotid swelling, both eyes showed a ciliary flush, and K.P. and posterior synechiæ were discovered, which were very intractable to treatment and still going on.

Hole at the Macula.—Mr. R. Foster Moore.

H. L., aged 24, male, was struck in the left eye with a piece of wood. and three or four days later found he could not see properly; since that time there had been no change, and the eye was practically useless. For the last two months he had noticed the right eye getting dim, and

all objects appeared cloudy. No history of syphilis or any serious illness. The vision in the right eye was $^6/_5$ with +2 sph., and $^6/_{60}$ in the left. By ophthalmoscopic examination both eyes showed symmetrical changes at the macula, occupying an area about $1\frac{1}{3}$ the size of the disc. In the right eye was a circular hazy œdematous area well defined and slightly raised at the edges with some small exudates on the surface. The left eye showed an affection of a similar nature, but here there was the appearance of bright red holes with shelving edges, and many whitish areas of all sizes scattered about in this region. Other parts of the fundus in both eyes were clear.

Connective-tissue Formation on the Disc.—Mr. L. Paton.

Rose C., aged 17, came with a very indefinite history; her right vision was $^6/_6$, and that of the left counting fingers; the vision was gone in the lower nasal field. Projecting in front of the disc and forwards into the vitreous was a white shining mass seen best with a +10 D. From the top of this several strands of connective-tissue projected further forwards still, and surrounding the central vein were a series of nodular semi-translucent masses seen best with a +6. There was sheathing of the retinal vessels in a few places and disturbance of the retinal pigment not far from the disc.

Granuloma (?) of the Conjunctiva.—Mr. C. Worth.

Frank D. had shown a pink spot on the left eye for eight months. Just on the sclero-corneal margin downwards and inwards there appeared a flat pad of conjunctiva in which, radiating from a common centre, were some vessels arranged like the ribs of an umbrella, and each rib had an afferent and efferent vessel. It was attached to the sclera by a small pedicle. No history was forthcoming to account in any way for this condition.

Electrical Method of Rotating Testing Block, in place of the Cords.—Mr. R. E. Bickerton.

Linear Opacity of the Cornea with Retinal Degeneration following Birth Injury.—Mr. E. E. Henderson.

Ivy W. showed in the left eye a straight linear opacity of the cornea situated in the deeper layers. On examining the fundus the whole of the nasal half was obscured by a large mass of bright shining fibrous tissue passed forwards as far as one was able to see.

? Epithelioma of the Cornea.—Mr. H. H. B. Cunningham.

The case was not shown, but a drawing was exhibted of a man, aged 36, where both cornea were affected with large growth occupying about half of each cornea; and the question arose as to whether this was of an epitheliomatous nature.

Obstruction of Inferior Temporal Branch of the Central Artery of the Retina.—Mr. Arnold Lawson.

A month ago the eye was struck with an elastic chest expander, and the vision afterwards was fingers at 3 feet. Below the disc was a large patch of retino-choroidal atrophy exposing the choroidal vessels and the sclera; over this patch passed the inferior retinal artery with obviously no blood in it, and its origin was obscured by a patch of exudate.

Swelling near the Pupilla of Doubtful Nature.—Mr. Arnold Lawson.

For two months there was a history of defective vision in the left eye, and three weeks ago a small swelling was first seen at the upper and outer part of pupilla. The vision with correction was $^{6}/_{18}$ and was best seen with a +2sph., while the summit of the swelling was most distinct with a +4. At the time of showing (Feb. 10th, 1910) the swelling had increased so that it occupied a concentric area round the lower and outer part of the circumference. There were no hæmorrhages to be seen, and no view of the vessels was possible.

MALCOLM L. HEPBURN.

THE INJURIOUS EFFECTS OF LIGHT ON THE EYE.

BY

W. Halliburton McMullen, M.B., B.S., F.R.C.S.

Assistant Surgeon to the Royal Westminster Ophthalmic Hospital.

It has long been known that injury to the eyes may result from exposure to excessive light. Eclipse blindness is referred to by some of the ancient Greek writers. Mountaineers and Arctic explorers have been familiar with snow blindness since very early days. Since the introduction of electricity for lighting and industrial purposes electric ophthalmia has become a fairly common disorder.

Eclipse blindness, snow blindness, and electric ophthalmia are the clinical conditions in which the injurious action of light is most unmistakable. Glass-blowers' cataract and cataract following lightning stroke have also been attributed to the action of light, especially of ultra-violet light, but it is probable that other factors play a part in the causation of both these conditions.

Eclipse blindness is so called because the symptoms most often follow attempts to watch an eclipse of the sun with insufficiently protected eyes, but the same symptoms may be caused by looking at any intensely bright light with unprotected eyes. The most important and characteristic symptom is a central or paracentral scotoma, generally positive. In most cases there are no changes in the fundus visible with the ophthalmoscope, but sometimes there is a little cloudiness or discolouration at the macula which, on clearing up, may leave some fine spots of retinal pigmentation. Slight cases recover completely. In severe cases a permanent scotoma remains. Transient conjunctivitis sometimes

occurs at the outset. Other changes described in certain cases, such as optic neuritis, thrombosis, retinal hæmorrhages, and detachment of the retina, were probably accidental complications, and not due to the action of light alone.

The symptoms of snow blindness, which come on after prolonged exposure to the glare of sunlight reflected from snow, especially at high altitudes, are chiefly those of severe conjunctival irritation. They are pain, photophobia, lacrymation, hyperæmia and swelling of the conjunctiva, mucoid discharge, and occasionally superficial opacities and erosions of the cornea. Rarely retinal changes are said to occur.

The symptoms of electric ophthalmia are similar to those of snow blindness. They are most commonly excited by exposure to the glare of an electric arc formed by accidental short circuiting. Occasionally retinal lesions are produced similar to those seen in eclipse blindness. There is a latent period of four or five hours between the exposure to glare and the onset of the ophthalmia.

The injurious action of light upon the eye has been experimentally investigated by a number of workers with the object of determining what lesions can be produced by light in various parts of the eye and what rays are responsible for the production of these lesions.* In most cases the light used was that of an electric arc or of a uviol mercury vapour lamp, both of which emit a high proportion of ultra-violet rays.

It will be convenient, in discussing the conclusions to be drawn from experimental and clinical observations, to consider the effects of light (*a*) upon the superficial parts of the eye, (*b*) upon the lens, and (*c*) upon the retina.

* The visible spectrum includes rays of wave length from about 760 $\mu\mu$ at the extreme red end to about 400 $\mu\mu$ at the extreme violet end. The ultra-violet spectrum given by an arc lamp includes rays of wave length from 400 $\mu\mu$ to 220 $\mu\mu$ or less.

A. *Effects upon the superficial parts of the eye.*

Exposure at close quarters to the intense light of an electric arc or mercury vapour lamp very readily excites in animals symptoms of electric ophthalmia. If the exposure be prolonged, or the light concentrated, there may be produced, in addition to conjunctivitis, considerable opacities and erosions of the cornea, hyperæmia of the iris, and exudations into the pupillary area. The development of these symptoms can be almost completely prevented by placing a screen of ordinary window glass between the source of light and the eye. This glass absorbs all rays of wave length less than 300 $\mu\mu$. It must, therefore, be these rays which are most active in exciting superficial inflammation of the eye. The action upon the conjunctiva of rays of longer wave length than 300 $\mu\mu$ is not, however, absolutely negligible, for Schanz and Stockhausen[1] succeeded in exciting well marked conjunctivitis in a rabbit by four hours' exposure to a powerful arc lamp, even when a glass plate 18 mm. thick was interposed. And one of these authors himself suffered from a severe attack of electric ophthalmia after exposure for half an hour to the light of an arc lamp, although the arc was enclosed in a glass globe and his eyes were protected by clear spectacles. They found that all signs of irritation could be prevented by the use of a screen of euphos glass, a tinted glass introduced by them which completely absorbs all ultra-violet rays. These observations appear to prove conclusively that electric ophthalmia is due to the action of the ultra-violet rays, and chiefly to that of rays of wave length less than 300 $\mu\mu$.

There can be little doubt that snow blindness also is due to the action of the ultra-violet rays. The symptoms are the same as those of electric ophthalmia. It occurs especially after exposure to snow glare at high altitudes, where the sunlight contains a much higher proportion of ultra-violet rays than at lower levels. There is

generally a latent period before the onset of symptoms, and such a latent period is characteristic of the action of rays of short wave length.

Chronic inflammation of the conjunctiva may result from repeated and long continued exposure to intense light. It is not uncommon in persons exposed to the glare of desert or white roads in the tropics. It has also been observed in people working in a brilliant light from mercury vapour lamps. Some people complain of smarting and burning in the eyes after working in the light of electric glow lamps, especially metal filament lamps. In view of the experimental proof of the irritant action upon the conjunctiva of ultra-violet light, it is not unreasonable to suppose that in all these cases the conjunctival irritation is due, to a great extent at least, to the action of these rays. Birsch-Herschfeld[2] has obtained very interesting results from repeated exposures of rabbits' eyes to the light of a uviol mercury vapour lamp. He exposed some of these eyes as often as 150 times during 18 months, for ten minutes each time. Each exposure caused an attack of electric ophthalmia, and at the end of that time there were well marked changes in the conjunctiva exactly similar to those occurring in spring catarrh. He does not, however, consider that these experiments warrant the conclusion that spring catarrh is primarily due to the action of light, although such action may help to produce it.

B. *Effects upon the lens.*

Several workers have described changes in the lens produced experimentally by exposure to intense light. The evidence as to which rays cause such changes is conflicting. Widmark[3] obtained clouding of the lens by exposure to the light of an electric arc between zinc terminals, concentrated upon the eye by means of a condenser consisting of quartz lenses with water circu-

lating between them. This condenser absorbed heat rays, but was transparent to ultra-violet rays. No clouding of the lens was observed when he used a similar condenser consisting of glass lenses with quinine solution between them, which absorbed all ultra-violet rays. Hess[4] demonstrated microscopical changes in the lens epithelium produced by exposure to the light of a uviol mercury vapour lamp. These changes were prevented by the interposition of a plate of ordinary glass 1 mm. in thickness between the lamp and the eye. On the basis of these and similar experiments it was very generally concluded that the lens changes observed were due to the action of the ultra-violet rays only, and especially of those of wave length less than 300 $\mu\mu$.

Doubt has been thrown upon this conclusion by experiments made to determine the absorptive power of the media of the eye. Recent observations on this subject have been made by Schanz and Stockhausen[5] and Birsch-Hirschfeld,[6] who determined the powers of absorption of the various media by means of photographs taken with a quartz spectrograph. They have shown that the cornea possesses about the same power of absorption for ultra-violet rays as ordinary glass. According to Birsch-Hirschfeld it absorbs all rays of wave length less than 306 $\mu\mu$, and there are practically no variations in different animals or at different ages. It appears impossible to reconcile these observations with those of Hess. If the cornea absorbs all rays of wave length less than 306 $\mu\mu$ it must be rays of greater wave length that cause the lens changes, yet Hess found that a screen of glass absorbing only rays of wave length less than 300 $\mu\mu$ prevented lens changes. Birsch-Hirschfeld states, further, that he has obtained lens changes, identical with those described by Hess, by exposing a rabbit's eye for five minutes on each of three successive days to the concentrated light of an arc lamp from which all ultra-violet rays were filtered off by a euphos glass screen.

It seems, therefore, that the production of lens changes cannot be justly attributed to the sole action of the rays of a limited region of the spectrum. It is possible that all rays which reach the lens, luminous as well as ultra-violet, play some part in the production of these changes; but since they are most easily produced by light rich in ultra-violet rays, and since these are the rays of greatest photo-chemical activity, it seems reasonable to attribute to the ultra-violet rays which reach the lens, viz., those of wave length between 300 and 400 $\mu\mu$, the greatest share in the production of these changes.

An interesting phenomenon which has attracted considerable attention is the fluorescence of the lens which occurs under exposure to ultra-violet light. This fluorescence has been shown by Schanz and Stockhausen[7] to be excited mainly by rays of wave length between 400 and 370 $\mu\mu$.

The lens possesses a high power of absorption for ultra-violet rays, varying to some extent at different ages and in different animals. The human lens, according to Schanz and Stockhausen, absorbs in youth nearly all rays of wave length less than 375 $\mu\mu$, and after middle age completely absorbs all rays below that limit. It has been suggested that senile cataract may be due to the action of ultra-violet rays. It is pointed out that a large proportion of rays possessing a high degree of chemical activity is absorbed by the lens, a part being converted therein into visible rays by fluorescence, but a larger part not producing any immediately visible effect. Since lens opacities can be produced experimentally by the concentrated action of such rays in a short time, it is suggested that the action of the ultra-violet rays present in sunlight and artificial light may lead in the course of many years to the formation of lens opacities, and further, that since modern artificial illuminants emit light comparatively rich in ultra-violet rays, the use of these illuminants may tend to cause

cataract. No evidence of any real value has been brought forward in support of this suggestion, and until such evidence is forthcoming it would appear as reasonable to avoid sunlight because one can blind oneself by looking at the sun, as to avoid the use of certain lamps because they give light of a character which can be made to produce lens opacities under certain absolutely abnormal conditions. Birsch-Hirschfeld found no changes in the lenses of the rabbits repeatedly exposed, as above described, to the light of a mercury vapour lamp. He also examined, and found no lens changes, in the eyes of a number of workers in the testing room of an arc lamp factory, who wore protective glasses which did not exclude all ultra-violet rays.

C. *Effects upon the retina.*

Birsch-Hirschfeld[8] observed chromatolysis in the nerve cells, especially the ganglion cells, after exposure of the eye to intense light. Complete degeneration of the cells was produced if the illumination was very intense or prolonged. Similar but not quite identical changes were produced by sunlight and by electric light. In aphakic eyes retinal changes were produced by concentrated ultra-violet light alone, but if the lens was present such changes were produced only by mixed light, containing luminous as well as ultra-violet rays. Owing to the high power of absorption of ultra-violet rays possessed by the lens, very few of those rays can reach the retina in the normal eye, and there can be little doubt that luminous rays play a large part in the production of the retinal lesions caused by exposure to intense light. Best[9] found that he could safely look for ten seconds directly at the midday sun in summer through a blue uviol glass, which cut off a large proportion of the luminous rays, but transmitted all rays of wave length between 405 $\mu\mu$ and 332 $\mu\mu$ and a considerable part of those of shorter wave length. After the exposure he

saw a yellow after image of the sun for a few minutes, but this was not sufficient to prevent him reading. On the other hand he found it impossible to fix the sun, even for a fraction of a second, when looking through a yellow glass which cut off all ultra-violet rays.

Erythropsia is an interesting functional disturbance attributed by Fuchs and many others to the action of ultra-violet rays upon the retina. The principal evidence in favour of this view is that it occurs most readily in aphakic eyes, in which, owing to the absence of the lens, a higher proportion than usual of ultra-violet rays reaches the retina; that it is very apt to occur after exposure to snow glare on high mountains where the light is very rich in ultra-violet rays; and that it can be excited, according to some observers, by exposure to the light of a uviol mercury vapour lamp, but does not occur if a screen of smoke-tinted or even plain glass is interposed. An obvious criticism of this last observation is that the cornea and lens already protect the retina from the rays cut off by plain glass. That erythropsia is not necessarily due to the action of ultra-violet rays is shown by some experiments of Best.[9] He spent a day on a snow mountain with one of his eyes under homatropin and cocain, but protected by a yellow glass which absorbed practically all ultra-violet rays. Nevertheless erythropsia resulted in that eye. Another day he repeated the experiment under similar conditions, but protected the eye with a blue uviol glass, which transmitted a large proportion of ultra-violet rays, but absorbed a large part of the luminous rays. Under these circumstances he did not get erythropsia. Vogt found that erythropsia could be excited by exposure to the light of a uviol mercury vapour lamp even when a screen was used which cut off nearly all ultra-violet rays.

Cases of disturbance of colour vision following exposure to intense light have been recorded by Best[10] and Birsch-Hirschfeld;[11] by the former in a case of snow

blindness, by the latter in five cases of men who had worked for a long time under brilliant illumination from mercury vapour lamps. The symptoms observed in these five cases were slight chronic conjunctival irritation, and a disturbance of the colour sense, generally in the form of a pericentral scotoma for red and green, shewing a predilection to occur in a lower sector of the field of vision 15°—20° from the fixation point.

Reviewing the evidence to hand, one is led to the conclusion that all the rays which reach the retina may play some part in the production of the disturbances resulting from exposure to intense light. It seems, however, that such disturbances are more liable to occur when the light contains a high proportion of rays of short wave length. And since the photo-chemical activity of the rays is inversely proportional to their wave length, it is not improbable that the blue, violet, and few ultra-violet rays which reach the retina are most active in causing damage; but the action of rays of greater wave length cannot be regarded as negligible.

Among the general public there is a very widespread idea that the use of electric light is bad for the eyes, and one is often asked by patients if it is so. In the writer's opinion there is no evidence whatever to show that any serious injury to the eyes need be apprehended from the use, under ordinary circumstances, of any form of electric glow lamp. The arc lamp must, of course, be used with caution, and Birsch-Hirschfeld's cases show that some protection of the eyes is desirable for those who have to work under brilliant illumination from mercury vapour lamps. But although no serious injury is to be feared, there is no doubt that many people suffer some discomfort from the use of ordinary electric light, especially when metal filament lamps are used. It is possible that the smarting and burning in the eyes sometimes complained of may be due to the high proportion of ultra-violet rays emitted by these lamps; but most of the

discomfort experienced, especially retrobulbar pain and headache, when not due to errors of refraction, is caused by excessive brightness or bad arrangement of the lamps. Violent contrasts in the retinal image are always apt to cause discomfort. When a lamp is so placed that its rays enter the eye directly, the contrasts are extreme between the image of the filament, the much less brilliant but still very bright image of a page of white paper or other light object, held in the full light of the lamp, and the relatively feebly illuminated images of other objects in the field of vision. The discomfort felt under such circumstances is doubtless due to imperfect adaptation of the eye to the illumination of the brightest parts of the retinal image, and of similar nature to that felt on emerging from a dark room into bright daylight. In order to prevent discomfort from this cause, the lamps should be so arranged, or shaded, that light cannot enter the eyes directly from them. If this be impossible, the light should be diffused by the use of ground glass globes, or other suitable means, and several lamps of comparatively low candle power used rather than one or two of high candle power. When a reading lamp is used on a table, the rest of the room being dimly lighted, it is important that the lamp should not be unnecessarily powerful. It has been found by trial that one can read easily with an illumination of one candle-foot, *i.e.*, the illumination given by a lamp of one candle power at a distance of a foot. If the illumination exceeds six candle-foot it is liable to cause discomfort.

References.

1. Schanz and Stockhausen. *Arch. f. Ophth.*, lxix, 1908, p. 49.
2. Birsch-Hirschfeld. *Arch. f. Ophth.*, lxxi, 1909, p. 573.
3. Widmark. "Mitteilungen aus den Augenklinik zu Stockholm," 1901 (cited by Birsch-Hirschfeld, *Zeit. f. Aug.*, xxi, p. 386).

4. Hess. *Arch. f. Augenheilk.*, lvii, 1909, p. 185.
5. Schanz and Stockhausen. *Arch. f. Ophth.*, lxix, 1909, p. 452.
6. Birsch-Hirschfeld. *Zeit. f. Augenheilk.*, xxi, 1909, p. 385.
7. Schanz and Stockhausen. *Arch. f. Ophth.*, lxxiii, 1909, p. 184.
8. Birsch-Hirschfeld. *Arch. f. Ophth.*, lviii, 1904, p. 469.
9. Best. *Klin. Monatsbl. f. Aug.*, xlvii, 1909, p. 520.
10. Best. *Klin. Monatsbl. f. Aug.*, xlv, 1907, supplement.
11. Birsch-Hirschfeld. *Zeit. f. Augenheilk.*, xx, 1908, p. 1.

REVIEWS.

George Lenz. **On the Pathology of the Cerebral Visual Tracts, with special reference to its bearing on Anatomy and Physiology.** *von Graefe's Archiv für Ophthalmologie*, lxxii. Part 1 and part 2.

This paper of Lenz's is in itself mainly in the nature of a long review of the present condition of our knowledge of the course taken by the visual fibres from the chiasma to the higher visual centres and their distribution there. He bases it mainly on the evidences produced by pathological conditions, and though the author cites new cases and observations of his own the bulk of the paper is in the nature of a review and does not readily lend itself to further abstracting.

He first discusses the conditions in which homonymous hemianopia occurs. He finds it in about 16 per cent. of cases of brain tumour, in 35 per cent. of cases of cerebral hæmorrhage, in 51 per cent. of cases of cerebral softening. Incidentally he finds that cerebral hæmorrhage is less likely to give rise to a double sided lesion than cerebral softening. In this connection he discusses the hemianopia of migraine and considers that the indications point to its being of vascular origin. Of inflammatory changes, the one likely to give rise to hemianopia is cerebral abscess. Encephalitis rarely does so. Syphilitic gummatous basal meningitis is the form most likely to give rise to hemianopia. Other forms of meningitis do not usually do so. Though serous meningitis and internal hydro-

cephalus give rise to visual disturbances, these are usually due to pressure of distended ventricles on the basal tracts. He considers that no definite case of hysterical hemianopia has yet been recorded.

An interesting case of quadrantic hemianopia due to a small tumour pressing on and involving the inner surface of the left occipital lobe in the upper part of the visual area is described in full detail.

Lenz next considers the course taken by the visual fibres from the chiasma to the occipital lobe. The majority of the light bearing fibres go to the external geniculate body and from there straight by the optic radiations to the occipital lobe. He considers the functions of the fibres which go to the pulvinar as still doubtful though cases have been cited where a lesion in this neighbourhood led to hemianopia, though the external geniculate was intact. The fibres going to the anterior corpora quadragemina do not play a part in the light bearing function.

As regards the organisation of the higher portion of the visual mechanism he states and discusses the two antagonistic theories which we may call Henschen's and Monakow's. The former regards the macula as having a sharply defined respresentation in the occipital region whilst the latter considers that the primary centres are linked up through numerous tracts with practically the whole visual area of the occipital lobe. To support the first theory what is wanted is a case in which the macular region has been picked out by a cortical defect. No such satisfactory case has as yet been described, whereas it is well known that the macula escapes in many cases of hemianopia.

The most interesting part of the paper is where the author discusses the site of the lesions in which the hemianopic division cuts through the macula and those in which the macula is left free. His conclusions are that, when the hemianopia is due to a lesion of the tract, of the primary centres, or of the anterior portions of the optic radiations, the hemianopia defect will involve the macula, but when the lesion is further back in the optic radiations, behind the internal capsule, then the macula is more likely to escape. This theory involves some communicating tract between the external geniculate and the visual centre of the opposite occipital lobe branching off somewhere behind the region of the internal capsule. A large portion of the paper is devoted to a discussion of the cortical distribution of the visual centres. Of this part it is unneces-

sary to give any detail as it has been admirably dealt with comparatively recently in this country by Mott in his Bowman Lecture. It is interesting to note however that as a result of a review of 58 cases the author has formed the opinion that the cortical representation of the macula is in the neighbourhood of the posterior end of the calcarine fissure.

There are short discussions of hemiachromotopsia, double sided hemianopia, nasal and one-eyed hemianopia, and the conclusion of the paper is devoted to a clinical description of the mode of onset and signs and symptoms which accompany hemianopia.

LESLIE PATON.

MELLER (Vienna). **About Sclerecto-Iridectomy.** *Klinische Monatsblätter für Augenheilkunde*, December, 1909.

THIS paper, which is of considerable length, deals with the results obtained in Professor Fuchs' clinic in twenty-seven cases of glaucoma treated after the manner of Lagrange.

The latter half of the paper comprises a description of the cases, with full details about the history of the illness, the date of admission and operation, the after course of the operation, and present results. The only point worthy of notice in this record of the cases is that among the first seven cases five are the subjects of an acute attack of glaucoma, while the remaining cases all belong to the class of chronic inflammatory glaucoma, or to glaucoma simplex. Important points are summarised at the end of the case to which they belong, and cross references are common between the cases themselves and statements made in the earlier portion of the paper. This earlier portion of the paper is the part I propose to consider more especially in this review, as it forms a critical survey of the results of Lagrange's operation, as obtained in this series of cases, and is full of important points in connexion with the technique of the operation, the difficulties and dangers that may ensue, the complications that may arise, and the indications for operation, and finally, ending, as it does, with a discussion about the value of the operation, it forms a useful contribution to our knowledge.

Meller, in his opening remarks, deplores the fact that though it is three years since Lagrange first published his method of procedure, yet only very scanty reports on a series of cases treated by this method have so far come to hand. In all notices

of the after results of an operation for the relief of glaucoma he says, "we feel the want of a trusty method of estimating the intra-ocular pressure"; small differences cannot, he maintains, be accurately estimated by the finger, and it is impossible to define with certainty the boundary between normal and slightly increased pressure, if we trust entirely to the finger.

The majority of these cases have therefore been treated in the following way: Lagrange's operation has been performed on the one side, and an ordinary iridectomy on the other, and in all cases the intra-ocular pressure has been recorded where possible by means of Schiotz' tonometer. The normal tension of the eye as found by the use of this instrument, which has been found to be very reliable in the clinic of Prof. Fuchs, fluctuates between 15 and 25 mm. of mercury, whereas in glaucoma simplex a pressure of at least 30—35 mm. is present. Meller divides his subsequent remarks under the following headings:—

(1) Details about the technique of the operation.
(2) After results (*a*) The condition of the scar.
(*b*) Clinical efficacy.
(3) Indications for operation.

(1) In the first place Meller points out that, as frequently the conjunctiva in these cases is brittle, and tears away from the forceps in fixation, the most desirable situation for the section cannot always be obtained, and thereby the carrying out of this method is frustrated; he also points out the danger to the underlying ciliary body in performing this very peripheral section, and insists on the fact that injury to the base of the iris can hardly be avoided, especially when an adhesion exists between it and the cornea, and that though the operative treatment of glaucoma is directed against this peripheral synechia, yet that an irido-dyalisis caused in this way may be followed by the gravest consequences, for when we come to carry out the rest of the operation, and insert the iris forceps to draw out the iris for iridectomy, the forceps may pass through this artificial hole, and thereby the lens capsule is in danger of being wounded, as occurred in Case 19 of his own series. Meller is in favour of performing the iridectomy before excising the strip of sclera.

Spontaneous development of cataract may occur, for when so extensive a section is made in a hard eye the high pressure

in the vitreous pushes the lens forward, and it comes into the region of the incision, where the sclera is thinner and less resistant than usual, even if it does not actually reach the opening in the sclera, and the suspensory ligament may rupture: actual tilting of the lens may occur, in which its upper edge turns forwards under the iris, and after the iridectomy, it may be exposed in the wound. In like manner a prolapse of vitreous may occur: this took place in Case 9, where the tension before the operation amounted to 70 mm.

Meller ends his remarks on the technique of the operation by quoting Abadie's remarks to the effect that "sclerecto-iridectomy is a delicate and difficult procedure, which requires an extensive peripheral section, and which exposes the lens and vitreous to the possibility of being wounded"; he points out that these dangers mainly concern the very hard eye, and acknowledges that Lagrange has not proposed his operation as a means of treatment for eyes in which the tension is considerably raised, but rather for cases of glaucoma simplex.

(2) About the condition of the eye after the operation, three points require especial attention—the anterior chamber, the scar, and the intra-ocular pressure.

The chamber remains open in a good number of cases longer than it does after an ordinary iridectomy, as in Cases 2, 14, 25, where the chamber in the eye on which an ordinary iridectomy had been performed was restored on the day following the operation, whereas in the Lagrange eye it remained open for a space of time varying from 2—5 days, and once even for 8 days. In most cases Meller is of opinion that this delay in restoration of the anterior chamber is only a part phenomenon of a simultaneously occurring detachment of the choroid.

The characteristic appearance of the scar is generally a late development; on the day following the operation there is often found an œdematous, transparent condition of the wound, which, however, may not develop for a week or so, as in Cases 16, 17, 21; other cases on the day after the operation offer all the appearances of a filtering scar, while a week later very slight changes are present in the conjunctival flap, as in Cases 18, 19, 22. Meller finds in his series twelve examples of pure thinning of the sclera, eight examples of subconjunctival fistula, and twelve examples of an ampulliform œdematous bulging of the flap.

The kind of scar depends upon the kind of operation, the carrying out of the section, the spot where the excision of the

strip of sclera is performed, and the amount excised, and it has very little to do with the degree of raised tension in the eye.

Meller is unable to agree with Lagrange, when the latter looks upon the ampulliform scar as a simple bladder in open communication with the anterior chamber.

Meller's fifth case is that of a patient who developed a cataract after Lagrange's operation, in whom the scar was of a typical ampulliform kind; in the operation for extraction of the cataract Meller first separated the conjunctiva above the limbus from the globe; he found that the bladder-like conjunctiva was very firmly connected with the underlying tissue, so that he could only separate the two with difficulty, the tissue in the region of the scar was as hard as cartilage, and positively grated on the scissors as he was dissecting the flap up, preparatory to performing his cataract section; he is therefore of opinion that the ampulla is no true bladder, but that it is formed of solid tissue, possibly of a hyaline nature, and he points out that it is rigidly limited to the conjunctival flap.

In speaking of the condition of the intraocular pressure after the operation, Meller is well aware that his observations only extend over a short space of time, *i.e.*, 6—9 months. Meller's first point under this heading is that the eye with this ampulliform scar is often found to be abnormally soft, much softer than is ever found to be the case after a pure iridectomy; in Case 6, for instance, where before the operation the tension was 135 mm., he could only measure a tension of 5 mm. in the eye six months later, and the scar was a typical ampulliform one; Case 13 showed a similar though not so marked difference, as also did Cases 7 and 10.

From this Meller argues that after a Lagrange's operation the intraocular pressure is not only considerably diminished, but that it is diminished to a greater degree than after a pure iridectomy; he goes on to say that the simultaneously performed iridectomy hinders the correct estimation of the value of the sclerectomy; in Case 10, in an eye which had been the subject of a pure iridectomy previously for glaucoma, an increase of tension recurred, simple sclerectomy was performed, and the tension came down from 55 mm. to 20 mm., as opposed to a tension of 30 mm. in the other also iridectomised eye. The operation, however, even when leading to a typical ampulliform scar, occasionally is unsuccessful in preventing the malignant course of glaucoma, as is shown in Case 5.

Meller next goes on to speak on the subject of choroidal

detachment; he has altogether eight cases of choroidal detachment out of thirty-six operations, *i.e.*, 22 per cent.; he has no instance of its occurring in pure sclerectomy. The cases where this state of affairs came to pass were as follows. Glaucoma chronic inflammatory with tension 70 mm., the other eye with tension 55 mm. showed no detachment, an acute glaucoma with tension 111 mm., the other eye with the same tension had no detachment, a chronic glaucoma with tension 65 mm., and a bilateral detachment in a case of glaucoma simplex with tension 55 mm. These cases are 4, 7, 9, 17, 21, 24, and one other case is also cited. Case 9 was complicated by prolapse of vitreous, but in all the other cases the course of the operation was normal.

Fuchs puts the occurrence of detachment of the choroid in pure iridectomy at 10 per cent.; Meller's series gives 22 per cent.; the course of the detachment is in no way different from that described by Fuchs as occurring in simple iridectomy. How soon after the operation detachment occurs cannot be definitely settled; in Case 24, in which on the day following the operation the chamber was restored, a large detachment was found on the fifth day; in Case 21 it was found at the end of a week, though the chamber was restored on the second day; he is of opinion that those factors which delay the restoration of the anterior chamber, viz., the excision of the strip of sclera, also tend to produce a choroidal detachment.

In Case 17 an examination with the mirror was undertaken from the day following the operation: in the left eye a detachment was discovered on the fourth day, though it was first seen in the right eye on the third day; this detachment was a large one, and yet had disappeared in eleven days' time; in another case detachment discovered on the fourth day had disappeared six days later, and in two other cases it was found on the second day, and had disappeared by the tenth.

Meller sums up as follows: the time for detachment to occur is when the eye is soft, and when the development of the new scar tissue is taking place; his cases of detachment all occurred in eyes with typical ampulliform scars.

(3) Indications for operation. In the first place in a very hard eye the operation is difficult, and tends to lead to complications, and as we know that in acute glaucoma the simple iridectomy usually acts efficiently, this operation is contraindicated; on the other hand sclerectomy simple, or combined with iridectomy, is a simple procedure in eyes with not too

shallow a chamber, with contracted pupils, with slight rise of tension, which are free from irritation.

Since in glaucoma simplex an iridectomy is almost incapable of permanently delaying the course of the disease, a trial should be given to the operation of Lagrange.

As a special indication Meller now comes to those cases where increase of tension sets in after a simple iridectomy has been performed; here he thinks that Lagrange's operation is preferable to a further iridectomy, as it does not enlarge the size of the coloboma, and it leads to a more lasting diminution of pressure.

In cases of absolute glaucoma a non-perforating sclerectomy, such as occurred in Case 3 where an intralamellar section was made with a Graefe knife, gave excellent results. Meller ends the first part of his paper as follows: "when through such an operation as sclerecto-iridectomy we succeed in making an end of the most dangerous symptom of glaucoma, viz., the rise of tension, without danger to the eye, so are we justified in including the same among the operative measures at our disposal in properly selected cases."

In conclusion, I think Meller is to be congratulated on his exceedingly able and instructive paper and on his results. The paper forms a valuable contribution to our knowledge on this subject, and all interested in the operative treatment of glaucoma would do well to read it.

R. R. James.

Jackson (Denver, Colo.). **Recent observations concerning Glaucoma.** *The American Journal of Ophthalmology*, Dec., 1909.

In this paper Jackson brings under review the recent work that has been done, chiefly clinical and operative, on the subject of glaucoma. He draws especial attention to the relation the blood pressure bears to glaucoma, and quotes cases in which either a rise in blood pressure coincided with an attack of glaucoma or some factor which might cause a rise of blood pressure was apparently the determining factor in precipitating an attack. These factors fall in with the observations that glaucoma arises in the eyes of those who have the peculiar anatomical features which predispose to glaucoma following excitement, distress or the exposure to cold. As confirming this latter factor, acute glaucoma is found to be more common in the autumn and

winter when a rise in blood pressure may be assumed from the contraction of the peripheral arterioles following exposure to the fall in temperature of these seasons.

Attention is drawn to the frequency of glaucoma affecting eyes the subject of thrombosis of the central vein when the intra-ocular blood pressure must be greatly increased, and the cases reported of glaucoma following the local application of adrenalin.

The relation of the blood pressure to glaucoma is the basis of conservative treatment in acute glaucoma when use is made of blood letting, fomentations, purging, and the inducement of sleep, all of which tend to reduce the pressure in the vessels. He mentions a case in which the diagnosis of glaucoma in the presence of an intra-ocular growth was assisted by finding no rise in the general blood pressure.

There is also reference to the recent paper of Fuchs on glaucoma following perforation of the cornea, showing the base of the iris adherent to the cornea and also to the use of the transilluminator in showing narrowing of the circumlental space in eyes predisposed to glaucoma.

In secondary glaucoma, especially in irido-cyclitis, the presence of solid particles in the meshes of the spaces of Fontana has received corroboration, experimentally, by the production of solid particles in the anterior chamber after electrolysing pieces of steel placed there, and by the presence of particles of lens matter after the production of a traumatic cataract (Erdmann, Raehlmann).

In discussing the various operative procedures, especially those of Herbert, Lagrange, and the operation of cyclo-dyalysis, he points out that all these "weaken the thicker ring of corneo-scleral tissue at the region of the limbus and tend to permit an enlargement of the eyeball at the ciliary ring," and that if Priestley Smith's view of the progressive growth of the lens be a factor in producing glaucoma, then any operation which tends to enlarge the circumlental space will be of advantage.

He also suggests that an explanation may lie in the formation of new vessels in the region of Schlemm's canal and thus the establishment of a new connection between it and the vessels within the globe. And here, following Thomson Henderson's observations on the sclerosis of the tissues in the region of the angle of the anterior chamber, the new vessels by furnishing a venous outflow will be of assistance in reducing the blood pressure within the globe. C. B. Goulden.

A. Dehenne. **The Measurement of the Visual Acuity from the point of view of industrial accidents and fitness for public service.** (New decigrade optometric scale). *La Clinique Ophthalmologique,* Nov. 10, 1909.

The purpose of the new scale is to obtain results which shall always be comparable, in order, firstly, to do away with the unseemly discussions in the law courts in connection with industrial accidents (which discussions arise usually from the diverse scales used by the medical witnesses), and, secondly, to classify more accurately those persons with normal vision of varying degrees.

To effect this, Dehenne has established a new optometric decigrade scale—based upon the size, in microns, of the retinal image formed at a certain distance, viz., 5 metres—but capable of being used at other shorter distances to suit the examiner's convenience, *e.g.*, 4 m., 3 m. and even 2 m., because the size of retinal image is constant since the scale is calculated according to the tangent of the angle formed by the different rays. He has taken for his starting point the tangent of an angle of 5′ with a ray of 5 metres, and the 0° of the scale is taken as the case where the eye can tell but dimly his 73 mm. letters at 5 m., a visual acuity, according to the law, useless for work. The retinal image in this case would be 220 microns. The 5° is where the 36·5 mm. letters are just seen—retinal image 110 microns. The highest visual acuity is his 10°—corresponding to the $^{11}/_{10}$ths of some other scales. Between these two points —0° and 10°—he has established an exact declination so as to obtain proportional sizes of retinal images. The 0° of his scale corresponds to the $^{1}/_{10}$th of other scales. From 0°—5° is the part concerned with accidents at work, while 5°—10° has to do more with the superior visual acuities necessary for the public services. Tables are given showing the size in microns of the retinal images formed at the different distances by tests of various sizes—and one very striking chart shows the superior accuracy of gradation in Dehenne's scale to that of Monoyer's or even Armaignac's.

He points out that many people at 5 m. read characters a little smaller even than the 7·3 mm. ones which theoretically they should just read. His scale allows of more accurate classification and selection of the candidates for government posts—those with $^{7}/_{10}$ths or $^{8}/_{10}$ths have *good* sight, those with $^{9}/_{10}$ths have *very good* sight, while those who have the 10° have *perfect* sight.

He emphasizes the necessity for employing not only the same test—but the same exact methods of testing—as regards a rational height for the test, constant intensity of illumination at a constant distance from the test, and the maintenance of the proper distance between the observed eye and the tests.

He himself uses an incandescent electric lamp—110 volts—filament horizontal—encased so that a ray of light falls on each successively appearing line—without any direct light reaching the observed eye. This lamp is placed 15 cm. from the test. Directions are given for the use of gas-light. In testing the superior acuities the person must not bend forward at all because this alters markedly the size of the retinal image. Counterproofs can be made by the tests for other shorter distances than 5 m., and the results should correspond. He does not, however, attempt to explain away the objections raised by Landolt and many others to the testing of the visual acuity at distances less than 5 metres. The influence of the accommodation is not mentioned.

In a somewhat humorous way he advocates the metrical system of stating the visual acuity.

While many will agree with the author that the scales in use are often unsatisfactory, it is doubtful if even now we are much nearer perfection.

No details are given as to the nature of the types used, nor is their possible source of supply indicated.

W. C. Souter.

Dr. Charles Roche. **A Clinical argument in favour of the Helmholtz theory of Accommodation.** *Receuil d'Ophthalmologie*, October, 1909.

The writer of this paper first summarises the theories of Helmholtz and Tscherning, and concludes that, if we judge the former to be correct, we must regard the lens as never being in a state of rest; whereas, according to Tscherning, the refraction of the lens is altered by a change of shape from the normal state of rest brought about by the contraction of the ciliary muscle; and, therefore, if the zonule be cut, the shape of the lens ought to remain the same. On the other hand, if the lens is kept in a given state of curvature by the suspensory fibres, the severance of the latter will release its constraining influence, and the accommodative power of the lens would then be considerably increased.

Dr. Roche proceeds to describe in detail the case of a child of eleven years old, who had double dislocation of both lenses upwards and outwards. The refraction in the aphakic area was +11 D, and in the lenticular area −13 D; therefore the myopia is caused by the lens. Now, it is at once apparent that that 13 D. exactly represents the refractive change produced by a child in making a forced effort of accommodation, and the loss of attachment of the lens leaves it free to expound to its full extent, if Hemboltz's theory of accommodation be the correct one.

Dr. Roche explains the fact that this difference in refraction is not found in all cases of sub-luxation, by saying that the presence of a majority of the fibres remaining intact prevents the lens from assuming its maximum degree of curvature.

MALCOLM L. HEPBURN.

W. KOSTER (Leyden). **The Establishment of Permanent Drainage between the Lachrymal Sac and the Nasal Cavity.** *von Graefe's Archiv für Ophthalmologie,* lxxiii, 1.

THE present paper is supplementary to one published by the author in 1907, since which time he has simplified the technique of his method of operation and has increased his experience of its value. His earlier paper was reviewed in this journal in May, 1908, (xxvii, 151). As he points out in it, the difficulties in the way of treatment of lachrymal obstruction and chronic abscess of the sac lie not so much in the virulence of the disease or the nature of the organisms, but rather in the mechanical difficulty of access to the parts chiefly affected. Koster's aim has been by some means to establish a permanent drainage route from tear passage to nose. But how is this to be accomplished? The hollow styles of lead he disapproves of, Schweigger's gold ones might be less open to objection, but he never had any real success with them. His own plan is to get a thread of silk placed in the canal, by which he hopes to drain the passage, and this, though a somewhat difficult manœuvre, he accomplishes by various little devices. Details of these are given in his earlier paper; besides other plans he even tried attaching a small needle to the thread, letting it slip down the hollow sound as far as possible and then extracting it further by means of Haab's magnet introduced into the nose. The chief disadvantages of Koster's plan of treatment seem to consist in

the difficulty in the introduction of thread of silk, for the inferior end of the nasal duct is invisible in the nose and is hard to find; and the deformity caused by the visible presence of the thread upon the face.

To avoid the troublesome process of hunting in the nasal cavity for the thread the following ingenious plan was suggested to him by a friend and was found to succeed fairly well. The thread is impregnated with gum arabic, and sufficient length of it introduced through the hollow probe very slowly and carefully, so as to leave about 10 to 15 cm. lying in the meatus of the nose; in contact with the nasal secretion the thread quickly becomes quite soft and flaccid; the patient then, holding the other nostril closed with the fingers, expels the air sharply and vigorously through the affected nostril, when the thread springs at once into view. If this little manœuvre is to succeed, it is essential that before the hardened thread is introduced the hollow sound should be withdrawn a little way, and that the introduction of the thread should be carried out very gently and slowly; if this is not attended to what happens is that the thread does not become sufficiently softened, but remaining too wiry may find its way backwards to the throat and can then not be "blown" to the anterior opening of the nose. Should this happen it could even be secured with proper forceps, but that is an unpleasant procedure and not desirable. This original stiffened thread may be used as itself the permanent drain, or it may be attached a double, not-gummed, thread, which is pulled through by the aid of the first and left in position; this latter plan is preferred by Koster.

With the results obtained by this drainage method Koster continues to be well pleased, and he rarely has recourse now to excision of the sac. One advantage which he claims is this that since the inflammatory products are constantly drained away, the mucous membrane lining the duct returns to a more normal condition, and there is none of that periodical destruction of it by the rude passage of a probe which in his opinion and in that of the reviewer is so injurious and so inimical to a sound result.

According to circumstances, the severity of the original affection, the social status and the attentiveness of the patient, etc., it may or may not be necessary that he should pay frequent visits to the surgeon, be admitted to hospital or simply douche out the nose and keep the thread clean. The author admits frankly the serious disadvantage under which his method labours, viz., that the thread must lie, visible to all, upon the patient's cheek,

and he rather resents the criticisms to which this circumstance has given rise; many writers in commenting upon his method adding, "In this country this defacement would be objected to out and out." But too much may be made of this objection, which, indeed, does not accord with Koster's experience; and if the patient has before him (1) wearing a thread visible on the face for a short time, but no pain, (2) repeated painful, futile, and costly probings, and (3) excision of the sac, with all its attendant evils, real and imaginary, he will not unlikely decide for Koster's satisfactory, if for a brief time inelegant, method of cure.

When the case is an acute one, Koster's first procedure is to apply dressings of bichloride of mercury (1—3000) until the swelling and congestion are reduced, which in his experience occurs very quickly under this application, and he then, without waiting for complete resolution, introduces the thread.

In cases in which there is an impermeable stricture Koster is guided by his experience of an occurrence which took place some time ago: he had a patient in whose case there was a false passage leading from the lachrymal sac over the inferior turbinated bone into the middle meatus: eventually the proper channel was opened into, but the case suggested to him the propriety in such circumstances of intentionally establishing an artificial communication when the normal passage was completely stenosed. Through this passage he introduces his thread, which ensures that it shall remain open while the passage becomes lined with mucous membrane which pushes in both from above and from below, thus establishing a permanent channel.

At the close of his paper Koster gives details of a number of cases of dacryocystitis of various degrees in which his thread operation has proved highly beneficial.

W. G. S.

E. Mayer. **A Memoir on the Prescriptions for Spherical Lenses.** *Annales d'Oculistique*, Nov. 1909.

The glasses of spectacles are intended to be worn at a distance of about 15 mm. in front of the cornea. But patients can not always be persuaded to conform to this rule, as some wish to see over the glasses, others under them. For this purpose the former wear them at a greater, the latter at a less distance from the cornea. There are, in addition, those who wish to avoid

the rubbing of their lashes against the glasses. The skin is so sensitive in some people that they can only support their pince-nez towards the end of their noses. In these cases the vision procured by the glasses is not the same as was anticipated when the prescription was given.

The principle object of Dr. Mayer's article is to solve two problems: (1) A lens being made according to a prescription, between what limits of distance from the eye may it vary without sensibly changing the vision? (2) If it is necessary to exceed this limit, in what degree must the original prescription be modified?

Prescriptions as a rule only state the strength of the lens required. But besides the power there are three other factors which may influence the vision. These are: (1) The nature of the curvature of the two faces of the lens. (2) The dimensions of the lens. (3) Its refractive index.

Dr. Mayer also studies the influence of these factors in the execution of prescriptions. The memoir is divided into three parts. The first aims at clearly expressing some definitions and formulas concerning thick lenses. The second studies the question in reference to thin ones, whilst the third part contains the complete study and connects it with thick lenses.

The distance of a glass from the eye being difficult to measure, the solution of these problems, as Dr. Mayer remarks, is chiefly of scientific interest, but if some day a precise method is indicated of measuring the distance of a lens from the eye, then the formulas which Dr. Mayer has calculated and tabulated will prove of practical utility.

E. M. Lithgow.

Dr. W. Nicati (Marseille). **Physiologie Oculaire, Humaine et Comparèe, Normale et Pathologique.** 1909.

It is not possible to do much more than record the publication of this work of Dr. Nicati's in the *Ophthalmic Review*. The book contains more than 600 pages, and treats of the whole subject of the physiology of the eye in all its ramifications, ranging from the luminous organs of infusoria worms and myriapodes to the functions of the cortical centres in man. The first half of the book deals with the optical matters of emission of light, refraction, and sensation.

The second half deals with what Dr. Nicati terms mechanics, viz., all the movements not directly related to the contact with

light, such as formation and repair, nutrition, circulation of lymph, and blood, tension, accommodation, pupillary movements, and the movements of the globes, the eyelids, and the tears. In all these divisions the phylogeny and pathology are included, and many original observations of Dr. Nicati are recorded, of which some have not been hitherto published.

A work of this description must necessarily contain much that is common knowledge and belief in the ophthalmological world, but the book is very far from being merely a compilation of what is known at present of ocular physiology. It expresses decided opinions upon many points which are as yet matters of contention among physiologists, and in every portion of the book the work of an original thinker and investigator is evident.

Mention may be made of two points upon which Dr. Nicati advances views more or less strongly opposed to those of other writers.

First as regards the choroid, he holds that among its other functions is to be included that of regulating the intra-ocular pressure by means of a tensor muscle, which acts antagonistically to the pressure of the blood, and which is supplied with an innervation of its own. In the anatomical description of this muscle he follows Muench.

Again in the mechanism of accommodation Nicati divides the "so-called" ciliary muscle into two parts with antagonistic functions. The posterior which by its contraction actively focusses the eye for near object, the convexity of the lens and more especially of its anterior surface being apparently due to its natural elasticity, and the anterior muscle, which by its contraction flattens the curves of the lens, and thereby focusses the eye for distance. One argument that he urges seems rather a piece of special pleading and it is stated in the form of a question—Where else is there a muscle whose function is not antagonised by that of some other muscle? Forgetting apparently that he has himself described one in the tensor of the choroid, to which we can hardly assign an antagonist in the walls of the cardiac ventricle. Besides the interest of the work for scientific ophthalmologists there is much to attract the practitioner, more especially in the pathological portion.

J. B. S.

BEAUVOIS. **Vertical and Oblique Hand-writing.** Congress of the French Ophthalmological Society, 1909.

FOR upwards of thirty years the relative merits of the upright and the slanting script have engaged the attention of authorities in school hygiene, both from the point of view of the production of crooked spine and of the development of myopia. In 1891 the Paris Ophthalmological Society reported in favour of the vertical method, Javal being one of its leading advocates. It does not seem to have been generally adopted, and about 1906 fresh efforts in the same direction were made, but in 1908 the alternative slanting script was defended in a paper by Péchin and Ducroiquet.* The copy-book, they say, should be placed obliquely on the desk, and the pupil should sit square to the desk with both elbows on it, using his right elbow as a fulcrum as his hand moves along the line. The present paper takes the other side. According to it the copy-book should be placed square with the edge of the desk. It is claimed that with this method there is less tendency to bend the head to one side and therefore less tendency to sit with the body twisted. Moreover it is denied that with the usual practice of oblique writing both elbows are on the desk. For more often, it is said, the right elbow is poked into the side and the head falls forward—the familiar position so well known to medical inspectors of elementary schools. A further argument is adduced that with the copy-book sloping upwards the head must necessarily be twisted to the left in order that it may be square with the line of writing. To the reviewer this argument appears unsound. A child's attention is usually occupied with each letter during the time that he is writing it, and with copy-book and script both slanting each letter will be about vertical and therefore there will not be any reason why the head should be twisted. After all, the question is one that is not to be decided by theory but by observation and practice. That method is best which makes it easiest for the child to sit with his head upright. Even with a good method prolonged writing lessons are tiring, and you cannot induce a tired child to sit up when you are not looking at him whatever method you employ. The method of writing is only one of several subjects which must be considered by the school hygienist in relation to the production of school myopia. Perhaps the most important is the timely correction of astigmatism.

A. H. T.

* *v. Ophthalmic Review*, February, 1909.

W. Stock. **On the Application of Wright's Opsonin-technique in Ophthalmology, especially in regard to tuberculous disease of the eye.** *Klin. Monatsbl. f. Augenh.*, Nov., 1909.

This paper consists of an introduction, which deals with Wright's theories, and methods of treatment, the relation of opsonins to immunity, and some of the views which have been expressed on this subject. Afterwards in Part I, the writer describes an investigation he has made in a number of cases of disease of the eye, treated with tuberculin under opsontic control. Part II is concerned with a method of diagnosis based upon Wright's observation that local stimulation may affect the opsonic index to the organism with which the individual is infected. Stock considers that, whatever the value of Wright's method of treatment in disease of other parts of the body, it has been assumed on insufficient evidence that this method is essential, or even desirable, in ophthalmology. He points out that those ophthalmologists who have emphasized its importance most strongly, seem to be those who have had little or no practical experience. With the object of further investigating the matter, he first spent some time in Wright's laboratory, a course he advises all who are interested in such researches to follow. He at first met with some difficulty in his attempts to obtain reliable results, but was satisfied after some time that, precautions being taken against subjective influence, his margin of error did not exceed that claimed by Wright.

Part I: opsonic charts are given of a number of cases treated with small doses of tuberculin. The tuberculous nature of the condition was proved by varied evidence. The index is shown on the charts to be generally raised after the injections. In spite of this, the conclusions of the writer are unfavourable to the method. He has the impression that more satisfactory clinical results were obtained when larger doses of tuberculin were given. Comparing the clinical course of the disease with the index, he finds little or no connection between a high index and progress towards cure; indeed in one case not until a very irregular index followed an increase of the dose was any improvement noted. He advises that treatment be regulated by the effect on the patient, and the course of the disease, and pronounces the verdict that, "The opsonic index proves of no value as a guide to treatment in tuberculous disease of the eye."

Part II contains a series of charts showing the effect on the opsonic index of irritation with a solution of dionin of eyes

affected with tuberculous disease. The charts certainly show marked fluctuations of the index, following the instillation, in cases almost certainly tuberculous. Stock claims for the method the advantage that it proves the tuberculous focus to be actually in the eye irritated, which is only an assumption when the usual means of diagnosis are employed. He is satisfied of the value of the method, but considers its general application improbable owing to the labour entailed.

B. B. Wedd.

THE OPHTHALMOLOGICAL SOCIETY OF THE UNITED KINGDOM.

Thursday, March 10th, 1910.

The President, Dr. G. A. Berry, *in the Chair.*

Card Specimens.

Retinal Disease with Massive Exudation and Detachment.—Mr. J. B. Lawford.

Arthur H., aged 20, came complaining of failure of sight in the left eye for about 18 months, and the same in the right for the last six months. The vision was counting fingers at about 12 inches in both eyes, though less distinctly in the left than the right. Ophthalmoscopically in the right eye there were fine dust-like opacities in the vitreous. Some very dilated and tortuous vessels (? veins) were seen in places, and in the upper part of the retina were innumerable small yellowish flecks and areas of more extensive exudation. Large massive exudates were situated in the upper and temporal quadrants, and some also in the lower, though not so clearly visible; the upper retinal vessels were nearly normal, and in parts the exudate followed the course of the vessels. In the left, the ophthalmoscopic changes were of a similar type but not so distinctly seen, and there was one large area of exudate on the nasal side. In the extreme lower periphery there appeared an opaque grey reflex with a spot of yellow exudate, and on the temporal side was a large fluffy mass. All family and personal history was negative, except that the mother died of "consumption of the brain."

A case of Persistent Mydriasis in both Eyes.—Mr. A. W. Ormond.

E. P., female, aged 41, first seen in June, 1908, came complaining of both pupils being larger than they ought to be. The vision in each eye with correction was $^{6}/_{9}$. The pupils were dilated and fixed, and did

not act to light or accommodation, but there was nothing found to account for this condition. The fundi were normal, there was slight contraction of the visual field, and eserine made no difference to the size of the pupils.

A case of Transient Myosis Associated with Headache.—Mr. A. W. Ormond.

F. L., male, aged 8, came for treatment in January, 1907. The history was that, eight months before, the child had complained of headache, and the parents noticed at the time that the pupil on the right side was very small; several similar attacks followed at intervals of a few weeks; the pupil on the left side was found to be rather more dilated than normal. The attacks consisted of a headache followed in two hours by a contracted right pupil, and after one and a quarter hours the size of the pupil became normal again. There was +1·5 of hypermetropia, and the optic disc appeared, if anything, slightly redder than normal. In all other respects the boy was healthy.

In connection with this case, Dr. Buzzard suggested some temporary paroxysmal blocking such as a small movable tumour, of the third ventricle interfering with the passage of fluid and thus producing a condition of hydrocelphalus for the time.

Oxycephaly with Optic Atrophy.—Mr. E. A. Dorrell.

E. P., female, aged 12, came with a moderate degree of tower skull, with bilateral optic atrophy, and divergent strabismus of the left eye. Instruments had been used at the birth of the child, which was the sixth in a family of eight. The forehead rose steeply to a height exceeding the normal, and a conical growth of bone could be felt at the bregma; the greatest antero-posterior measurement was 16·5 cm., the transverse 13 cm., the byzygomatic 11 cm., and from the glabella to the conical mass 13 cm. The right vision with correction was $^{6}/_{18}$, and that of the left counting fingers. There was no proptosis, no nystagmus, and no limitation of movement; but the optic discs were both pale and the retinal vessels normal.

A Folding Ophthalmic Operating Table.—Mr. Harrison Butler.

The table was arranged to shut up so as to be easily portable; and the price was five guineas. It was simple and cheap and could be cut down to suit the height of the operator.

Congenital Cataracts—Lamellar in the Left Eye, and Approximating to Discoid in the Right.—Mr. J. H. Fisher

This case afforded a connecting link between a lamellar cataract and a discoid cataract. Pedigrees have been produced containing examples

of one kind or the other, but never both varieties in the same patient. E. G., aged 38, female, attended Moorfields, and the vision in the right eye was found to be $^{6}/_{12}$, and in the left $^{6}/_{24}$. The left eye showed a typical lamellar cataract, but in the right was a circular umbra with a fainter perumbra beyond the limits of the first; it appeared to be retro-nuclear, and there were no individual dots, spokes or striæ. Family history negative.

Sub-retinal Hæmorrhage.—Mr. R. Foster Moore.

F. A., aged 46, attended Moorfields, March 5th, 1910, complaining that two days previously a "smoky mist" came over the right eye. There was a specific history dating back 23 years ago, but nothing else discovered regarding the general health. The right vision was $^{6}/_{60}$, and the left $^{6}/_{6}$. In the right eye was a large retinal hæmorrhage involving the macula, near the centre of which was a patch of pigment, almost circular in outline and four or five times the size of the disc, with sharply cut edges.

Persistent Mydriasis in an Eye in which the Lens has been needled for High Myopia, giving rise to Secondary Glaucoma—Mr. Rayner Batten.

In November, 1897, the right lens was needled, and in December, 1905, the tension was +1, and there was glaucomatous cupping with a widely dilated pupil.

Vertically Elliptical Cornea in a case of Old Interstitial Keratitis.—Mr. J. F. Cunningham.

J. L., male, aged 50, attended St. Thomas's on November 8th, 1909. The right cornea showed haziness with new formed vessels, and at the upper end the vertical meridian was inclined slightly outwards in each eye. The retinoscopy in the right showed $\frac{-16D}{-6 \text{ cyl.} \mid \text{vert.}}$ and the left $\frac{-14 \text{ spl.}}{-5 \text{ cyl.} \mid \text{vert.}}$

Papers.

Xerosis of the Conjunctiva and Night Blindness.—Mr. M. L. Hepburn.

The characteristic features of this class of case was described, and the probable cause of the two associated symptoms was discussed. It was suggested that the rays of light during the summer months, when the complaint was most commonly met with, caused a retardation of the

metabolism of the visual purple and also acted on the conjunctival mucous glands inhibiting their action. The two symptoms were closely related, since they simultaneously disappeared whenever a successful treatment had been adopted. Some advocated external remedies alone, while others were convinced of the efficacy of drugs internally without any external application, while bandaging the eyes also caused the disappearance of the xerosis and the night blindness.

Arising out of this discussion, it appeared that there was some reason for thinking that congenital night blindness, xerosis of the conjunctiva and night blindness, and the night blindness of malnutrition might be due to a common cause.

A Contribution to the Bacteriology of Panophthalmitis.—Mr. R. R. James.

Mr. James furnished notes of the case of a man, aged 37, who was admitted in St. George's Hospital on November 30th suffering from what appeared to be orbital cellulitis following injury from wound with a piece of steel. There was marked proptosis of the left eye with intense chemosis; the lids were œdematous and the cornea hazy, but no hypopyon. An exploratory incision was made into the orbit, but nothing was found. A cultivation from the wound showed streptococcus and staphylococcus aureus and albus. Two days later the eye still projected and the conjunctival sac was lined by a complete membrane of a rather tough consistency. On raising the upper lid it was found that the eyeball itself had suppurated and was commencing to discharge through a small opening in the upper part of the globe near the limbus. Evisceration was performed, and the patient made a good recovery.

Very thorough bacteriological investigation was carried out by Dr. Slater, with cultivation of the various micro-organisms found on different culture media, on milk, gelatine, potato, and blood serum; and amongst the others mentioned above was discovered a large gram-positive, immobile, non-sporing, gas-forming bacillus closely allied to the bacillus aerogenes capsulatus. Injection experiments were conducted which showed post-mortem results similar to those found in spreading traumatic gangrene. This is the first case of a gas-forming bacillus causing panophthalmitis described in England; but cases have been published in France, where a similar micro-organism is called the bacillus perfringens.

MALCOLM L. HEPBURN.

A CASE OF CONGENITAL PARTIAL PALSY OF THE THIRD NERVE WITH CYCLICAL CONTRACTION AND DILATATION OF THE PUPIL.

By J. V. Paterson, F.R.C.S. (Edin.).

Assistant Ophthalmic Surgeon, Royal Infirmary, Edinburgh, Surgeon, Eye, Ear and Throat Infirmary, Cambridge Street, Edinburgh.

The patient, a girl of four years, was seen on December 4th, 1909. Her parents were anxious to have advice regarding a drooping of the right upper lid. The condition was said to have existed since early infancy. The child was bright and healthy, and there was nothing in the family history which threw light on the origin of the malady.

Present Condition.—There is evident but not marked right-sided ptosis. By a voluntary effort the child can raise the lid to an extent which almost hides the defect. The upward movement of the right eye is very defective, but movements in other directions appear quite normal. The child has a habit of tilting the face upwards and inclining the head a little towards the left.

The rhythmical change in the size of the right pupil is very striking when attention is drawn to it, but in the examination of a rather too lively and restless child the pupillary phenomena might easily escape the observer's notice. The whole cycle of events from one period of maximal contraction till the next takes usually about 30 to 40 seconds, but is subject to considerable variations. These variations appear to be partly due to the fact that the child's attention is very difficult to fix, and that by changing the point of fixation she introduces disturbing factors into the ocular innervation. The size of the pupil when in the stage of fullest contraction is about

$2\frac{1}{2}$ mms., and when in the stage of fullest dilatation 5 mms. Extreme contraction or dilatation is not reached at any stage of the cycle. On looking closely one sees that as the pupil dilates or contracts the movement is not continuous but rather wave-like or oscillatory. Contraction, when reached, is maintained for only a very brief period (1-2 seconds), while the stage of dilatation lasts a very much longer time. The cycle of events is easily disturbed by such factors as an effort of accommodation, or convergence, or by light stimulus. While the pupillary contraction in response to any of these stimuli was easily noted, yet one found it very difficult with so young and restless a patient to say which of these factors had the strongest influence and at what part of the cycle the response of the pupil to stimulation was most prompt. The consensual light reflex from the other eye was readily elicited and appeared to produce much the same effect on the right pupil as direct stimulation. The refraction in the phase of pupillary dilatation was almost emmetropic, while during the phase of greatest contraction a very marked myopia could be noted by the shadow test. The change in the refraction began suddenly just as the phase of greatest contraction was reached, and its duration was extremely short (2 or 3 seconds only).

The ptosis also varied during the pupillary cycle but the variation was only slight. The difficulty of observation was here greatly increased by the child's inability to keep still, but there was no doubt that a distinct elevation of the lid tended to occur rhythmically just at the moment of extreme contraction of the pupil.

The left eye shewed no abnormalities. Vision appeared to be perfectly good in each eye, and the fundi were normal.

Comments. The case presents the characteristics of a rare but well-known type. The chief distinguishing features of these cases are: (1) Congenital paralysis of

3rd nerve, more or less complete; (2) Peculiar rhythmical changes in the size of the pupil.

Many of the cases described correspond very closely to the one I have noted. In this case the involvement of the 3rd nerve is much less than in the great majority of the recorded cases.

No satisfactory explanation of the condition appears yet to have been given.

In a recent number of the *Klin. Monatsbl. f. Augenheilkunde* (Nov., 1909, p. 582) Dr. Franke, Hamburg, describes carefully two cases of this congenital anomaly which he had recently observed, and gives a summary of other four cases published later than 1901, when Axenfeld and Schürenberg (*Klin. Mon. f. Augenheilkunde,* 1901, p. 64) published an exhaustive paper on the subject.

REVIEWS.

A. Elschnig and H. Ulbrich (Prague). **The Ætiology and Prophylaxis of Post-operative Inflammation in the Eye.** *v. Graefe's Archiv. f. Ophthalmologie*, 72, 3.

The authors have analysed 26 cases of intraocular inflammation occurring in a series of 377 cases of cataract extraction. In 11 cases, which include those of the greatest severity, but in which the symptoms varied considerably in acuteness, "streptococci in the wider sense" (this term including the pneumococcus) are held with considerable probability to have been responsible for the inflammation; the evidence on the point is, however, to some extent conjectural. In the second group of 15 cases, the symptoms, which were for the most part mild in character, but occasionally severe, are attributed to manipulation and chemical irritation, *e.g.*, from lens remnants, an infection being here discounted on quite insufficient evidence. The inflammatory symptoms were frequently not noticeable for several (as many as twelve) days after the operation. No detailed description is given as to the condition of the wound with regard to inclusion of capsule, iris, etc., but in one case (13) the description suggests the presence of lens remnants beneath the conjunctival

flap, while in another case (25) the inflammatory symptoms followed the reposition of a partially prolapsed iris, and in six cases there had been loss of vitreous at the time of operation, a fact which may not improbably have interfered with sound union of the wounds. Ilbert Hancock in Vol. xviii, part 1, of the Royal London Ophthalmic Hospital Reports has described three cases of post-operative infection with prolonged latent period and peculiar course, in two of which a staphylococcus albus was proved to be the exciting cause. The reviewer has met with a case of slowly progressing iridocyclitis following cataract extraction in which a staphylococcus albus was recovered from the aqueous and in which sympathetic ophthalmitis subsequently developed, and other cases in which months or years after an extraction-operation, apparently fulfilling all surgical ideals, a plastic irido-cyclitis of extreme severity has developed in the fellow eye with complete or almost complete absence of symptoms in the operated eye. A consideration of the phenomena met with in such cases as these and of those associated with sympathetic inflammation suggests possibilities with the regard to subacute and latent post-operative infections which are at present little or not at all understood and emphasizes the inadvisability of dogmatic conclusions on any but the most circumstantial evidence as more likely to retard than to promote progress. The question is still further complicated by our lack of knowledge as to the ætiology of so-called idiopathic iridocyclitis and its relation to systemic infection or intoxication, a subject to which Elschnig refers in only the briefest terms.

The method of examination of the conjunctiva preliminary to operation, which is strongly recommended by Ulbrich, consists in the inoculation of serum-bouillon tubes with all the available conjunctival secretion, which is obtained by suction into, and subsequent expulsion from, a long capillary tube similar to that used in the estimation of opsonic indices, the mouth being used for this purpose in preference to a rubber cap. This method revealed the presence in the apparently normal conjunctiva of streptococci (including pneumococci) in no less than 30 per cent. of the Prague cataract patients.

The details given by Elschnig afford a strong argument against the practice, probably very uncommon in this country, of simultaneous bilateral cataract extraction, more especially when performed shortly after excision of the lacrimal sacs.

A. C. Hudson.

PASCHEFF (Sofia, Bulgaria). **On "Chlamydozoa" or "Trachoma-Bodies" and other similar bodies—Epithelial Cell-Inclusions.** *v. Graefe's Archiv für Ophth.*, lxxiii, 175.

PASCHEFF. **Researches on the Nature and Etiology of Trachoma.** *Archives d'Opthtalmologie,* xx, 1, Jan., 1909.

THE first of these papers is brief and to the point, and well illustrated. Two cases of conjunctivitis are related in detail, in which v. Prowazek's and Greeff's trachoma bodies were found plentifully, though the clinical picture was not that of trachoma. This finding is at variance with the experience of the large majority of those who have worked at the subject. The absence of lymph follicles clinically recognizable in these two cases was confirmed by histological examination of excised strips of tissue. The conclusion is that if we are to accept the trachoma bodies as pathognomonic of trachoma, we must accept as trachoma some cases in which the clinical picture is that of acute catarrhal conjunctivitis, and in which the lymphoid infiltration may be quite diffused.

The conjunctivitis in the first case, a woman of 50 years, had lasted five weeks before it was seen by Pascheff. Two weeks' treatment by perchloride compresses and silver nitrate solution sufficed to restore the conjunctiva practically to normal. The second case, in a man of 65 years, had lasted four months before coming under Pascheff's observation. There were some small corneal infiltrations. The effect of treatment is not stated.

The staining solution used for the detection of the trachoma granules was Giemsa R. ten drops, new Giemsa two drops, distilled water 10 c.cm. Pascheff has examined numerous cases of trachoma. In addition to the more minute granules he has seen others somewhat larger and varying in shape—some like diplo-bacilli, others (in one case) pear-shaped and arranged in small rosettes.

A third clinical case is related—ulcus serpens apparently due to the streptococcus pyogenes—ending in panophthalmitis. The whole of the palpebral conjunctiva was scarred by old trachoma. Of special interest in this case was the finding of phagocytosis occurring in the epithelial cells. (The reviewer has found the same in the epithelium of certain conjunctival papules.) In some cells polynuclear leucocytes were found; in others smaller bodies, coloured red, either homogeneous or presenting small deep blue points, suggestive of leucocytes in process of digestion.

Other cells were seen containing quite large dark violet structureless bodies, in some instances so large as almost to fill the cell, flattening the nucleus to one side. Some cells contained examples of both the small and the large bodies. The smaller homogeneous (hyalin) forms have been found rarely, coloured either blue or red, in trachoma, phlyctenular conjunctivitis, and spring catarrh. Attention is also drawn to groups of small granules similar to trachoma bodies, but coloured red, found in cells of the third case related.

The second paper enters rather fully into the histo-pathology of trachoma and other forms of follicular conjunctivitis, including the experimentally induced. A good deal of histological detail is given which has been described better and more fully elsewhere. Attention might well have been concentrated a little more upon contentious matters and fresh observations. It is well recognized that the boundary zone of many trachoma follicles is both incomplete and ill-defined. Pascheff goes a step further in describing, especially in acute trachoma, both large and small follicles without any boundary zone of small lymphocytes at all. These "germ centres" consist mainly of an aggregation of large pale lymphocytes undergoing active proliferation. Pascheff finds no essential difference in structure between trachoma follicles and other lymph follicles, but distinguishes between follicles and "granulations," reserving the latter term for aggregations of follicles, either fused together or not.

He dwells particularly upon the existence in many cases of very small bulbar follicles, distributed at any point between fornix and limbus. The use of the loupe may be required for the detection of these small elevations. He finds follicles in the fornices frequently associated with phlyctenules at the limbus. He affirms a closer connection between follicles and blood-vessels than is generally admitted.

He thinks the existence of a lymphatic diathesis plays a considerable part in the development of trachoma. He has found in many cases of trachoma, in the secretion and once in a section of tissue, a small gram-positive bacillus, frequently in diplo form. It grows readily on common media, and must be regarded as a saprophyte.

H. Herbert.

W. Goldzieher (Budapesth). **The Treatment of Trachomatous Pannus by means of Infection with Gonorrhœal Secretion.** *Weiner klinische Wochenschrift*, xxii., 52.

Since pannus is the worst and most distressing result of trachoma, destroying as it must do the capacity and the efficiency of the eyes affected, the cure of pannus is the crucial point in the therapy of trachoma. It is no doubt to some extent true that pannus being a consequence of trachoma and dependent on it, the treatment of pannus is in reality the treatment of the causative trachoma, but pannus is, according to Goldzieher, an invasion of the cornea by trachoma, an attack upon the cornea by the trachomatous process which has already invaded and partially destroyed the conjunctiva: it is therefore right and proper when this invasion occurs to attack it directly. When therefore recent pannus is to be dealt with this should be along well recognised lines,—destruction of the invading bodies in the cornea by the cautery, destruction of the vessels, atropin, etc.—and the result is generally pretty successful. But far harder to overcome are the cases in which chronic pannus exists —with superficial ulceration, congested iris, curvature changes of the cornea, and what not,—cases which tax the resources of the surgeon, the endurance of the patient, and the patience of both. Where there is also much formation of new vessels the cautery destroying the new-formed vessels is very useful: this may further be accomplished by a species of peritomy, destroying the conjunctival vessels just as they enter the anterior segment of the globe. Here again there may be trouble, for the new vessels communicate not merely with the surface vessels of the conjunctiva, but with those also which lie deeper, and on the whole Goldzieher considers that this line of treatment should not be adopted.

For still more formidable cases, the *pannus crassus* of former days, the Jequirity bean, introduced by de Wecker, has been a good deal recommended and employed. Goldzieher's experience however is that even the vehement reaction, resembling a diphtheritic conjunctivitis, induced by the application of an infusion of the seeds is not quite efficient for the really bad cases and is too dangerous for the less severe, all the more that for such the destruction of the new formed vessels by means of the cautery has in his hands proved of marked benefit. Further, apparently, different samples of the drug have varying efficiency in producing reaction of the nature desired, and to sum up this

matter Goldzieher rejects this method of treatment altogether as too risky for the milder cases and too frequently a complete failure in the really severe.

Turning now to his real thesis Goldzieher gives a brief but interesting account of the origin of the bold method of treatment of pannus by infection of the eye with secretion from a blennorrhœa. This dates from the early years of the nineteenth century, and as at that period the idea of isolation on account of a contagious malady was in its infancy it is more than probable that the first experiments in this direction were involuntary rather than premeditated. The first person deliberately to recommend the treatment appears to have been F. von Jaeger, Chief Medical Officer of the Austrian Army, who recommended it in the most unequivocal terms, in certain suitable cases, and it was spoken of in high terms by Piringer and by Stellwag.

Since that time however the procedure has fallen into disrepute, chiefly on account of the inherent danger involved in the wilful inoculation of the conjunctiva from a blennorrhœa or a gonorrhœa. It has been with some diffidence that even one who has been treating cases of trachoma for nearly thirty years finds himself obliged to recommend this operation for suitable cases.

It is in the first place for cases of pannus crassus, or pannus carnosus, that he has ventured to proceed in this fashion; under this name he includes the cases in which the abnormal vascular trunks in the anterior layer of the cornea lie so close together that iris and pupil are almost invisible, can hardly be made out; in extreme cases the whole anterior layers of the cornea have become like a layer of granulative tissue, and the curvature altered to an ectatic form. There are in these thickened layers numerous small superficial ulcers, and scars left by former ulcers. During the last little while he has had to treat six such cases in which he was quite unable to obtain any resulting improvement for the patients (who were practically blind) until he decided to adopt inoculation. Of these six patients he describes in particular the cases of three, whom he exhibited at the meeting of the Society on the occasion of reading his paper: the other three patients were not shown, but in all cases a good and apparently permanent result had been obtained. Of the three we shall give very condensed notes.

(1) A man, aged 25; infected with trachoma in 1905 while going through his military service. He spent eleven months in

hospital undergoing treatment, and was dismissed from the army as incurably blind. When seen by Goldzieher he had intense photophobia, copious mucopurulent secretion, thickened conjunctiva with large papillary growths and grey "granulations," severe conjunctival and ciliary injection. In particular the cornea was so densely invaded by vessels all over its surface that it was only at the limbus that these could be distinguished from one another. Both eyes were in a similar state. Vision was reduced to perception of light. After the patient had been three months in hospital undergoing various forms of treatment with no benefit whatever, his left eye, which had become somewhat worse rather than better was infected with pus from a case of blennorrhœa. In three days the reaction began, lasted more or less for a month, and at the end of that time the patient left hospital (contrary to Goldzieher's desire) with a very considerably clearer cornea. About a year later he presented himself with that (left) eye practically quite well: the cornea showed a few fine nebulæ, the eye was free of all injection, and the conjunctiva was absolutely normal, showing not a trace of trachoma: vision was correspondingly improved. The right eye was *in statu quo*. Having first proved the absence of gonococci from the secretion coming from it, Goldzieher now inoculated the right eye, with a similar excellent result.

(2) A boy of 13, who had lost his left eye some years before, but of this he could give no account. The right eye had been blind for three years and had had no treatment. It was then in a state of regressive trachoma, with scarred conjunctiva, mis-shapen lids and trichiasis, very dense pannus, and scanty mucoid secretion. Vision was limited to hand movements close to the eye. The lids were first operated upon and the inversion cured, but the pannus resisted all treatment, until the eye was inoculated with blenorrhœal secretions. On the third day the reaction began and he had a severe gonorrhœal ophthalmia in the course of which the vessels of the pannus became "lost" in the gray infiltration of the cornea. In a month the cornea was all but clear and he could count fingers promptly at 6 metres; he was removed from the Blind Asylum (to which he had originally been sent, and whose officials had handed him over to Goldzieher for treatment) and put to a trade.

(3) An Italian, aged 55: he had been affected for a year, and his wife also, and was now practically blind. In both eyes the conjunctiva was intensely trachomatous, with large papillary growths: brawny infiltration in the fornices, muco-purulent

secretion in which no gonococci could be demonstrated; very intense injection of conjunctival and ciliary vessels; ciliary pain and photophobia severe. With the right eye he counted fingers close to the eye, at half a metre with the left. Mere ordinary treatment being a failure it was decided to inoculate him, but as it happened that there was no suitable case of ophthalmia neonatorum on hand this was done from a case of gonorrhœal ophthalmia in the adult. After four days there was severe reaction in the right eye and a day later in the left. In a few days the vascularization of the cornea was, as in the previous case, almost quite concealed by the gray infiltration, and in the right eye there formed a circular furrow round the middle of the cornea as though the centre was about to slough away, but it did not, and in less than a month from the day of inoculation all inflammatory changes had disappeared from the conjunctiva, pain was gone, the corneæ had to a great degree cleared up, and injection had so completely disappeared that even when he was shown two months later at the meeting of a Medical Society, and fifty persons had (as Goldzieher naïvely puts it) examined his eye and everted the lids, no reaction occurred. Eventually he secured finger-counting at 2 to 3 metres in the right eye (which had still to have an optical iridectomy done before it could be at its best) and $^5/_{20}$ with the left eye.

Goldzieher defends himself against the charge of the reckless employment of a dangerous procedure by the just observation that the fact that he has only acted thus in six patients during the last five years, although he sees numberless cases of the disease, shows that he is not hasty to adopt a line of treatment which he admits to be heroic, and he goes on to lay it down as a rule that this procedure should only be carried out where there not merely is pannus but where the pannus is of the densest character, reducing vision to hand movements, concealing the iris, and spreading over the whole cornea as a thick, vascular, succulent blanket.

For inoculation pus should never be taken from a gonorrhœal urethra or from the conjunctiva of an adult affected with gonococcal conjunctivitis, but from the less noxious stock of an ophthalmia neonatorum. A little of the infected material should be picked up not in a mass but rather by drawing the sterilised glass rod along the everted lower lid and thus infecting the eye to be treated rather with lachrymal secretion containing organisms than with actual pus. The only particular point to be noted in regard to the course of the severe inflammation which

follows is that from experience of these cases the author asserts that one must not be afraid of the alarming gray infiltration of the pannus cornea, for this seems to be an indispensable preliminary to clearing up. A point of great importance and of much encouragement is that even when there has been a great deal of trachomatous infiltration of the conjunctiva still healing may be secured without any scar formation: the fact that this is so, indicating as it assuredly does that trachoma is not *necessarily* or *inevitably* followed by scarring, is of great encouragement as regards results of this treatment and of other methods which are still to be brought forward.

In conclusion Goldzieher again earnestly advises against the use of this treatment so long as there is any chance of other methods being of any service: it is only a *dernier ressort*; and in particular warning anyone who may think of employing it that there is all the difference in the world between a comparatively clear cornea and one whose anterior layers are thick, succulent, and highly vascularised: in the former case the method under consideration is absolutely contra-indicated. The "arm-chair critic" may suggest that by inducing gonorrhœa of the conjunctiva the surgeon may be in danger of producing some distant, remote, and doubtful evil consequences to his patient, but to be relieved of intense trachoma with its blindness, pain, and long drawn out misery, most patients would cheerfully and wisely and eagerly risk much more than that.

W. G. S.

WALDSTEIN (Prague). **The Histology of Gonorrhœal Conjunctivitis.** *von Graefe's Archiv für Ophthalmologie.* 72, 2.

FOR this investigation Dr. Waldstein removed small pieces of tissue from the transitional fold and tarsal portion of the conjunctiva in cases of gonorrhœal conjunctivitis. They represented all stages of the disease from 2 to 60 days after the outbreak of the inflammation in babies, children, and adults. He examined 19 pieces of tissue obtained from 16 separate cases. Of these 8 were cases of ophthalmia neonatorum in which the gonococcus was present and 2 more cases believed to be gonorrhœal in origin although the micro-organism was not found. In addition to these there were four cases of acute conjunctivitis due to the micrococcus catarrhalis. He gives a minute account of the histological findings in all these cases.

In considering the cases of ophthalmia neonatorum he divides them into three groups:—

I. Up to about 14 days, when the destructive process predominates.

II. From 2 to 4 weeks, when the tissues gain the upper hand over the invading germs.

III. The stage of repair and return to normal condition.

The more important facts concerning these groups are as follow:—

Group I (cases 1—4). In this there was vascular dilatation and infiltration of the connective tissue stroma and epithelium by phagocytes. The epithelium presented signs of severe damage, becoming necrosed, and shed into the secretion. Some attempt at repair could be seen during the latter half of the first week. There was an ingrowth of the epithelium into the sub-epithelial tissues. These downgrowths had the appearance on section of glands, and some of the epithelial cells had become goblet-cells. The phagocytes consisted almost entirely of polynuclear neutrophile leucocytes which came from the neighbouring blood-vessels. The gonococci in the superficial cells caused necrosis and the cells became detached. The gonococci then attacked the deeper layers extending even beyond the basal layer into the sub-epithelial tissue. The secretion corresponded to these changes, being sero-saneous with few cells in the early stages and becoming later thick and creamy and containing more cells. Besides the epithelial cells there were polynuclear neutrophile leucocytes, 95 per cent. or more with a few lymphocytes. The cells contained gonococci.

Group II (cases 5—7). The round cell infiltration was subsiding and the epithelium was less defective. The increased vascularity was diminishing. The gonococci were less in number and mostly intra-cellular in superficial layers. In the secretion the number of lymphocytes seemed greater than the leucocytes and the gonococci less in number. The epithelial cells were disappearing from the secretion.

Group III (cases 8–9). The epithelium was regenerated but the arrangement was not normal. Besides poly- and mono-nuclear leucocytes this stage was characterised by the presence of numbers of mast cells which wandering through the epithelium escaped with the other cells in the secretion. These cells underwent considerable change in appearance as they passed to the surface from the deeper layers. As these cells have not been observed in the secretion Dr. Waldstein thinks they undergo degeneration

and a granular detritus is all that remains. Gonococci were entirely absent in this stage.

The two cases of ophthalmia neonatorum where no gonococci could be found, except for this, differed in no respect histologically from the gonorrhœal cases.

The cases of gonorrhœal conjunctivitis in adults (cases 12—17) were in all phases entirely similar histologically to those cases described above. Lastly, the two cases due to the micrococcus catarrhalis are considered. In all important features they agreed with the gonorrhœal cases. The bacteria, however, were not present in the attached epithelium. They enter the cells but are quickly eliminated by the epithelium being cast off owing to necrosis taking place. Of course the micrococci are present in the secretion. Dr. Waldstein believes that the difference between the two conditions is due to the different actions of the two toxines they produce. A point also to be considered may be the fact that the gonococcus enters the epithelial cells more easily than the micrococcus catarrhalis.

In conclusion he sums up the results of his investigations as follows:—

(1) Gonorrhœal conjunctivitis is an inflammation which confines itself to the superficial layers of the conjunctiva.

(2) The gonococci, for the most part, occupy the upper and middle portions of the epithelium but when this is shed reach the basal layer and pass into the sub-epithelial tissue. They are nearly always intra-cellular.

(3) Repair begins in the second half of the first week. Active growth takes place into the depth of the necrotic tissue giving rise to gland-like structures containing goblet cells.

(4) The subepithelial infiltration consists in the main of plasma cells—in which mitosis is a frequent occurrence. Mast cells, which increase in number later, pass through the epithelium to the surface and so into the secretion.

(5) Eosinophile cells play no essential part in gonorrhœal conjunctivitis.

(6) A great increase in the blood-vessels takes place from which emigrate the polynuclear neutrophile leucocytes, plasma, and mast cells.

(7) The connective tissue only plays a small part in the inflammation and the elastic fibres undergo no alteration.

(8) The gonorrhœal conjunctivitis of the adult differs histologically in no respect from that in the newborn.

(9) The ophthalmia neonatorum, in which no bacteria are

present, differs only from the gonorrhœal by the absence of the gonococcus.

(10) The blenorrhœa due to the micrococcus catarrhalis, in contrast to the gonorrhœal, shows less damage to the epithelium even in the earliest days. The organism is confined to the superficial layers and easily eliminated.

BEATSON HIRD.

BOARDLEY and CUSHING (Baltimore, U.S.A.). **Alterations in the Colour Fields in Cases of Brain Tumour.** *Archives of Ophthalmology*, xxxviii., 5, 1909.

THE two authors of this interesting and valuable paper have been for a number of years making careful investigations into the state of the colour fields in as many cases of brain tumour as could be found suitable. Naturally, many of the patients are incapable of affording information on this point because of youth, of blindness, or of mental or physical infirmity, such as aphasia. One of the difficulties which the writers found to be a source of error was imperfection in the hues of the test discs: now they employ spectral colours, having found that the presence of a mixture of colours in the test objects was productive of false impressions. In fifty-six cases however in which they were able to make reasonably reliable records they came to the following conclusions: in 25 cases the predominant feature was interlacing of the colour lines; in 9, colour inversion, *i.e.*, the blue field smaller than the red; in 4, hemi-achromatopsia without corresponding change in the form field; in 3, islands of blue blindness; in 3, blue blindness; in 1, complete green blindness; in 5, complete achromatopsia; and in 6, no colour change whatever.

Putting their conclusions in a different form, they work out thus: (1) Of fifty-six patients fifty showed colour changes, while only eighteen showed form-changes—a record which differs greatly from the ordinarily accepted view of the frequency of such alterations; (2) in four cases interlaced colour boundaries were found, although choked disc was not present, showing that it was no mere local change dependent on inflammatory exudation which produced the symptom; and (3) forty-two cases were re-examined after operation and in forty-one of these the colour-lines became restored to their normal relative position.

Dyschromatopsia has hitherto been, and is still very largely, regarded as "hysterical" by most clinicians, and especially when

it accompanies concentric restriction of the field, but if the authors of this paper are correct we must review this opinion with care, for whether these symptoms occur in hysteria or no, they cannot be characteristic of that most singular condition, inasmuch as they are present in a number, perhaps a large number, of cases of genuine local disease. We are however startled by a statement of the authors, which (even supposing it to refer solely to their own actual cases and not understanding their words in a more general sense and of wider application) may justify us in taking off a little percentage, namely this: "We at least must face the disconcerting fact that almost every patient brought for operation, after the diagnosis of brain tumour has finally come to be read by the ophthalmoscope on his retina (*sic*), has at one time or another been regarded as hysterical or the subject of some psychoneurosis." Is not this too strong a statement?

The authors consider that the changes of most significance seem to be those of the field for blue, which therefore may be of great service in contrast with the cases of tabes, sclerosis, etc., where the red fields are more liable to attack. In some instances at least scotomata form in the periphery of the blue fields, which coalesce, and thus the field becomes more and more restricted.

Complete achromatopsia, in which objects appear as in an "Indian ink sketch," appears to cause great confusion of sight, even greater than a well marked concentric restriction of the fields.

The paper is one meriting attention and calling for confirmation (or the reverse) of the views of the authors, for if they are correct careful examination of the fields may supply more information than one has been apt to suppose.

W. G. S.

Z. B. Wicherkiewicz. **On the Operation of Unripe Stationary Cataract.** *La Clinique Ophtalmologique.* Jan., 1910.

This is an article intended to show that all cataracts whether immature or stationary are amenable to successful operation when irrigation of the anterior chamber is adopted as part of the procedure.

After a few preliminary remarks on the divergence of opinion as to what constitutes maturity of cataract—for some absolute opacity of the lens—for others when vision is reduced to a

certain minimum—not stated; and on the difficulties of affirming whether a cataract is complete or not; the author assures us, that, thanks to irrigation, almost any degree of immaturity, and any kind of cataract may be dealt with successfully.

With his method of operation (not detailed in the article) which he has carried out for more than a quarter of a century, he has never had any reason to find fault; and he is convinced that this is the only process of removing incomplete cataracts surely and readily. If not universally practised by ophthalmic surgeons, it is because rupture of the hyaloid membrane and loss of vitreous is feared, an accident which never happens, according to Professor Wicherkiewiez, if his operation be properly performed.

The author now examines the different kinds of cataract which lend themselves to the operation without any preliminary measures.

(*a*) *Cortical Cataract.* (1) When the cortex is opaque, striated, and the fundus is no longer visible, the nucleus and the cortex can be extracted either by expression or preferably by irrigation. (2) When the cortex is segmented and swollen, extraction is usually easy, often without irrigation. (3) When the cortex is opaque, diffuse, and bluish in colour, but still transparent. Here the cortex detaches itself with difficulty. A successful issue is only obtained by irrigation. (4) When the cortical striæ have disappeared and the cataract is uniform and of a bluish colour. Extraction here is performed by some unusual method.

(*b*) *Nuclear Cataract.* (1) Complete cataract, so called hard cataract, comes away easily and completely. (2) Cataract hard, but incomplete. The nucleus comes away easily. When the nucleus is not large, the surgeon must be on his guard in supposing that the cataract has been entirely removed, even when the pupil appears black, because the clear cortex remains and gives trouble later on. By using oblique or artificial illumination the cortex is more readily detected, and irrigation ought to be used.

(*c*) *Hypermature and Morgagnian Cataract.* (1) These are easy to remove, although sometimes unexpected accidents occur. It often happens that after cystotomy the nucleus comes away and the liquid mass remains on the iris, or the liquid part comes away readily, whilst the small nucleus falls to the bottom of the anterior chamber without budging even after attempted expression. In one or other case irrigation is indicated.

(*d*) *Cataract Arida-siliquata.* (By which name we presume the author refers to "chippy" lenses). In this variety only irrigation is successful.

(*e*) *Partial and Stationary Cataract.* These offer a large field for this method. (1) C. Stellata, (2) C. Punctata, (3) C. Zonularis—are admirably adapted for linear section plus irrigation. The pupil must be well dilated (atropin). Capsulotomy must be large. Evacuation of lens by curette, or by massage, as much as possible, followed by irrigation, sometimes somewhat prolonged. Very often the pupil becomes suddenly black and remains quite free. If any lens matter remains it will be absorbed. This class of case often gets well in 10 days.

The satisfactory method or irrigation has encouraged the writer to adopt the same plan for the removal of normal lenses in high myopia. G. W. Thompson.

Handmann (Döbeln). **The Beginning of Senile Cataract in the Lower Half of the Lens.** *Klin. Monatsbl. f. Augenh.*, Dec., 1909.

Dr. Handmann from the beginning of his practice in 1903 has made a point of recording exactly in all cases of cataract the nature of the opacity, its position as regards cortex, nucleus, pole or equator, and, in the case of peripheral opacities, the segment of the lens in which they were situated; and before long made the discovery that the first indications of senile cataract appeared with much greater frequency in certain quarters of the lens periphery than others.

Most of us have probably made the same observation for ourselves; but if it be true, as Dr. Handmann states, that he has ransacked all the modern (German) text books on ophthalmology and monographs on diseases of the lens without finding any mention of it, and that he has only in the course of his reading come across two incidental references to it (one German and one American), it may be worth while to present here his carefully collected statistical evidence on the matter.

His figures concern 845 eyes with senile cataract, in which the opacity could be called incipient in the sense that some portions of the lens were still transparent; there were 1147 opacities or groups of opacities, which were distributed in the regions of the lens in the following manner: Lower 335; lower nasal 118; lower temporal 35; upper 32; upper nasal 14; upper temporal 15; nasal 111; temporal 67; diffuse 65; whole periphery 89; central 220; supranuclear 26; doubtful 22.

Excluding the more advanced cases and taking only those which presented no more than one or two opacities, with normal or nearly normal visual acuity, the figures were for 391 peripheral opacities: Lower 319; upper 21; nasal 40; temporal 11.

Having thus shewn the marked preponderance of the earliest signs of senile cataract in the lower half of the lens he discusses the inferences which may be drawn from the fact. We know that adventitious substances, such as blood and pus, tend to collect in the lower part of the anterior chamber, and we may assume that pathological products and excreta so far as they are specifically heavier than the aqueous will take the same position, and the lower half of the lens will thus be less favourably situated as regards metabolic changes than the upper. Another possible factor in the production of senile cataract is the influence of the ultra-violet rays on the lens. Such rays have been shewn by Widmark, Hess and others to be capable of producing destructive changes in the lens fibres (as well as in other tissues of the eye) and it is obvious that in the ordinary occupations of life the lower, and perhaps especially the lower-inner, parts of the periphery of the lens will be more exposed to light rays than the upper.

Taking these facts in conjunction with his present observations Handmann is inclined to view the latter as a proof that senile cataract arises from certain disturbances of the nutrition of the lens which make themselves felt more readily in the lower than in the upper part of the lens.

Do cataracts due to other causes shew a similar localization? The author's figures bearing on this point are naturally much smaller than those for senile cataract, but so far as they go he considers that his statistics for diabetic and glaucomatous cataract shew that the changes in the lens in such cases are more apt to be diffused and exhibit no marked preponderance in any particular region. W. G. L.

La Doctoresse Bonsignorio. **On the Absorption of Simple Senile Cataract.** *La Clinique Ophtalmologique,* Jan., 1910.

The partial and even complete absorption of senile cataract is a well established fact. A considerable number of cases have been reported, but on closer examination many of these can hardly be called typical senile cataracts. They are usually complicated by grave diseases of the eye, such as glaucoma, myopic choroiditis, and further they have occurred in patients

between the ages of 45 and 55 at a time when senile cataract can hardly be said to have commenced. The author thinks that it usually takes from 8—15 years for the absorption and liquefaction of the perinuclear layers of a cataract, so that probably most of these cases of absorption reported in literature started as cataracts between the ages of 35 and 40.

Most of the cases described were diagnosed by the ophthalmoscope only, but the author had the good fortune to confirm the diagnosis by extraction and subsequent examination of the capsule and its contents, in five cases of double cataract in her clinic. The cases were patients of over 70 years with double cataract of long standing. In each case one of the cataracts was more or less absorbed at the time of the operation. The history of each case was one of gradual loss of vision, and complete blindness, eventually followed by slow recovery up to a point of distinguishing large objects—cats and dogs—but no small objects. With the recovery of the first affected eye, there was gradual failure of the second. The affected eye (the one with absorption partial or complete) presented the following characteristics:—The anterior chamber was deep, the pupil was moderately dilated and almost black, had a central greyish reflex, and further back resting on the posterior capsule, was a deep yellowish or amber coloured spot, the nucleus of the lens. The iris was on a posterior plane, quite non-tremulous. Ophthalmoscopic examination of the fundus was possible through a haze more or less dense according to the degree of absorption.

The author extracted the cataracts in both eyes of five patients, and the hypermature cataracts were rather remarkable in their behaviour. Each time that the corneal flap was completed there was a spontaneous and brusque expulsion of the cataract in its capsule without any apparent manœuvre that could have provoked this action. The pressure of the knife in the eye had sufficed to tear the degenerated fibres of the zonule. I say "tear" because the capsule was still in its place, not only because the ophthalmoscope had revealed no luxation, but also because the cataract was forced out without any preliminary flow of vitreous: the latter in small quantities always followed after the cataract was expelled. The cataract was very much reduced in volume, soft and flaccid and readily folded, or became fusiform. On incising the capsule with the scissors the nucleus was extremely small (Hempseed) and the fluid was of a yellowish colour somewhat thickened, or dirty white. The visual acuity was good, and the healing rapid in each case.

The author is of opinion that it is the integrity of the capsule that favours the regression, the emulsion and the liquefaction of the crystalline fibres in persons suffering from senile cataract. She further holds that confirmation is needed of the absorption of the nucleus and of the cortex after rupture of the capsule in cases of senile cataract, as maintained by some authorities, and that lens material left in the anterior chamber after extraction of senile cataract is seldom, if ever absorbed.

G. W. Thompson.

S. S. Golovine. **Exenteratio Orbito-sinualis.** *Annales d' Oculistique*, Dec., 1909.

A detailed explanation is given in this article of the author's method of operating on extensive malignant growths of the orbit. He points out that such growths, especially epitheliomata of the lids, easily penetrate into the cavities in the neighbourhood of the orbit, viz., the antrum of Highmore, nasal cavity, and the ethmoidal and frontal sinuses. Epitheliomata at the inner canthus are particularly prone to invade these regions. Such being the case, it is obvious that to effect a cure by operation, the procedure must be thoroughly radical. The operation described aims at converting the orbit and neighbouring sinuses into a single large cavity, every part of which is readily accessible. The details are as follows:—

I. *Incisions.*

(*a*) Internal vertical: from 2 to 3 cm. above the glabelion to 1 cm. below the level of the angle of the nose.

(*b*) External vertical: along the semicircular ridge of the frontal bone to 2 cm. below the zygoma.

(*c*) Superior horizontal: across the eyebrow from *a* to *b*.

(*d*) Inferior horizontal: from *a* to *b* a little lower than the inferior margin of the orbit.

An H shaped incision with two cross-bars is thus marked-out. (See diagram.) The frontal flap is undermined up to the hair line: the malar flap is reflected down as far as the alveolar margin; thus the orbital periphery is fully exposed.

II. *Exenteration of the Orbit.* The lids, globe and the entire orbital contents and periosteum, are removed, as far as possible in a single mass. The bones of the orbit and the sinuses are now carefully examined.

III. *Exenteration of the Sinuses.* In malignant growths at

the inner canthus, the internal and inferior parts of the orbit are those usually affected. The antrum is first investigated by removing its roof (*i.e.*, the floor of the orbit) and part of the anterior wall. Following this the nasal process of the superior maxilla, the lacrimal bone, part of the nasal bone and the nasal process of the frontal bone are cut away. Then the os planum of the ethmoid and finally the anterior and inferior walls of the frontal sinus are removed. The septa between the ethmoidal sinuses are cleared away so as to lay bare the anterior wall of the sphenoidal sinus; and any affected tissue in the nasal cavity is scraped away. The posterior wall of the antrum

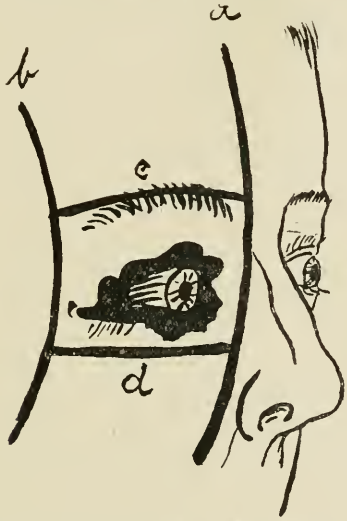

and the frontal sinus are curetted. The whole field of operation is thus converted into a large osseous cavity.

IV. *Plastic Closure.* The upper and lower musculo-cutaneous flaps are brought together by sutures, and then united to the lateral flaps, forming an H shaped junction. Finally gauze is inserted into the underlying cavity through the nose.

This method of operating was employed in ten cases, with good results. In a few the transverse sutures tore apart but secondary sutures produced firm union.

Five cases are reported in detail with photographs of the patient before and after treatment, all exhibiting an excellent cosmetic appearance, as well as a cure of the condition.

WILFRED ALLPORT.

JACQUEAU (Lyons). **A Form of Hereditary and Family Keratitis.** *La Clinique Opthalmologique,* Sep., 1909.

THE family which has furnished Dr. Jacqueau with the material for his paper is composed of seven persons, on one side four brothers and sisters, on the other a brother and sister, cousins german of the former.

There is also a son, the result of a marriage between the eldest brother of the first group with his cousin of the second group. The paternal grandfather of the first group suffered severely from gout; the mother of the same group died at the age of 72, nearly blind, after having suffered for nearly twenty years from an ocular affection which appears to have had all the characteristics of the cases described by Jacqueau.

These eight persons have been and are still the subjects of an identical and special form of corneal affection, which has commenced at a ripe, if not advanced age, except in the case of the son of the consanguineous marriage, who was attacked at the age of 22.

One member of the family suffers from gout, another from rheumatism, otherwise the general health of the family is excellent; there is no evidence of alcoholism, diabetes, albuminuria, or syphilis.

All these patients show in both eyes considerable opacities of the cornea. The corneal epithelium is preserved and does not appear to be raised, but one sees in the superficial layers of the cornea a fine network of whitish lines more regular in arrangement in some places than in others, but situated in all cases chiefly in the centre of the cornea. Inflammatory reaction is very moderate or absent. The sensibility to touch is diminished, and there is so little photophobia that most of the patients can without great difficulty continue work which is not very fine in character.

The medication which has given the best results is the instillation of dionin, with intervals of two days every three days.

With regard to the etiology of this condition, Wehrli assigns tuberculosis as the cause and proposes to give to this affection the name of lupus of the cornea. Abadie is inclined to look upon these cases as being gouty in origin, the consanguinity which has been noted here and there is a factor which has to be considered.

In conclusion, the etiology has still to be found, but what the author particularly wishes to lay stress on is the family and hereditary character of these cases of chronic keratitis, and the resistance to treatment. E. M. LITHGOW.

VAN DUYSE. **Endothelium (perithelium) or Epithelium? A contribution to the study of tumours of the orbit.** *Archives d' Ophthalmologie.* November, 1909.

VAN DUYSE gives us a fresh contribution to the subject of the histogenesis of the class of tumours variously designated endotheliomata, fibrosarcomata, endothelial carcinomata, endothelial adenomata, fibro-epithelial, and mixed tumours, etc.

The clinical and histological characters of these tumours are described in an illustrative case by the author. A man, 25 years of age, some five years after an injury to the right eyebrow, developed proptosis with diplopia, due to the displacemen of the right eye down and out and the impairment of the action of the superior rectus by a tumour in the roof of the right orbit. There was no involvement of the optic nerve but the vision in the affected eye was reduced to $\frac{1}{2}$. On palpation of the orbital structures a tumour of firm, though not osseous, consistence could be felt between the eye and the orbital roof. This was diagnosed as a sarcoma probably of endothelial origin, and was successfully removed by Krönlein's method of orbital resection.

The tumour, which was situated between the muscular cone and the orbital roof, was easily detached by a few snips of the scissors. It was of the size of pigeon's egg, oval, flattened and slightly bosselated. It was of greyish-white colour with specks of red and was enclosed in a thin capsule.

The histological structure of the growth consisted fundamentally of double rows of epithelioid cells surrounding the adventitial sheaths of the capillaries which had largely undergone hyaline degeneration. There was no proliferation of the intravascular endothelium but the lumen of the capillaries was narrowed owing to the swelling of the hyaline adventitia and the proliferation of the neoplastic cells planted perpendicularly on their outer walls, and the accumulation of hyaline material in the spaces between the vessels. These intervascular or "lymphatic" spaces (Max Borst) which varied in size and shape according to the direction of the blood-vessels and the number of their anastomoses appeared to be lined by the double rows of

neoplastic cells on the blood-vessels, and looked like tubes or alveoli. This appearance has given rise to the terms "tubular perithelioma," "alveolar perithelioma," and is suggestive of a metatypical adenoma or an adenocarcinoma.

The "lymphatic" spaces were occupied by a more or less clear substance which was the product of the secretion and degeneration of the lining cells. Frequently some extravasation of blood was also found in them.

The lining cells were of two types and were arranged in two layers in relation to the vascular adventitia. The proximal cells were cubocylindrical with large oval nuclei rich in chromatin, having generally a nucleolus and clear cytoplasm.

The distal row was composed of cubical cells whose free borders were in relation to the lumen of the tubes and alveoli and were irregular in consequence of the globules of secretion which escaped from them. Their attached margins sent one or two prolongations between the proximal cells. Hyaline metamorphosis took place in the cells of both rows by the formation of small globules which eventually coalesced. The process began at the periphery of the cells and extended inwards towards the nucleus. The hyaline outline of the cells accentuated their epithelium-like appearance.

The approximation of the globules of neighbouring cells gave the appearance of moniliform intercellular spaces and a suggestion of intercellular processes characteristic of epithelial prickle-cells.

In the later stages the hyaline substance became more abundant, the cells became stellate in shape and the structure had a myxomatous appearance. The formation of hyaline globules in the cells is suggestive of a secretory function which has been attributed to endothelial cells by Heidenhain and Hamburger.

The hyaline degeneration of the vessels and the pressure of the swollen neoplastic cells favoured the rupture of the vessels and occasionally blood escaped into the tubes and alveoli. Hyaline degeneration also involved the general stroma of the growth, giving rise to more or less homogeneous masses in which the nuclei of connective tissue cells could be recognised.

When the degenerative process is intense but limited to small areas we find circumscribed claviform or lobulated homogeneous masses which compress and displace the neoplastic cells. When the neoplastic lells become compressed without undergoing hyaline degeneration, they become flattened and fusiform and

arranged in concentric layers (called "cancroidal pearls") suggestive of epithelial cell-nests.

By the proliferation of the neoplastic cells the intervascular "lymphatic" spaces tended to become obliterated and the adenomatous character of the growth to give place to an appearance of glandular carcinoma or alveolar sarcoma, in which the obliterated vessels were represented by hyaline streaks only.

In some parts the stroma had a cartilaginous appearance, in other places it was mucoid in structure, but in each case the appearance was due to a hyaline degeneration of the fibrous tissue elements and not to the formation of genuine cartilage or mucin. The increase in volume of the hyalinised stroma tended to isolate and compress collections of neoplastic cells which eventually assumed the appearance of connective tissue cells.

Much of the confusion, in the description of these tumours, has arisen owing to the fact that the cells which line the interior and often the exterior of blood and lymph vessels have been called epithelium by some histologists who have ignored the essentially different embryonic origin of epithelium and endothelium.

It must also be remembered that endothelial cells may assume the appearance of epithelial or of connective tissue cells—epithelial and fibroplastic transformation. It is not surprising therefore that tumours derived from endothelium may sometimes be sarcomatous, at other times carcinomatous, in appearance. If the dimorphic and secretory characters of endothelium be admitted the varied characters and appearance of endotheliomata become explicable.

If these orbital tumours are regarded as endothelial growths it is unnecessary to invoke the unlikely processes of epithelial inclusions or embryonic remains which have to be advanced to support the epithelial theory of origin.

It is not easy to tell an endothelial from an epithelial cell by its histological appearances or the biochemical characters of the products of metamorphosis or the appearances of these cell-nests.

Van Duyse, however, finds that the hyalinised centre of the endothelial cell-nest does not retain the colour when stained in acid fuchsin, while the eleidin in the keratohyalin centres of epithelial cell-nests retains that colouring matter. Judged by this test the author's orbital growth was an endothelioma.

J. Jameson Evans.

R. Greeff. **Guide to Microscopical Examination of the Eye.** *Anleitung zur mikroskopischen Untersuchung des Auges.* 3rd Edit., Berlin, 1910, Hirschwald. Price 4 marks.

Histological technique is a subject which cannot be learned from books alone. Every laboratory worker cherishes a number of little "tips" of his own devising, and firmly believes that without them the perfect result is unobtainable. Since its first appearance in 1898 however, Prof. Greeff's little manual, which has now reached its third edition, has proved itself a thoroughly reliable guide to the special technique of the eye. The reader is not perplexed by the presentation of too many methods, but those which are included are carefully selected, thoroughly practical, and for the most part simple. The descriptions are clear, and misprints, which so easily creep into a book of this kind, seem to be remarkably few. We notice however an unfortunate one (4 per ct. for 40 per ct.) on p. 22, in a foot-note which is meant to clear up misconceptions as to the strength of formalin.

The present edition is enriched by a chapter from the pen of Prof. Stock on bacteriological staining methods, in which, as was to be expected, full instructions are given for the staining of the so-called trachoma bodies. Otherwise the changes in the text, as compared with the second edition, are not great. The book commences with useful sections on apparatus, orientation, etc. In the chapter on fixatives justice is perhaps scarcely done to the merits of Zenker's fluid, which is replacing other fixatives in many laboratories. It is recommended because it preserves the normal form of the choroid, but its excellence as a cytological fixative is insufficiently emphasised, and the combination of Zenker and formalin fixation, which gives, we believe, the best results, is not mentioned. The celloidin method of embedding is naturally described in detail; the time recommended for soaking in thin and thick celloidin (four days in each) is perhaps unnecessarily long, but if this be an error it is at least in the right direction. An excellent account is given of the preparation of serial celloidin sections. Mallory's connective tissue stain is described, but the polychrome methylene blue and Pappenheim methods are not mentioned. The description of the Golgi and Ramon y Cajal methods is very full and good. Sections are devoted to the demonstration of fat, lime, cholesterin, mucus, hyalin and amyloid material, etc.; it is tolerably

certain that all the substances classed as hyalin—the membrane of Descemet and Morgagnian globules for instance—are not of the same nature. A special portion of the book is devoted to the microscopical examination of the different parts of the eye: a new section on the vitreous, a subject which Prof. Greeff has specially studied, is added.

Our recommendation is scarcely required for a book which already occupies so high a place in the estimation of all practical workers. An English translation of the work has already appeared; it would be well if the additions in the present edition could also be made available to English readers.

LAUBER and ADAMÜK (Vienna). **On the Presence of Doubly Refractive Lipoid in the Retina in Albuminuric Retinitis together with remarks on the pathology of this disease.** *v Grafe's Archiv. f. Ophthalmologie*, 71, 3.

WHILE a great deal of work has been done on the pathology of albuminuric retinitis and the subject has been recently revived by Leber, a review of whose work appeared in this "Journal" (Sept., 1909, p. 257), the authors believe that for the elucidation of various points that are still obscure one must employ other methods besides the chemical reaction of tissues to stains, and they suggest the application of the methods of physics and physical chemistry as likely to prove useful for further investigation.

Within the last few years certain fat-like substances have been found in the kidney only in cases of nephritis, and the main purpose of this research has been to enquire whether a similar deposit occurs in the retina simultaneously with ordinary fat in albuminuric retinitis.

Lipoid is a name given to a fat-like substance which, while like true fat in some respects, differs from it in certain physical and chemical properties. Among these is the fact that when examined with the polarisation microscope it is found to be double refractive, while with osmium it assumes a grey colour and only becomes black when treated with alcohol; it loses this black colour in xylol or chloroform, and being easily soluble in ether and alcohol it is impossible to find it in sections obtained after imbedding in celloidin or paraffin. This necessitates the

employment of fresh material or of eyes previously prepared exclusively in formalin.

In a series of 13 cases of albuminuric retinitis which the authors collected and submitted to a most thorough and careful examination they were able in four to look for the presence of lipoid in fresh frozen sections. It is unnecessary to describe these cases or the methods of examination in detail here, but a short summary of the general results obtained may be given.

Detachment of the retina is a very common complication. The small detachments were not seen clinically, because they were flat and with the thickening and opacity of the retina they looked more like œdematous areas. They were all the result of an exudation which, sometimes serous, sometimes fibrinous in character, was in most cases derived from the choroid, although, where the internal limiting membrane was detached, or the outer limbs of the rods and cones were found separated from the rest of the retinal elements, the exudation must have arisen in the retina itself.

As to the rôle which the vascular changes found in this disease are supposed to play in its causation, they vary so much in degree that the authors consider it extremely doubtful that they are really the cause of the conditions in the retina. It is possible that while they may at times be of great significance in the development of albuminuric retinitis they are often merely a symptom of an intoxication due to the alteration in the composition of the blood and a result of the renal disease.

According to Leber the pigment epithelium cells play a very important part in the production of the histological picture of albuminuric retinitis by taking up fat, losing more or less of their pigment and appearing as fatty cells which wander into the retina. Lauber and Adamük, however, were unable to confirm this in their cases. As regards the absorption of fat-droplets by the pigment epithelium cells this was observed in only one case to a very limited extent; the changes they found more or less pronounced in all their cases consisted either of a proliferation or a destruction or even disappearance of these cells; they found no trace of fuscin pigment in the fat-containing cells in the retina. It is of interest to note the changes in the retina corresponding to the white spots of the clinical picture. These spots may be accounted for by the ganglion-like degeneration of the nerve fibre layer, the presence of fibrin, the deposit of fat or fat-like material, either separately or together. The fatty substances may be found in any of the layers of the

retina. The fat may lie free, or it may be contained in the supporting fibres or in 'fatty granular' cells. While these fat-containing cells, however, may not be in sufficient numbers to explain the white spots seen clinically it should not be forgotten that many substances that appear white ophthalmoscopically may be removed in the preparation of celloidin sections (*e.g.*, lipoid). In the cases which the authors were able to examine for lipoid by their special method they found it in sufficiently great quantity to account for the ophthalmoscopic appearances. The discovery of this substance is the main theme of this contribution. In every case it showed the same position and properties above referred to, and as it corresponded in amount to the parts of the retina clinically most affected its presence must possess considerable significance in albuminuric retinitis. It remains to find out the origin of this substance and to prove whether, as the authors are inclined to think, it is a specific product of this form of retinitis as it seems to be in the kidney in nephritis, occurring simultaneously with lipoid there.

T. S.

EDRIDGE-GREEN. **Colour-blindness.** Kegan Paul, Trench, Trübner & Co. 2nd Edition.

IN the second edition of this well-known work on colour blindness the author has found no necessity to make much alteration in the text. He has however added an appendix containing some additional observations and experimental evidence supporting his views on colour vision and the action of the visual purple.

Recent cases support the author's contention that the colour vision testing as at present carried out by laymen results in the rejection of men whose colour vision is sufficient for the purpose required, and in the passing of others whose colour defect is of a dangerous type. Amongst other advantages of the lantern test is, that it is much more satisfactory to the candidate, who is in that test asked to do exactly what his work requires. When asked to match shades of wool the candidate, if an ignorant man, is apt to protest that he is not required to do this and to be very stupid in the doing of it. An intelligent man also may be taught to pass the wool test if used by one who has but little experience in its use. The reviewer has recently seen such a case passed for service as an engine driver

on one of our larger railways, who when showed a green light obscured by smoked glass called it red.

We can cordially recommend this book to all those whose work necessitates the testing of colour vision.

KRAUSE. **Surgery of the Brain and Spinal Cord.** Vol. 1, H. K. Lewis, English translation by H. A. Haubold.

THE present volume deals only with the technique of the surgery of the central nervous system and makes no attempt to deal with diagnosis or pathology. It gives at very full length an accurate account of the methods by which the various parts of the brain can be made accessible to the surgeon, and of the methods found satisfactory in dealing with the morbid conditions present. Accounts of cases illustrating the various procedures recommended are numerous. The work is extensively illustrated, and though it is legitimate to criticise the colouring as in many cases being not very realistic, the plates express with great clearness the descriptions in the text.

Berlin Ophthalmological Society, 24 February 1910.

The Reaction of the Eye to Light-rays of short Wave-length. Schanz and Stockhausen: Besides the visible rays light consists partly of invisible rays of short wave-length, the ultra-violet, which are capable of producing serious effects upon the eye, as "electric ophthalmia," for example, and snow-blindness. These rays are for the most part absorbed by the exterior parts of the eye, but those of them with relatively a long wave-length penetrate to the interior of the eye, where they are mostly absorbed by the lens, in whose capsule they induce changes, which may result in the formation, for instance, of glass-blower's cataract, which makes its appearance first in those parts of the lens which are most exposed to the action of these rays. The fluorescence of the normal lens and retina is to some degree at least due to these same violet and ultra-violet rays. They bring into action that protective mechanism by which a sudden access of light brings an immediate contraction of the pupils. It is on this account wise to protect the eyes when in presence of ultra-violet rays by closing the lids. In Alpine climbing, balloon-work, arctic travel, etc., the eyes should be well protected against these rays. Empirically dark gray or "black" glasses have been used to cut off the offending rays, but of late the Euphos glass, which

permits the passage through it of approximately all the light rays except some of the blue, and excludes the ultra-violet, has been found much superior to the dark glass. Two observers, for example, made a balloon ascent to 8000 ft.; one wore light Euphos glasses and suffered no inconvenience, while the other wore dark glasses and was attacked by severe ophthalmia.

In ordinary conditions we receive only those ultra-violet rays which cause fluorescence of the lens and retina; diffuse reflected light, such as enters our protected pupils, contains almost none; but where conditions are such that the natural protection is not maintained, protection by artificial means must be obtained, *e.g.*, in directly reflected sunlight, when the pupil is dilated, when the lens has been extracted, or when the patient works at a glass furnace.

Artificial light, on the other hand, is rich in ultra-violet rays, and the higher the temperature of the illuminant the richer is it in these rays. The ordinary oil lamp contains few or none, and is the best artificial light so long as the eye is protected from the direct entrance of the light. Should the light fall directly upon the eyes the lamp chimney or some interposed screen should be of euphos glass.

Transplantation of the Cornea. Clausen showed a young man in whose case he had transplanted into the cornea a piece removed by v. Hippel's corneal trephine from an eye with glaucoma. The tissue was removed right down to Descemet's membrane, and on this was planted the borrowed flap, in which Descemet's membrane was included. The flap took well and for a time remained transparent, but gradually became somewhat less clear; the patient had finger-counting at 2–3 m, a decided improvement on his former condition.

Herpes Zoster Ophthalmicus and Paralysis of the External Rectus. Langenhan showed a patient, aged 60, with this combination of symptoms on the left side. The paralysis first appeared five days after the herpes, which was somewhat hæmorrhagic. The blebs first affected the whole half forehead, etc., but later became limited to the scalp, the neighbourhood of the eyebrow and the outer canthus. The onset of the paralysis was ushered in with a fresh formation at the inner canthus. Langenham attributed the condition to a syphilitic neuritis which had spread from one nerve to another at the orbital fissure. Association of herpes and III nerve paralysis is much less infrequent than paralysis of the external rectus with herpes.

Voluntary Dilatation of the Pupil. Adam showed a man who

had acquired this trick. When a boy of 15 he suffered from intestinal paralysis as a result of enteric, when he learnt the art of auto-massage of the abdominal muscles. He was also able to innervate selected muscles of the arm and back, and to retard the heart's action, etc. He was hypermetropic to the extent of 2 D, and was able to accommodate so as to correct this or not at will, and so produce the associated pupil contraction.

Eye-symptoms in Disease of the Accessory Sinuses of the Nose. Gutmann first drew attention to certain diagnostic points to which he had referred in a previous paper, in regard to phlegmon of the orbit in connection with disease of the various sinuses.

In perforation of the frontal sinus:—(1) Lid phlegmon, limited to the upper lid. (2) Abscess in the upper inner angle of the orbit. (3) Dislocation of the globe downwards and outwards. (4) Crossed diplopia with vertical separation also. Cases were shown or described illustrating these conditions. A girl was also exhibited showing narrowing and obliquity of the canthus on each side from dragging of the lids attached to the scar. Five cases were described in which there was paralysis of the superior oblique following Killian's operation.

Orbital cellulitis occurs too as a result of empyema of the ethmoid. The following complications occurred in a case of right-sided empyema of the ethmoid:—Œdema of both lids, orbital abscess pointing close to the caruncle, dislocation of the globe towards the temple, and double vision. In certain cases abscess of the posterior ethmoidal cells and sphenoid produces definite eye symptoms having their origin in the optic nerve, either directly, with central scotoma and visible optic neuritis, or by the action of toxins without ophthalmoscopic changes.

Ophthalmodiaphanoscopy. Langenhan read a paper dealing with this valuable method of diagnosis between simple detachment and that caused by tumour. He showed that when tumour is in the first stage the tension need not be increased, that exploratory puncture may mislead, that Röntgen rays may not be a success, and that the transillumination method may fail when the tumour is very far back. He had found the method by diaphanoscopy very valuable, and demonstrated it, showing a leucosarcoma of the choroid quite clearly in contrast to a case of simple detachment. The success was less where connective tissue and pigment changes had followed upon detachment. He demonstrated too the shadow cast by opaque nerve fibres, and by hæmorrhages in the retina in a case of glaucoma.

PENETRATING INJURY OF THE GLOBE WITH PANOPHTHALMITIS DUE TO A GAS FORMING MICRO-ORGANISM.

By R. R. James, F.R.C.S.

Assistant Ophthalmic Surgeon to St. George's Hospital.

E.B., a healthy looking boy of eleven years of age was playing with two friends at being boy scouts on the afternoon of February 7th, 1910, the anniversary of his birthday. The boys had an air gun and were firing alternate shots, one of the boys pointed the gun which he thought was unloaded at my patient and pulled the trigger, the patient felt something hit the left eye. He was taken to the chemist who treated him with boracic lotion and a dose of salts.

Next morning the boy had some pain in his eye, and was sick, and as during the afternoon he seemed worse rather than better, the parents took him to a doctor, who ordered him up to St. George's Hospital, without delay, when he was admitted under my care.

I saw the boy at 9 p.m. and found him lying in bed apparently in no pain, and with a subnormal temperature. There was moderate œdema of the upper lid on the left side with slight chemosis below the cornea; the movements of the globe were fairly full.

There was a long wound crescentic in shape and vertical in position, just to the outer side of the mid-line of the cornea, which latter was of an opaque grey colour. No details of the interior of the eye could be made out.

On raising the upper lid I saw absolutely clear bubbles of gas issuing from the wound.

The condition was obviously an early panophthalmitis and in view of the excellent results obtained by French surgeons by performing immediate excision in these cases of panophthalmitis due to a gas-forming organism, I determined to excise the eye at once.

Excision was performed under general anæsthesia within twenty minutes. The excised globe which seemed unduly soft was put into a 10 per cent. solution of formalin: on examining the globe next morning it was found to be perforated just to one side of the optic nerve by a sharply pointed metallic body. I had an x-ray photo taken, which showed a dart in the interior of the eye.

The patient made an uninterrupted recovery and left hospital in five days' time with a clean socket.

For the following bacteriological notes of his case I am indebted to Dr. Slater, bacteriologist to the hospital.

Smear preparations made from a swab taken from the wound showed numbers of large gram positive bacilli of a length of 1—3 $\mu\mu$ lying singly. There was no chain formation.

Aerobic and anerobic tubes were inoculated.

The aerobic tubes showed no growth. The anerobic milk tube showed the "enteritidis" change, while the agar tube showed only one colony, which was of a denser appearance than is usual.

The cultures were pure, and showed the large non-motile gram positive non-sporing bacillus, which I have described before.[1]

A guinea-pig was inoculated, and on the following day appeared ill, with a gangrenous patch at the site of inoculation, and with loss of hair at this spot. On the next day, as it was no worse, it was killed and examined. A large patch of caseous matter was found

at the site of inoculation, there was no separation of the skin, no subcutaneous œdema, and no red fluid in the tissues. The internal organs appeared healthy. Preparations from the caseous matter, peritoneal fluid, and spleen showed the bacillus.

Secondary subcultures were examined with the following results:—

Milk.—"Enteritidis" change.
Potato.—Invisible growth.
Gelatine.—Liquefaction.
Broth.—Turbidity with production of gas.

Of the subcultures made from the guinea-pig, only those from the caseous matter showed the bacillus.

A second guinea-pig was inoculated from the subcultures, this developed a boggy swelling over the abdomen at the site of inoculation, with some thickening of the abdominal wall. This swelling eventually burst and was found to have contained serum, but no pus, and the animal was fairly lively.

Cultures made from this serum gave similar results to the original cultures.

The guinea-pig recovered.

The final experiment of inoculating a rabbit intravenously gave indisputable proof that the bacillus was the B. aerogenes capsulatus.

The rabbit having been inoculated was killed, and put in the incubator; when removed from this next day there had been a large post mortem evolution of gas, so that the rabbit was swollen and distended by it.

Pathological Report.

A small window was cut through the sclerotic, so as to expose the interior of the eye, where was seen lying

in an antero-posterior direction the dart, with its blue feathery end immediately behind the opaque cornea. There was no sign of the lens, and the retina was crumpled up.

The piece of the globe excised to form the window, after dehydration, was embedded and cut in paraffin. Sections were stained by Gram's method, and counter-

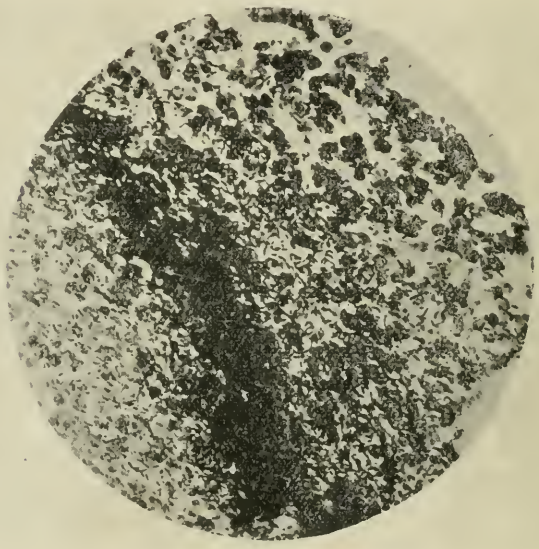

Bacillus Aerogenes Capsulatus in Retina.

Magnification × 500.

stained with eosin. Only a small portion of the coats of the eye was thus available for examination. The sclerotic appeared normal, the choroid was highly engorged and swollen to many times its normal thickness, the retina was also thickened and crumpled.

The rod and cone layer appeared visible in places as

did the external limiting membrane, and there were indications here and there of the outer nuclear layer, but on account of the methods of staining it was not easy to make out much of its structure.

The inner layers of the retina were found to contain enormous numbers of the bacillus lying singly, which could easily be seen with a magnification of 500 diameters.

I am indebted to Dr. Trevor, Pathologist to the Hospital, for preparing the slides, and to Dr. Spitta for taking the photos. This case resembles that reported by me in this year's transactions of the Ophthalmological Society up to the point of inoculation. The growths on milk, potato, etc., are exactly similar, but the inoculation results are very different, for in this case the reaction is entirely local, and in the former, inoculation produced a most rapidly fatal general infection.

The bacillus is a variety of B. aerogenes capsulatus described by Welch in 1892.[2]

This bacillus has been fairly frequently found in cases of acute spreading gangrene, appendicitis abscess, empyema, and mastoid abscess, and is the cause of the curious post mortem appearance known as foaming liver.

I have not been able to find any cases where it has been responsible for panophthalmitis recorded in the literature, though the descriptions of cases from France of such cases due to the bacillus perfringens are identical with this, and I look upon the bacillus perfringens as another name for B. acrogenes capsulatus. Cases have been reported from France by Chaillous, Darier and Oreste.[3]

REFERENCES.

1. James. *Lancet*, 1907.
2. Welch, in Sternberg's "Bacteriology," 1898.
3. Chaillous. *Annales D'oculistique*, 1905.
3. Darier. *La Clinique Ophthalmologique*, 1906.
3. Oreste. *Annales D'oculistique*, 1910.

REVIEWS.

ORESTE. **Penetrating Wound of the Globe by a Blow from a Whip. Infection by the Bacillus Perfringens.** *Annales d'Oculistique*, Jan., 1910.

THE writer records the case of a man of thirty years of age who was struck in the right eye by the lash of a whip, eight days before admission.

On admission, the lids were red and inflamed, especially along their free borders, and there was a brownish discharge from the conjunteiva. On exposing the lower fornix a blackish body about 1 centimetre long was found lying there; this was removed and found to be a portion of the lash of a whip.

There was much chemosis; the cornea except for a narrow margin had ulcerated away, and the perforation was occupied by iris and yellowish exudate.

The man was much depressed and had the aspect of a patient suffering from peritonitis, he had had much pain and had vomited frequently. The left eye was normal.

Enucleation was at once performed, and in view of the nature of the injury a prophylactic dose of antitetanic serum was given.

The temperature, which was 38°C. before the operation, rapidly came down to the normal.

Bacteriological examination: Smear preparations were at once made from the exudate lying in the corneal perforation, in which were found the following elements: (1) Cocci; (2) Short gram positive bacilli, taking the stain feebly; (3) Stumpy thick bacilli, staining intensely with gram; (4) Sarcinæ; (5) Degenerated cells.

Cultures were immediately made from the infected vitreous, both ærobically and anærobically on agar. After 24 hours in

an incubator at 37°, the agar was dislocated by an abundant production of gas, and in the spaces formed by the gas could be seen a turbid liquid which on being microscopically examined, was found to contain a diplococcus, and the same stumpy bacillus found in the smear preparations. The tubes smelt strongly of butyric acid. A milk tube which had been inoculated showed coagulation with an acid reaction. . Gelatine was not liquefield. The stumpy bacillus proved to be a strictly anærobic microbe, and it never grew on the ordinary media in contact with air.

Morphologically it was found to be a large bacillus with square extremities, lying sometimes alone, and occasionally in pairs, it was surrounded by a clear space, a capsule negative, due to shrinking of the background. It was immobile. Two rabbits were inoculated, the first received ½ cc. of a bouillon culture subcutaneously. The next day large bullæ had made their appearance under the skin of the rabbit, and these bullæ crepitated on pressure, and on the following day suppuration had set in at the site of inoculation; eight days later the skin had sloughed. The bacillus was therefore the bacillus perfringens. From the first mentioned tubes a diplococcus with peculiar characteristics, and a bacillus presenting the morphological and cultural characteristics of the B. subtilis were separated.

On examining the enucleated eye it was found that the cornea was practically non-existant, and that the vitreous was infiltrated with pus cells; the iris was much congested, and there were many hæmorrhages into its substance. Similar hæmorrhages were found in the ciliary body and choroid. The sclerotic was much congested, and not a trace of retina remained.

Oreste comments on the rarity of panophthalmitis occurring after injury to the eye by means of blows from the lash of a whip, which he points out is a fairly frequent accident.

Vigier has reported a case in the *Annales D'oculistique*, and he has had a bacteriological examination made of a whip lash, with the following results:—

Ærobic varities: Bac. subtilis; Bac. terus; Bac. mesentericus vulgatus; a yellow coccus; Bac. mycoides.

Anærobic varieties: Bac. butyricus; Bac. pseudo-tetanus; Staph. parvulus; Bac. liquefacicus magnus.

Orestes points out that to this list of special micro-organisms in such a case as injury by whip lash must be added those which are often found in the conjunctival sac, as well as the

pneumococcus, which latter can be accounted for, by the habit drivers have of moistening the lash of the whip with their saliva.

Orestes refers to the observation of Chaillous on panophthalmitis due to a gas-forming organism. The writer looks upon the B. perfringens as playing the preponderating role in this case, and thinks that the B. subtilis played a subsidiary part favouring the anærobic development of the perfringens.

R. R. James.

W. Uhthoff (Breslau). **Cataract—Operation in Diabetics.** *Bericht, u.d. 35, Versammlung der Ophthal., Gesellschaft,* Heidelburg.

In the paper read before the Heidelberg Congress, Uhthoff gives an interesting account of his experience in the operative treatment of cataract in the subjects of diabetes. Some statistics of his cases have already been published in the *Klin. Monatsbl. f. Augenheilk.*, Bd. 46, by one of his assistants. The results obtained by Uhthoff are very satisfactory, much more so than those recorded in some earlier papers: they will in fact compare not unfavourably with the results of cataract extraction in non-diabetics.

Uhthoff finds that about 5 per cent. of all his cataract extractions are in diabetics; and that of his total number of cases of eye disease "diabetic cataract" is met with in 0·12 per cent. Presumably he uses the term dabetic cataract in a wide sense, meaning thereby all examples of cataract occurring in patients with glycosuria.

The proportion of cataract-operations in diabetics to those in non-diabetic patients was much higher in his private than in his hospital practice. This is probably the experience of most ophthalmic surgeons.

In reference to technique and after treatment in these cases Uhthoff has practically followed his usual routine. He is not in favour of a strict anti-diabetic regimen before or during operative treatment in patients who have not been previously on a special dietary. As in non-diabetic cases, he orders absolute rest in bed for one day, and allows the patient to sit up in a chair from the second day onwards. His usual method of operating is by a peripheral flap section with a conjunctival flap. He does not perform preliminary iridectomy, and as a

rule he now does a simple extraction, instilling a half per cent. solution of eserine at the termination of the operation. In his earlier cases he performed extraction with iridectomy, but recently has relinquished this method in favour of simple extraction. Since the regular application of eserine after the operation he has had very little trouble with prolapse of iris.

The total number of cases operated upon by Uhthoff was 115, and of this number not one eye was totally lost, although in two instances no useful vision was regained, one patient having only p. l., and the other being able to count fingers at 1 metre. The former of these two cases occurred in a man who had arterio-sclerosis, albuminuria, and gangrene of one leg. One patient, a woman aged 42, who was doing well surgically, died on the fifth day of diabetic coma. In this case no serious disturbance of health had been noted before the operation was undertaken.

The following are the percentage results of vision in the 115 cases:—

Vision 1 to $\frac{1}{3}$	68%
,, $\frac{1}{4}$ to $^1/_{10}$	18%
,, less than $^1/_{10}$	14%

One of the most frequent complications was iritis: this occurred in a severe form, sometimes accompanied by hypopyon, and in a mild and easily controlled variety, the former being the more common. Maceration of the pigment layer of the iris was a marked feature in these cases, the iris afterwards showing the characteristic appearance first noted by Snellen. This alteration in the pigment epithelium did not appear to have any serious effect on the healing of the tissues.

In the following table are given the percentage occurrence of the more important complications in Uhthoff's series:

Severe iritis (3 times with hypopyon)	6%
Mild iritis	5·4%
Post-operative glaucoma, after retinal hæmorrhage	0·9%
Detachment of choroid	0·9%
Hæmorrhage in a.c....	8·9%
Retinal hæmorrhage	4·5%
Hæmorrhage into the vitreous	1·8%
Diabetic retinitis	2·6%
Albuminuric retinitis	0·9%

J. B. L.

C. Stedman Bull (New York). **The Adverse Influence of Diabetes in Certain Operations on the Eye.** *Trans. American Ophthal. Soc.* 1909.

This paper is the outcome of the author's observations on all diabetic patients in his private practice made with a view of determining what class of diabetics, if any, are not fit subjects for operative treatment. It contains experiences of practical interest to ophthalmic surgeons, and gave rise to a prolonged discussion by the members of the Society before which it was read.

Before giving a resumé of the statistical and other results published by Bull, it will be profitable to abstract some of the important statements in the earlier part of his article.

It is well recognised in general surgery that certain types of diabetics are intolerant of operation. The wounds do not heal, or become gangrenous. Other patients again whose general condition cannot be distinguished clinically from the above do unusually well after operation, their wounds healing promptly.

Diabetic patients are generally anæmic, the percentage of hæmoglobin is reduced, and as a result there is a lowered resistance power.

The diabetic condition is frequently associated with general arteriosclerosis, and with tuberculosis, and the relationship is more than accidental. The arterio-sclerosis is probably an important, perhaps the most important, factor in the causation of the recurrent intraocular hæmorrhages which have been so often observed.

Most writers have advised the postponement of all operations, except those of urgency, until the urine is free from sugar. But recent investigation has shown that it is not the amount of sugar, or even its presence, which is of the greatest importance, but rather the amount of acetone, diacetic acid and beta-oxybutyric acid present, which gives a more accurate idea of the condition of the patient. Analysis may show little or no sugar in the urine and yet the odour of acetone in the expired breath may be very strong,—an evidence of the abnormal product of decomposition of glucose.

It is not wise to make any marked change in the diet of a diabetic patient immediately before operating.

The complications after operations on diabetics which have been most frequent in Bull's experience are iritis, hæmorrhage into the a.c., or infection of the wound, manifested by slow

healing. In the cases of iritis, there was a marked maceration of the pigment epithelium of the iris, a condition originally noted by Snellen. Bull found a rather marked tendency to infection by micro-organisms after operation, and suggests that it would be well to have tests made of the bactericidal properties of the blood serum in diabetes.

Bull's cases, 115 in number, were: Extraction of cataract, 62; Preliminary iridectomy, 40; Optical iridectomy, 9; Iridectomy in chronic glaucoma, 4.

Of the 62 extractions, 40 were for senile cataract, in patients 65 years of age and upwards. All were extractions without iridectomy, and all the patients recovered without serious complications, though the wound healed slowly in 11 cases. In 10 of the 40 cases careful records of the heart, arteries and arterial tension had been kept. These 10 patients had degenerate arteries and high tension and in all of them healing occurred very slowly.

The remaining 22 cases were examples of pure diabetic cataract, in patients between 36 and 40 years of age. Each case was under treatment and the percentage of sugar was reduced to a minimum, and an endeavour made to eliminate as far as possible acetone, diacetic acid and oxybutyric acid before operation was undertaken. In 6 of the 22 cases profuse hæmorrhage into the a.c. took place, with several recurrences. In 2 there were retinal hæmorrhages. In 6 an obstinate iritis without much exudation. In the remaining 8 cases no complications occurred.

The cases of preliminary iridectomy, 22 in senile cataract and 18 in true diabetic cataract, gave but little trouble. In 3 cases (senile) annoying hæmorrhage into the a.c. occurred and the wound healed very slowly. All three patients showed general arterio-sclerosis.

The 9 iridectomies for optical purposes were performed on young diabetics, and all did well with one exception, a female, æt. 22, in whom the operation was followed by severe iritis with abundant exudation.

The last group contained 4 cases of chronic glaucoma in diabetics, treated by iridectomy. Operation was undertaken at a time when the urine contained little or no sugar and only a minute percentage of acetone and diacetic acid. All 4 cases did badly and one patient fell into collapse and nearly died. Profuse hæmorrhage into the a.c. occurred and recurred in all the cases, but there was no retinal hæmorrhage. In one in-

stance delirium set in on the 3rd day, but passed off in twenty hours without the supervention of coma. This patient died of diabetic coma, 8 months later.

J. B. L.

RUDOLPH SCHNEIDER. **Experimental Researches on the Action of "Leukine" in Infective Ophthalmias.** *v. Grafe's Archiv für Ophthalmologie*, lxxiii., 2, p. 223.

THE interest of this paper for ophthalmic surgeons lies first in the demonstration of the inactivity of normal lacrimal and conjunctival secretion as a bactericide, and secondly in presenting a rational hypothesis to account for the beneficial effect of nitrate of silver and sulphate of zinc in infectious ophthalmia.

The journals are full of various hypotheses as to the active agents in the production of immunity, and strange terms, opsonins and aggressins, antiagressins, alexins, leukines, bacteriotropins, antibodies, etc., are revolving in uncertain circles in the medical atmosphere.

The particular substance treated of now is a product of the polynuclear leucocytes. It differs from alexin, which circulates in the blood, in being thermostable, and affecting organisms which are not affected by blood serum.

As regards the lacrimal and conjunctival secretion it has been found by Bernheim that the tears in keratitis and conjunctivitis are antagonistic to various organisms, staph. pyogen. aur. and B. subtilis for instance. Blood serum on the contrary has no effect upon staph. pyog. aur. The tears too can be heated to 58° without losing their powers. Bach's experiments tend to similar results. Alstroem found tears in phlyctenular ophthalmia active against staphylococci, while the pure tears from a fistula of the lacrimal gland had no effect upon any microbes examined.

From the above and other publications on the subject it is pretty certain that the principal defence the conjunctiva receives from pathological organisms is the physiological washing it gets from winking. But several observers have recorded an action of the secretion upon certain microbes, staphylo-, strepto- and pneumococci, and noted that the active agent is thermostable. The subject is therefore worthy of further investigation.

Schneider's method of collecting the secretion is to insert sterilised cotton wool beneath the lids for long enough to pro-

cure sufficient fluid for the experiment. This is centrifuged and a definite quantity added to a culture tube containing bacilli. At stated intervals inoculations of plates are made from this culture with a wire loop, and the number of colonies so obtained counted. The blood serum was similarly tested, and both agents tested again after heating for 1 hour to 56°. The experiments were as follows:

Typhoid bacillus: No effect from ocular secretion heated or unheated, but the unheated serum reduced growth markedly.

Staphylococcus pyogenes aureus: Ocular secretion inactive.

Streptococcus: Neither serum nor ocular secretion active.

Pneumococcus: Serum inactive, but ocular fluid lessened growth after some hours, owing, Schneider believes, to exhaustion of nutritive material.

Diphtheria bacillus: Both fluids quite inactive, as also in case of the allied Xerosis bacillus.

Diplobacillus: Ocular fluid quite inactive, while both rabbits' and human serum destroyed growth in one hour.

Meningococcus: Rabbits' serum active, ocular fluid inactive.

Fresh experiments with pneumococci showed the ocular fluid in one case to act just as physiological salt solution, and in another to exhibit a slight restraining action on the growth.

Schneider therefore concludes that there is no bactericidal substance in the normal lacrimal or conjunctival secretion.

But it is otherwise with the secretion produced under abnormal conditions, in disease and after application of irritants.

The astringents tested by Schneider are nitrate of silver, protargol, and sulphate of zinc.

Astringents have played a great part in our therapeutics, but in our ignorance of the ætiology of conjunctivitis generally, an explanation of their action was difficult. Attention was practically confined to the symptoms, redness, swelling, secretion, and the accepted theory was that the superficial slough caused by the drug carried away diseased cells from the mucous membrane, and the newly formed cells had a better chance of health. In later years of course the explanation has been "antiseptic," and the conjunctiva has been douched with weak dilutions of the most powerful antiseptics both in disease and as a preliminary to operation, on the hypothesis that any good result to be gained depended on the direct action of the drug on the microbes. Schneider's experiments give us seemingly for the first time a rational explanation of the beneficial action of these drugs.

As a sample experiment, instillation of a drop of silver nitrate 1 per cent., washing out with salt solution. Fifteen minutes later secretion collected, and centrifuged. (A second collection made after an hour.) Definite quantity of the secretion added to a tube containing a definite amount of typhoid bacilli in salt solution with a little bouillon added. At stated intervals inoculation of agar plates from this tube by means of a wire loop of definite size, and counting the number of colonies produced by each inoculation.

Rabbits' serum was tested similarly, and both the serum and the secretion heated for $\frac{1}{2}$ hour to 56°, and then tested.

The conjunctival secretion heated or unheated stopped all growth of typhoid bacilli in one hour, while the serum was inactive. (For the quantities of the agents in each experiment the original must be read.)

Of course pains were taken to exclude any possibility of the effect being due to the silver nitrate or other drug employed remaining in the conjunctiva.

Experiments were made with staphylococci, pneumococci, streptococci, meningococci, diphtheria and xerosis bacilli, and the same results were practically obtained in all cases.

Schneider found that even a $^1/_{10}$ per cent. solution was strong enough to produce definite bactericidal properties in the secretion. Protargol in 10 per cent. solution acted similarly.

The explanations usually given of the action of nitrate of silver are either that it contracts the blood vessels, thereby lessening blood supply, or that the slough carries off diseased cells and microbes, or that it acts antiseptically. The real truth is its effect is only good in as much as it promotes the emigration of leucocytes, and the formation of leukine.

That weaker solutions are as effective in promoting the formation of leukine as the stronger onés in common use is shown by other experiments. $^1/_{10}$ per cent. of nitrate of silver is sufficiently strong to produce marked bactericidal properties.

As it is on the production of leukine that the effect depends it is quite logical to employ silver nitrate in affections with profuse production of leucocytes in the secretion, for there may be quantities present as in dacryocystitis without any leukine formation. Without leukine in the fluid the leucocytes have a poor chance against the microbes, and the effect of the drug is said by Schneider to be to make the cells give off their leukine.

The same uncertainty as to the mode of action of sulphate of zinc exists. Schneider finds that it too developes leukine in the

secretion, and this effect is present even when used in $^1/_5$ per cent. concentration.

Schneider made some experiments on the human conjunctiva in addition to the above, which were made on rabbits, and obtained similar results.

The principle conclusions are as follows:—

(1) The normal secretion of the lacrimal gland and the conjunctiva contains no substances with bactericidal, hæmolytic or opsonic properties.

(2) After instillation of silver nitrate, protargol, and zinc sulphate leucocytes pass into the conjunctival sac, and under the influence of these reagents give off their bactericidal product, viz., leukine.

(3) The curative action of the so-called astringents depends not upon the production of a slough nor upon their disinfecting properties, but upon their power of producing leukine.

(4) The destruction of the infective microbes occurs chiefly extracellularly in the conjunctival secretion owing to the leukine in it, and not to the alexin, which is inactive against most of the pathological microbes of conjunctival inflammations.

Schneider as the result of his investigations distinguishes leukine from alexin. The former is derived from the polynuclear leucocytes, and is more an active secretion than a product of their destruction.

It differs from alexin, which circulates in the blood not alone in its thermostability, but in its action upon micro-organisms which are not affected by blood serum.

He has stated in a previous paper that the mononuclear leucocytes join in phagocytosis, but neither bactericidal nor hæmolytic substances can be extracted from them.

J. B. S.

Dr. Carl Fisher. **The Differentiation of the Diphtheria Bacillus from Organisms Morphologically Similar.** *Knapp's Archives of Ophthalmology*, Nov., 1909.

The method of differentiation employed was that described by Knapp, whose work, owing to the absence of any mention of the virulence of the organisms tested, is open to criticism and seems to require confirmation. Fisher considers that the fact that diphtheria-like organisms may readily be mistaken for the Klebs-Löeffler bacillus is not generally appreciated. Knapp stated that the diphtheria, xerosis, and Hoffman's bacillus could

be differentiated by their action upon media containing dextrin and saccharose: that the diphtheria bacillus ferments dextrin not saccharose, the xerosis saccharose not dextrin, and Hoffman's bacillus neither. Recognising the defects which have rendered so much of the extensive literature on this subject valueless, the author has taken the following precautions. All strains have been tested for virulence by injection into guinea pigs, the water of condensation from serum cultures being used, as containing little or no sugar, lest toxin production be prevented. The protective value of antitoxin against the virulent organisms was also in most cases confirmed. Sugar media suitable for the growth of the organism have been used, and that this has taken place without contamination has been tested by plate cultivations. The conclusions arrived at are not identical with those of Knapp. No effort has been made to differentiate the non-virulent organisms by their morphological or cultural characteristic. Forty-two organisms were investigated, of these twelve were virulent to the guinea pig. All these fermented dextrin within twenty-four hours, and failed to ferment saccharose. Of the non-virulent organisms, five fermented dextrin only, fourteen saccharose only, and eleven fermented neither sugar. Fisher concludes that as far as these observations are concerned virulent diphtheria bacilli always ferment dextrin, never saccharose, but that this reaction is not distinctive; that the absence of dextrin fermentation would be valuable as negativing the diagnosis of diphtheria, were it not for the difficulty, and loss of time often entailed in isolating the organism in pure culture, for which reason he considers the inoculation of guinea pigs preferable.

B. H. Wedd.

E. Delord and J. Revel. **Two Cases of Epithelioma of the Bulbar Conjunctiva.** *Annales d'Oculistique*, Dec., 1909.

These two cases are quoted in detail in order to prove the views held by the two authors, which will be referred to later, after giving a brief outline of the description of each case.

Case I. R. B., a man aged 52, whilst engaged in his occupation as forester was pricked in the left eye. The accident was followed by a redness of the eye, internal to the cornea, and at this spot there afterwards developed a small lump. He sought advice for this condition and when examined, a small tumour, about the size of a pea, was seen situated midway

between the cornea and the caruncle. It was strictly limited and freely moveable over the underlying sclera; it caused no pain. The patient refused to have it removed, but six months later returned for further advice, when it was found that the aspect of the case had considerably altered. The palpebral conjunctiva was normal, also the superior cul-de-sac, but the lower cul-de-sac was swollen, apparently by a neoplasm. The original tumour had increased to the size of a haricot bean and was now adherent to the underlying tissue. It was very hard and dark red in colour, but caused no pain. From the tumour two prolongations extended over the limbus above and below the cornea. The margin of the cornea in proximity to these extensions of the growth was greyish and infiltrated. The limbus was infiltrated through $^4/_5$ of its extent. The central part of the cornea, the pupil, iris and anterior chamber were normal. V. = 0·4.

The man now consented to an operation, and a complete exenteration of the orbit was performed, leaving the lids intact. He was seen again 8 months later and no recurrence had taken place.

Examination of Growth. A transverse section was made through the eye and growth. Macroscopically, no breach of continuity of the coats of the eye or invasion by the neoplasm was observable, but the growth had extended back into the orbit below the globe as far as the optic nerve.

Microscopically, the growth was found to be an epithelioma. The canal of Schlemm was nearly filled with the malignant cells. The ciliary muscle and processes were also infiltrated. In the region of the limbus epitheliomatous cells were seen to be penetrating through the substance of the sclera. The cornea and rest of sclera were free from growth.

Case II. M. C., aged 80, complained of the left eye being red and painful for about one month. There was no history of traumatism. A slight red swelling was present in the region of the limbus at the inner side of the cornea: the remainder of the conjunctiva was normal, also the cornea, iris and fundus.

The diagnosis being doubtful the patient was sent home, but returned 15 days later, suffering from great pain and spasmodic entropion of lower lid. The eye presented little further alteration in appearance, except that the redness had spread to the lower part of the conjunctiva. A portion of the tumour was removed for the purpose of examination and was found to be an epithelioma. Enucleation was performed a few days later,

a large area of the bulbar conjunctiva also being removed. A year later no trace of recurrence was observable.

Examination of Tumour. Macroscopically, the eye was normal in volume, form and consistence. The growth was very hard to the touch and scarcely moveable. When a horizontal section was made through the eyeball and tumour, it was found that the neoplasm extended some distance from the limbus over the cornea, being about 2 to 3 cm. in thickness. At the limbus itself, the growth was thicker and in the filtration angle at this point was seen a small mass of new growth, the size of a pin's head.

Microscopically. At the limbus, where the growth originated, a typical epithelioma was seen, while extensions of the growth penetrated the neighbouring regions of the cornea and sclera. The canal of Schlemm was nearly filled with the cells of the growth and in the ciliary processes and muscle similar cells were also to be seen: and some had invaded the anterior chamber.

There was also a backward extension of new cells between the choroid and sclera for some distance.

The points to be especially noticed are:—

(1) An epithelioma was present which tended to take a peribulbar formation.

(2) The external surfaces of the cornea and sclera were macroscopically and microscopically intact.

(3) The growth however had found its way through the region of the limbus and gained the interior of the eye.

(4) On this account, the malignance of the growth was considerably increased and necessitated removal of the eye.

Stress is laid on these points because certain observers hold views which differ from the writers of this article. Valude, for instance, regarded such growths as benign and thought that they extended superficially, without penetrating the eyeball. And many other ophthalmologists (Fage, Lepage, etc.) considered that a complete ablation of the growth itself was sufficient.

The cases quoted show:—

(*a*) Epithelioma of the bulbar conjunctiva generally arises between the cornea and inner angle of the eye.

(*b*) The growth extends principally in the region of the limbus, but may spread around the fibrous coats of the eye.

(*c*) In the latter case the growth does not pentrate the tunics of the eye except at the limbus.

(*d*) Consequently it is extremely difficult to define the extent of the lesion, as the growth, *quite early*, may have penetrated the eye in this region.

(*e*) The limbus is the weak spot in the cuirasse: for it is here, by means of the lymphatics, that the neoplasm is enabled to gain the interior of the globe.

(*f*) If the growth is merely on the sclera it may be removed locally, but if the *limbus* is affected enucleation should always be performed.

WILFRID ALLPORT.

M. E. VALUDE. **Neuro-fibroma of the Orbit Developed at the Expense of the Frontal Nerve.** *Annales d'Oculistique*, June, 1909.

THE author describes a case of neuro-fibroma of the orbit which occurred in a woman aged 34. Twelve years previously she noticed a small swelling the size of a pea below the superior margin of the left orbit. The tumour gradually increased in size without the least pain and without inflammatory phenomena. When seen by Valude she presented a small prominence at the middle of the upper eyelid, the prominence was of such a size as might be caused by an object the size of a hazel nut under the skin. To the touch the tumour felt fairly firm and was prolonged under the orbital margin outwards till it was lost in the depth of the orbit. It did not appear to be adherent either to the eye or the walls of the orbit, there was no exophthalmos and the movements of the eye were easily executed. The eye itself was normal and the visual acuity was good.

After an incision of 3 cm. in length over the prominence of the tumour, a smooth mass was found extending backwards into the superior part of the orbital cavity. The mass which terminated in a thin extremity was cut through at a depth of 2 or 3 cm. behind the superior orbital margin.

On histological examination of the tumour it was found to resemble those which are observed in the lesions which are called neuro-fibromata. A month later the patient returned well satisfied with the result of the operation, but related that she experienced a feeling of formication in the left side of the forehead; she also remarked that she did not feel when she

was pricked on the left side of the head. An examination of the zone of anæsthesia showed that the region of distribution of the external frontal or supra-orbital nerve was affected. The conservation of the sensibility of the palpebral conjunctiva of the upper lid proved that the internal frontal was not affected, and seemed to show that the tumour did not extend as far as the principal trunk of the frontal nerve.

E. M. Lithgow.

Cabannes (Bordeau). **Congenital Buphthalmos in Relation to Hemi-hypertrophy of the Face.** *La Clinique Ophtalmologique*, Sept., 1909.

Dr. Cabanne's observation concerns a girl of 6 years, who since her birth presented an enormous increase in the volume of the face on the right side, especially in its superior parts: eye ball, temporal and superior maxillary regions. This hemi-hypertrophy extended also to the corresponding ear, the right alveolar borders of the superior and inferior maxillæ, and the right side of the tongue. A large deep subcutaneous angioma, formed by a leash of apparently obliterated vessels, occupied the greatly enlarged temporal region. All the neighbouring bones were about three times the size of the corresponding ones on the other side. The right orbital cavity was considerably enlarged in size. The right eye ball was at least twice as large as the left, and was habitually covered by the drooping and hypertrophied upper lid. The cornea was somewhat opaque and internally a slight pannus existed. The anterior chamber was deep, the pupil dilated and immobile. The lens cataractous, the vision lost, the tension was not increased. The left eye was healthy. The right eye was enucleated and on examination showed that the disc was physiologically excavated. The angle of filtration and the canal of Schlemm were normal in appearance. The iris, ciliary body, the choroid and the retina presented signs of atrophy without traces of inflammation. The angioma of the temporal fossa had certainly originated the hypertrophy of the parts affected.

To the two theories commonly put forward as to the pathogenesis of congenital hydrophthalmos, Dr. Cabbanes adds a third, to which he gives the name of congenital hypertrophic malformation of the eye, and supports his case by the following arguments:—

(1) Other congenital defects coexist with hydrophthalmos:

Defective conformation of the skull, pupillary displacement, epicanthus, irideremia, with at times absence of the ciliary body, partial coloboma of the iris, the coexistence of six toes or fingers, etc.

(2) The anatomical study of the case described, where there existed no trace of inflammation of the uvea, or of closure of the iris angle, where the canal of Schlem and the spaces of Fontana were absolutely permeable, and where no hypertension was evident, requires some other and more general cause than those hitherto invoked. In the case under discussion the facial hemihypertrophy and the corresponding buphthalmos were dependant on the large angioma of the temporal region. The increase in the size of the eye must be due, like that of the face, to hypernutrition of the neighbourhood.

E. M. Lithgow.

Schanz and Stockhausen (Dresden). **On Dazzling.** *v. Graefe's Archiv für Ophthalmologie*, 71, 1.

Schanz and Stockhausen have published during the last two years several papers dealing with the subject of the action of light, especially of ultra-violet light, upon the eyes; and they have introduced a yellowish green glass, called euphos glass, for the protection of the eye from the action of the ultra-violet rays. Euphos glass absorbs all ultra-violet rays while diminishing but slightly the intensity of the luminous rays.

In the paper under review they record some further observations upon the action of ultra-violet rays upon the eye and discuss at length the part played by these rays in the production of the phenomena of dazzling.

It is well known that ultra-violet rays excite fluorescence of the lens. The authors find that this fluorescence is almost completely prevented by placing between the source of light and the eye a Wood's filter, which, at a certain dilution, absorbs ultra-violet rays of wave lengths between 400 and 375 $\mu\mu$ while allowing those of shorter wave lengths than 375 $\mu\mu$ to pass in almost undiminished intensity. It is therefore rays of a very limited region of the spectrum, those of wave lengths between 400 and 375 $\mu\mu$, that are mainly responsible for the production of fluorescence in the lens.

In a former paper the authors stated that fluorescence of the lens diminished after long exposure to ultra-violet rays. They now attribute this diminution in fluorescence to changes occur-

ring in the cornea and aqueous since it does not occur, even after prolonged exposure, in the case of a lens removed from the eye.

By spectrographic observations they have determined that rays of wave length less than 375 $\mu\mu$ are absorbed by the human lens to a high degree in youth and completely after middle age. These rays, however, cause little or no fluorescence. Therefore the absorption of ultra-violet rays by the lens is not entirely dependent on conversion of ultra-violet into fluorescent light. A large part of the ultra-violet rays is absorbed without giving rise to fluorescence, and the fluorescence is not proportional to the total amount of ultra-violet light absorbed. Fluorescence occurs also in the retina when the eye is exposed to ultra-violet light. This must be caused mainly by rays of wave lengths from 400 to 375 $\mu\mu$, for rays of shorter wave length are absorbed by the lens almost completely in youth and totally in later life.

The following table is given showing the action of light rays of different wave lengths upon the eye:—

Visible Rays: Red, Yellow, Green, Blue, Violet.	Invisible Rays: Ultra-Violet.		
I.	II.	III.	IV.
	Wave Lengths.		
760—400 $\mu\mu$	400—375 $\mu\mu$	375—320 $\mu\mu$	320 $\mu\mu$ . . .
Reach the retina unchanged, are invisible	A part is changed into fluorescent light in the lens, a part is absorbed by the latter, a larger part, however, reaches the retina, where it is in part changed into fluorescent light, and in part perceived as lavender grey.	Take little part in causing fluorescence of lens. They are absorbed to a great extent by the lens, and reach the retina in much diminished intensity only in youth.	Do not penetrate the cornea, but are specially active in exciting inflammation in external eye. Average limit of absorption by glass, 300 $\mu\mu$.

Discussing the influence of ultra-violet rays in producing the symptoms of dazzling, the authors express the opinion that the fluorescence excited in lens and retina plays an important part. It causes blurring of the retinal image, just as diffuse light in a camera causes fogging of the photographic image. It is irritating to the retina, as shown by the brisk pupil and lid-closure reflexes excited by it. It probably causes rapid fatigue of the retina by exhausting the visual substances. These

are deleterious influences deserving serious consideration even though it is not proved that they may cause grave lesions.

Long exposure to light rich in ultra-violet rays causes erythropsia and, as shown recently by Birch-Hirschfeld, disturbance of the colour sense. The only ultra-violet rays that can be concerned in causing these symptoms are those of wave-lengths from 400 to 375 $\mu\mu$, since these are the only ones which reach the retina in appreciable quantity. Luminous rays may play a part in the production of these symptoms. No sharp distinction can be drawn between the physiological action of the visible and invisible rays; it is the same in all regions of the spectrum, but its intensity is inversely proportional to the wave-length of the rays.

The authors review the principal experimental and clinical evidence with regard to the action of ultra-violet rays on the lens and refer to the possibility that senile cataract may be due to the action of these rays. They admit that there is no proof of this, but emphasise the fact that a large proportion of ultra-violet rays, in daylight as in artificial light, is absorbed by the lens, and that these rays possess very great physiological activity. Birch-Hirschfeld failed to produce lens changes in rabbits' eyes by 150 times repeated exposures of ten minutes duration to intense ultra-violet light. But the authors consider that these experiments do not in the least disprove the possibility that cataract formation may depend upon relatively rapid wearing out of the lens fibres as the result of life long action of the ultra violet rays. In the above-mentioned experiments of Birch-Hirschfeld conjunctival changes were produced similar to those seen in the human conjunctiva in spring catarrh. The authors remark that if spring catarrh is due to ultra-violet rays it must be due mainly to rays of wave length between 320 and 300 $\mu\mu$ as rays of shorter wave length are almost wanting in daylight, except at high altitudes, and rays of greater wave length have but little irritant effect on the conjunctiva.

It is advisable to wear glasses absorbing all rays of wave-length less than 400 $\mu\mu$ for the prevention of snow blindness and where working by the light of modern lights containing a large proportion of ultra-violet rays; and this too even when the light is of moderate intensity, if the eyes have to be exposed to it for long, because the fluorescence excited in the lens and retina may cause discomfort. The increased clearness of vision in bright daylight obtained by the use of amber glasses is

attributed largely to the absorption of ultra-violet rays by these glasses, which prevents fluorescence of lens and retina and the consequent blurring of vision. Euphos glass is recommended as being better than any other for this purpose since it possesses the highest power of absorption for ultra-violet rays, while only slightly reducing the intensity of luminous rays. Euphos glasses are also recommended for cataract glasses. Axenfeld has ordered them for glassblowers after operation for cataract, and patients wearing them have been able to resume their work, whereas formerly such patients had to seek other occupations. Axenfeld and Schanz have found this glass useful in cases of retinitis pigmentosa and for the relief of photophobia. Euphos grey glass is now prepared for use in cases where it is required to diminish the luminous rays as well as the ultra-violet.

The paper concludes with a criticism of Volgi's experiments, who attempted to prove the harmlessness of modern lamps by showing that the proportion of ultra-violet rays in the light emitted by them is no greater than in ordinary diffuse daylight in Hamburg. The authors point out that the Wood's filter used in his experiments absorbs rays of wave lengths from 400—375 $\mu\mu$, just the rays which cause fluorescence of the lens and retina and play the greatest part in the phenomena of dazzling.

W. H. McMullen.

Birch-Hirschfeld. **The Changes Produced in the Eye by Frequent Exposures to Light Rays of Short Wave Length.** *v. Graefe's Archiv für. Ophthalmologie*, 71, 3.

In this paper the author describes the effect on the eyes of rabbits of frequent exposures at intervals of about two days to light rays of short wave length and comparatively low intensity. The source of light was the Schott mercury vapour lamp used for about ten minutes at a distance of ten centimetres. A single exposure with everted lids resulted in an acute conjunctivitis developing about five hours later and persisting for about five days. The discharge contained great numbers of eosinophile cells. As the result of frequent exposures the conjunctiva developed a milky appearance with rough papillary elevations. Microscopical examination shewed that the conjunctival epithelium had assumed the characters of epidermis, and had even, in those cases submitted to very prolonged exposures, developed pigment in the deeper layers. The con-

nective tissue shewed hyaline degeneration, which did not however appear to affect the elastic fibres. Plasma cells were present in considerable numbers. The small blood vessels exhibited both hyaline degeneration of their walls with considerable thickening, progressing in some cases to obstruction of their lumen, and endothelial degeneration associated not infrequently with healthy walls. These appearances closely corresponded with the changes described as occurring after the use of radium, Roentgen rays, high frequency currents, and in spring catarrh. No pathological changes were found in the cornea, lens, or retina. The changes in the conjunctiva were only produced if the lids were everted.

The author points out that although the histological changes produced present many points of resemblance to those met with in spring catarrh, yet they can hardly be regarded as specific for that affection. Moreover in contrast to the changes met with in spring catarrh, those produced experimentally were found to vanish without leaving any trace after the lapse of a few months. It was also noteworthy that in the case of the rabbit no individual hypersusceptibility to the influence of light could be discovered. The experiments may be considered to have some bearing on the liability to relapse of spring catarrh under the influence of sunlight, but to negative the view that sunlight is the primary cause of that affection.

A. C. Hudson.

Dr. A. Rodiet and Dr. P. Pansier. **Vision in General Paralysis.** *Receuil d'Ophtalmologic*, October, 1909.

The authors of this paper discuss the whole question of the vision in general paralytics, summing up the conclusions arrived at by many writers on the subject. There appears to be a good deal of difference of opinion as to the value attaching to the various clinical visual symptoms noticed in general paralysis of the insane. Several observers (*e.g.*, Reznikow, Hirschberg, Galezowski, etc.) consider the general contraction of the field of vision as one of the earliest signs of general paralysis, while others (*e.g.*, Joffroy, Sauvineau and Schrameck) affirm that it is only an apparent contraction, the mental condition of the patients rendering a perimetric examination a matter of considerable difficulty. Again, it is stated by others that this combination of the visual field is common in toxic conditions, *e.g.*, alcohol, tobacco, etc., which are often precursors

of general paralysis, and from their own experiences Drs. Rodiet and Pansier favour this view themselves.

Several writeas (Charcot, Parinaud and Blocq) have thought that another symptom of the early stage of general paralysis is ophthalmoplegic migraine; while others see nothing at all characteristic about the occurrence of this condition, and regard it as a coincidence.

A central scotoma has sometimes been recorded, but this is by no means constant. With regard to the lesions associated with these visual troubles, many have been described, though several of them can hardly be considered peculiar to general paralysis. The combination of amblyopia with negative fundus changes, a sort of papillary œdema (Galezowski), tortuosity of the retinal vessels (Voisin), degenerate lesions in the vessels (Klein), atrophy of the nerve (Bay, Bouchet, Magnan), are a few of the opthalmoscopic appearances which have been considered important.

The examination of these cases histologically reveals a condition of connective tissue development in the retina and around the blood-vessels (Magnan), eventually spreading to the optic nerve, when it produces what Reznikow describes as an interstitial optic neuritis which ultimately leads to atrophy.

As a result of these observations, the authors have formed the opinion that the ordinary amblyopia of general paralytics is a retrobulbar neuritis which progresses slowly, and finally leads to atrophy of the optic nerve; and when visual defects are accompanied by lesions in the fundus the latter are variable and in no way characteristic.

MALCOLM L. HEPBURN.

ANGIOLELLA. **Paraspecific Serotherapy, and Subconjunctival Injection of NaCl in Ocular Infection.** *La Clinique Ophtalmologique,* Oct. 1909.

ANGIOLELLA considers that failure in treatment of ocular infections is due to insufficient vigour, and is enthusiastic in his praise of serum treatment He finds that serum alone may cure, but in some cases the system gets accustomed to it, and the infection process is not completely stopped, but cure in these cases always follows subconjunctival injection of NaCl. He thinks this treatment especially useful in trachomatous ulcers of cornea. The serum he used was Behring's (antidiphtheritic) in doses of 3–5000 units.

Case I. Man, æt. 27, seen 24 November, 1908. Left, abscess of cornea, 10 days duration; hypopyon $\frac{1}{3}$ anterior chamber; great pain and other subjective symptoms; wife has gonorrhœal metritis; condition of cornea probably metastatic and due to gonorrhœa; no lesion of superficial layers of cornea. Nov. 24, 1000 units serum injected, followed by slight diminution of pain. Nov. 27th, 1000 units. Nov. 28th, 1000 units. Nov. 29th, pain now gone, and suppuration is limited, but after two days, the condition remaining stationery, a sub-conjunctival injection of NaCl was given (Dec. 1st) and repeated alternate days. Dec. 4th, cornea more transparent above, no hypopyon. After eleven injections NaCl patient left hospital, with only small nebula of the cornea remaining.

Case II. Girl, æt. 17. Left, trachoma with corneal ulcer just over pupil, severe pain and other usual symptoms. Jan. 8th, 1909, 1000 units of serum injected. Jan. 10th and 12th, 1000 units. After these three injections all pain disappeared, and also all inflammatory symptoms, but as the ulcer didn't clean up well, NaCl was injected subconjunctivally. After 10 injections complete resolution, slight leucoma remaining.

Case III. Man, æt. 36. Right perforated corneal ulcer, with suppuration in vitreous; eye soft; no perception of light; no anterior chamber; *pain intense*. Serum was tried—3 injections of 1000 units, the only effect being that the pain disappeared. NaCl also tried, but eventually eye had to be eviscerated.

Case IV. Blenorrhagic keratitis and panophthalmitis. Man, æt. 59. March 8th, 1909, had catarrh of conjunctiva, and was advised to bathe eye with the urine of a little girl, æt. 10. After 4 days left eye swollen, purulent secretion, and violent pain. On examination cornea found to be necrotic. Right eye, ulceration upper part of cornea with violent pain. March 15th, 1500 units given. March 16th, 1500 units. March 18th, *no pain*, but infection process advancing in left eye. This eye was eviscerated on that day and 1000 more units of serum given. March 21st, 1000 units. After this the right eye got quite well. Angiolella examined the urine of the child later and found gonococci.

Case V. Man, æt. 23. Left corneal ulcer and hypopyon, with trachoma. Serum alone given here (5 injections of 1000 units), resulted in a complete and rapid cure.

Remarks. No cultures made except in one case. The diversity of the cases recorded shows the efficacy of the serum in

different infections. Cases 3 and 4 show that serum is not effectual where vitreous is affected, thus bearing out Darier's statement that advanced infections of vitreous are rebellious to all therapeutic measures. Angiolella specially notes that the treatment is very useful to overcome pain, even when morphia had no effect. He also asserts that treatment by serum and NaCl produces more transparent cicatrices than other methods. The important point is to start treatment promptly.

E. Harries-Jones.

Charles Blair. **Errors of Refraction and their Treatment.** John Wright & Sons, Bristol.

This, the second edition of Mr. Blair's little book, in rather more than one hundred pages, gives a clear and good account of the errors of refraction, and their correction.

The author presupposes a general acquaintance with the laws of elementary optics, and his book is mainly of a practical and clinical nature.

The correction of errors of refraction is a subject that is somewhat overlooked in treatises on ophthalmology; at most a rather dogmatic attitude is adopted, according to the ideas of the particular author, and it is therefore instructive to get the results of the practical experience conveyed in this book.

There is a very useful chapter on spectacles, and a good account of the examination of patients, and although the reviewer doubts very much whether the use of a refractometer facilitates the estimation of errors of refraction, yet he thinks that the book is an excellent one to put into the hands of a senior student, or of one just qualified, who finds himself called upon for a short period to undertake the duties of ophthalmic house-surgeon to a general hospital.

The Medical Annual, 1910. John Wright & Sons, Bristol.

This annual epitome of recent advances in medicine and surgery maintains the high standard of excellence of past volumes. The subject of ophthalmology has been entrusted to Messrs. A. Hugh Thompson and J. H. Yearsley. The latter author contributes six pages on diseases of the conjunctiva, the greater portion of which is devoted to the consideration of ophthalmia neonatorum. Room is also found for a plate showing microphotographs of trachoma bodies. Thompson in the article on paralysis of the ocular muscles gives a modification of the

method of diagnosis, recently described by McNab, which is very clearly explained. In his other articles the author deals with the early diagnosis of chronic glaucoma, by the use of more accurate methods of perimetry, with special reference to Bjerrum's work on the early enlargement of the blind spot area. Under the heading of interstitial keratitis the same writer refers to the recently advocated use of atoxyl, and states, rightly in our opinion, that the drug should not be employed in these cases, as the risk of causing atrophy is too great. He suggests, however, that soamin might be used, as this drug, being free from aniline, is said to be safe from the toxic properties of atoxyl. Recent cases have shewn that this is unfortunately not true, and we hold the opinion that these dangerous arsenical drugs should only be used in such desperate affections as sleeping sickness. We are pleased to see that the connection of iridocyclitis with septic mouth affections receives the attention it deserves.

The work of condensing into little over 700 pages the literature of medicine for a whole year has been admirably performed.

THE OPHTHALMOLOGICAL SOCIETY OF THE UNITED KINGDOM.

Thursday, May 5th, 1910.

President, Dr. G. A. Berry, *in the Chair.*

Case of Traumatic Paralysis of an External Rectus Muscle in a Child, aged 16 months.—Mr. N. Bishop Harman.

W.T., aged 16 months, perfectly healthy in every other respect, was first seen on April 20th, 1910, with complete paralysis of the left external rectus. The history was that six days previously the child had fallen, striking the back of his head, and when picked up both eyes appeared to turn inwards; the mother also noticed that when offered a toy, he would grasp it with one hand and stretch out the other to take another imaginary object, thus suggesting double vision. The interest in this case was the question as to where the lesion was situated; most probably the 6th nerve was torn or stretched by the sudden displacement of the basal cranial bones.

Family Choroiditis.—Mr. G. T. Mould.

Milly R., aged 34, came with the history of misty sight for 6 months, which had lately grown worse. The vision in both eyes was $^6/_9$ partly. Both fundi showed innumerable pale yellow spots, non-pigmented, round about the disc and macula, with some heaping up of pigment near the fovea.

Optic Nerve Atrophy, and Left Temporal Hemianopsia associated with Tumour (? Cystic) of Pituitary Body.—Mr. L. V. Cargill.

W.A.B., male, aged 35, came in October, 1908, for treatment, and on examination it was noticed that the discs were blurred and pale; the vision at that time was finger counting in the right eye, and $^{6}/_{12}$ in the left. He also noticed that he bumped into people approaching him from the left side. In February, 1910, the discs were seen to be pale and atrophically cupped, and the vessels small; R.V. was perception of light, and the L.V. $^{6}/_{9}$ partly; the left field was limited to the nasal half. The patient had observed for the last two years that his hands had been enlarging, and the feet for the last 15 months, together with some alteration in his face and widening of the jaws; the whole head had increased in size, the face being broad with prominent maxillæ.

A skiagram showed marked absorption of bone in the region of the sella tunica such as would be caused by enlargement of a growth in this region.

Optic Atrophy following Injections of Orsudan.—Mr. Ernest Clark.

The patient, who was in the Lock Hospital on October 19th, 1909, had been receiving injections of orsudan gr. x on alternate days, when, after the ninth injection the sight began to fail, and, in spite of the stoppage of further injections, the vision became worse. The pupils reacted normally, though somewhat sluggishly, and the knee-jerks were natural; the vision varied from hand movements to counting fingers.

Ophthalmoscopic examination showed typical primary optic atrophy, but the vessels were not reduced in size, while there were degenerative changes at both maculæ.

Heterochromia Iridis associated with Paralysis of the Sympathetic in Early Life.—Mr. M. S. Mayou.

Mr. Mayou showed 2 cases representing this condition, one case having come under his care at the Central London Ophthalmic Hospital and one at Paddington Green. The first one was a male, aged 3½, who came with a history of drooping of the left eyelid soon after birth, and difference in the colour of the two irides; the right was a brown shade, while the left was a bluish tinge. In every other respect the child was quite healthy. Both pupils reacted, but the left was smaller and did not dilate so fully in the dark as the right, nor did the left dilate under the influence of cocaine; no K.P. was discovered. There was slight ptosis, but little alteration in sweating on that side of the head; the fundi were perfectly normal. Labour in connection with birth had been prolonged, and instruments were used.

The other case was a child, aged 6, at whose birth forceps had been used, who came for treatment on account of drooping of the right

eyelid. The right pupil was smaller than the left, bluish in colour compared with the latter, which was brown; the right pupil did not dilate so fully as the left, and was unaffected by cocaine, which, however, produced the usual effect on the left. There seemed to be some diminution of sweating and lacrimal secretion on that side of the face.

Since this defect was noticeable immediately after birth, it was evident that the normal development of pigment, which does not take place usually till a child is several weeks old, had been arrested; and since in both cases forceps were used during labour, some birth injury suggested itself as the cause in these cases.

Recent Amaurosis with Unusual Cupping of the Disc, in a Youth.—Mr. J. H. Tomlinson.

Coloured drawings were shown of this case, whose vision 11 years ago was $^{6}/_{9}$ in each eye, and to whom glasses of +3 D had been ordered. The sight in the right eye was reduced to no perception of light, while that in the left was $^{6}/_{5}$ with correction. The corneæ measured 11 mm., and there was deep cupping of the discs in both, 7 D in the right and 5 D in the left. The field in the left eye showed slight contraction along the nasal side.

A Case of Congenital Arterial Loop Projecting into the Vitreous.—Dr. A. S. Worton.

PAPERS.

A New Operation for Glaucoma—Small Flap Incision.—Col. H. Herbert.

Col. Herbert described this operation, which he had found very successful for cases of chronic glaucoma, so far as he was able to judge at present. The method employed was as follows:—By means of a subconjunctival incision the sclerotic was entered 1·5 mm. from the limbus, and an opening 2 mm. long was made parallel to the corneal margin, and then from the extremities of this two forward cuts were made, extending up to the limbus; the flap thus formed becomes displaced forwards to prevent reunion, and the small tongue of sclerotic tissue shrinks, resulting in the formation of a filtering scar.

In 1907 Mr. Herbert had operated in this manner on 6 cases, and of the 5 results known, 4 had succeeded and 1 failed; the eyes were mostly blind from absolute glaucoma, and the tension in two of the cases had been very gradually reduced, thus indicating the tendency to a permanent result.

During the last 5 months Messrs. Herbert and Laws had operated on several more cases of a similar nature, and out of 14 recent operations a complete iridectomy had twice been performed in addition to the ordinary flap operation. A special shovel-shapel knife had been devised

for the purpose, though its use had not been attended with altogether satisfactory results.

Mr. Herbert then discussed the results compared with other filtering and fistulous scars, such as his own wedge isolation method.

Congenital Word Blindness.—Mr. J. Herbert Fisher.

This defect is supposed to be due to congenital maldevelopment of the visual memory centre for words, usually resident, in right-handed persons, in the region of the left supra-marginal and angular gyri. Such cases were usually educated by means of a method such as Miss Mason's "Delightful Reading Box."

Mr. Fisher described four cases, three of whom were boys, in which congenital word blindness was present; the visual acuity was good in all cases except in one where there was a squinting eye; in others there was a history of some near relative having a difficulty in spelling correctly, and in one of them the left side of the head and forehead was noticed to be smaller than the right since birth.

The cases may be said to fall into two groups :—

(1) Those in which there is failure of the visual memory centre for words situated in the left angular and supra-marginal gyri.

(2) Those in which the same centre may have been injured by a very limited meningeal hæmorrhage during the stress of parturition.

In the first group there may be found evidence of an inheritance of a familial defect, as in the case previously reported by Mr. Fisher in the *Ophthalmic Review,* 1905, p. 135, and in one of those mentioned in the present paper. If hereditary there was no sex limitation noticed.

The cases belonging to the second group are allied to those following birth injuries. It has been found that slight meningeal hæmorrhage has occurred during parturition and that the condition has been found more common in first-born children, more especially in males. It is a fact that word blindness shows a striking preponderance in male children, and the cause is probably a meningeal hæmorrhage over the region of left angular gyri.

Some Cases of Hypopyon Keratitis treated with Pyocyanese.—Dr. A. Bronner.

Dr. Bronner described six cases of hypopyon keratitis which he had treated by the local application of pyocyanese, a brownish fluid prepared from broth cultures of the bacillus pyocyaneus. In all cases the treatment has proved strikingly successful, but atropine and hot fomentations had been used in addition to the special application. Dr. Bronner considered pyocyanese superior to the cautery or carbolic acid in this class of case.

MALCOLM L. HEPBURN.

AN ERECT IMAGE OF THE FUNDUS BY INDIRECT OPHTHALMOSCOPY.

By G. F. Alexander, M.B., C.M. (Edin.), Major R.A.M.C. (retired).

(1) While with the indirect method of ophthalmoscopy using a +13D lens we obtain an image of a considerable area of the fundus magnified in emmetropia five times, and with direct vision one of a much less area magnified $14\frac{2}{3}$ times, the area in view at one time is sufficiently large for the juxtaposition of parts to be observed only with the former; but as its image is inverted it might in certain cases be desired to obtain such a view in which the parts remain correlated as they are in the fundus.

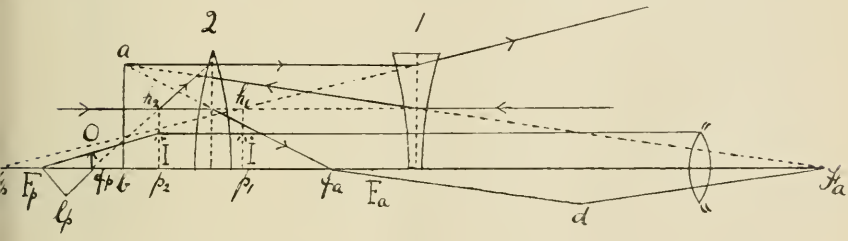

Though admittedly little is to be gained by the following method of doing so, and it is mainly brought forward as of theoretical interest, there are cases such as coloboma of the choroid passing into close relationship with the optic disc in which it seems advantageous.

(2) The application of the principle of Gauss to the combination of a positive refracting surface, *i.e.*, one refracting the rays of a pencil traversing it towards the axial ray, and a negative refracting surface, *i.e.*, one refracting the rays of a pencil traversing it from the axial ray, the two surfaces having a common axis, is illustrated in the accompanying figure where 2 represents the former and 1 the latter.

$\mathcal{F}_a$ and $\mathcal{F}_p$ are the anterior and posterior foci of 1, f_a and f_p the anterior and posterior foci of 2, and F_a

and F_p the anterior and posterior foci of the combination: let $\mathscr{F}_a$ and $\mathscr{F}_p$ also stand for the anterior and posterior focal lengths of 1, f_a and f_p for those of 2, and F_a and F_p for those of the combination. It will be observed that rays parallel to and equidistant from the axis incident from opposite sides on 1 and 2, meet after undergoing refraction at these surfaces at a, and that the construction shows $h_1 p_1$ to be the virtual image of ab given by 1 and ab in turn to be the virtual image of $h_2 p_2$ given by 2, hence $h_1 p_1$ and $h_2 p_2$ become the principal planes of the combination, the posterior focal length of which is the distance between F_p and p_2. Now if l_p represent the distance between F_p and f_p and d the distance between f_a and $\mathscr{F}_a$, and O be an object at the posterior focus of 2, as is the case with the fundus in emmetropia, its image, represented on the principal planes by $\dot{I}$, is seen by the observer's eye in front of 1, the magnification $\frac{\dot{I}}{O}$ being determined as follows:—from similarity of triangles

$$\frac{\dot{I}}{O}=\frac{F_p}{l_p}=\frac{\frac{\mathscr{F}_p f_p}{d}}{\frac{f_a f_p}{d}}=\frac{\mathscr{F}_p}{f_a}.$$

If O is within the posterior focus of 2 as is the case with the fundus in hypermetropia, or beyond it as is the case with the fundus in myopia, its magnification would naturally be less in the former and greater in the latter according to the degree. The proof of the above statements is on the same lines as that given in Donders' and other text books for the combination of two positive refracting surfaces, and being somewhat lengthy is at present withheld.

(3) It thus becomes obvious that if we hold a concave lens of focal length =Fmm. in front of the eye, whose anterior focal length we may take as 15 mm., we will

see through it an erect image of the fundus magnified just as that of the indirect image given by a convex lens $\frac{F}{15}$ times, *i.e.*, for a -13D lens about 5 times. It must be remarked that the principle is altogether different from that of the magnification of the fundus of a myopic eye viewed through a minus lens in direct ophthalmoscopy, as the lens is then used solely to focus the rays on our retina and the magnification depends on the principle of projection. On account of the negative refraction of the lens the illumination of the fundus must be very bright and hence the pupil should be well dilated by a mydriatic, the lens held as close to the eye as possible, and our eye moved within a few inches of it, which, as in emmetropia the image is formed at the focus of the lens, will in the case of our not possessing sufficient accommodation for this distance require a plus lens behind our mirror. A little practice is required to dissociate the attention from the image of the iris and pupil which are necessarily minified. When we desire to obtain a very high magnification of the fundus by the use of a lens of a few dioptres this method is superior to the use of a convex lens for this purpose as the latter requires the removal of our eye backwards to a distance which renders vision impracticable.

REVIEWS.

Sir Victor Horsley. **"Optic Neuritis," "Choked Disc," or "Papillœdema": Treatment, Localizing Value, and Pathology.** *British Medical Journal*, March 5th, 1910.

A main object of this paper is to adduce further evidence in support of the author's contention that in cases of cerebral tumour the changes at the optic discs are more pronounced on the side corresponding to the site of the tumour. If this view should prove on more extended observation to be well founded, then a distinct advance will have been made in the clinical diagnosis of a most important group of cases.

Sir Victor Horsley gives a table of 18 unselected cases of cerebral tumour which had been under his care at Queen Square, and in which the situation of the tumour was determined by operation during the year 1908. Of these cases 15 are quoted as ipsolateral, *i.e.*, with optic neuritis more pronounced on the side of the lesion, one as probably ipsolateral, one as indeterminate, and one as contralateral.

The number of cases cited is of course too small to afford conclusive evidence on the point at issue, still these cases appear to lend considerable support to the author's strongly expressed opinion. One criticism which the reviewer would like to make is that some of the cases seem classed as ipsolateral, *e.g.*, cases 3, 4, 5, on rather slender grounds. Take for instance case 4. The note here is L + 6, R + 5·5 the figures indicating in dioptres the amount of swelling of the nerve head. Surely the difference stated in this case is far too small to be independent of chance errors of observation. A second and equally competent observer might have given a different opinion with regard to the exact relative amount of swelling of the discs. In addition to the 18 hospital cases already mentioned Sir Victor Horsley cites 3 cases from his private practice. Case 2 was contralateral, the neuritis commencing on the right side and being more intense on that side at the time of the decompression operation. After the operation the neuritis became more intense on the left side. The patient died 3 days after operation and post mortem a tumour was found mainly on the left side of the brain. The opinion is given that post mortem evidence seemed to shew that pressure must have been mainly towards the right side and hence the earlier occurrence of neuritis on that side.

Much interest will attach to the view expressed by the author that in cases of choked disc the earliest changes are most commonly to be noted in the upper and inner quadrant of the disc, and further that in pressure dilatation of the optic nerve sheath this dilatation is usually most marked above. If the location of the earliest changes in choked disc is really so definite as Sir Victor Horsley thinks it is, then we ought in future to have less difficulty in giving a definite diagnosis in very early cases.

In regard to the cause of the radiating macular figure which may accompany optic neuritis Sir Victor Horsley is in agreement with Gunn's theory that the radial arrangement is due to tension lines. To test the correctness of this theory he chose an eye obtained from a case of early choked disc, first fixed the

fundus in osmic acid, formalin, and absolute alcohol and then subjected the specimen to drying. As the drying proceeded "the retina began to crinkle in a star-shaped pattern, the centre of which was the fovea." Under the microscope the intima was found raised, the effect of the altered tension having been first felt in the nerve fibre layer.

A careful histological examination was made of the whitish retinal areas so often seen in cases of choked disc. They were found to consist of a few red cells, of macrocytes which the author interprets as "epithelioid" cells, and of phagocytes containing fatty debris. These last are considered to be connective tissue corpuscles.

A very fine series of photographs adds to the value of this important paper.

J. V. Paterson.

Paton. **Brain.** Vol. 32.

In relation to the preceding abstract it is of interest to note that with regard to the vexed question of the relationship of the amount of the neuritis to the side of the tumour Mr. Leslie Paton who has special experience at Queen Square Hospital continues to hold a different view from that expressed by Sir Victor Horsley, where, after a careful analysis of observed cases, he concludes that a difference between the amount of neuritis in the two eyes cannot be considered as of localizing value. From Paton's statistics we might specially quote the series of thirty cases in which optic neuritis appeared while the patient was under observation. "In thirteen of these it appeared simultaneously in the two eyes. In eleven it developed first in the opposite eye and in six only did it develop first in the eye on the same side as the tumour." The importance of this series of observations in shewing, at any rate, that there is no uniform tendency of optic neuritis to appear earlier on the side of the tumour cannot be gainsaid.

In a letter to the "British Medical Journal" of March 12th, 1910, Mr. Paton adheres to his position as expressed in his article in "Brain." He again points out that in dealing with the amount of neuritis we ought only to cite cases in which no sign of subsidence or atrophy has appeared.

Most of the 18 cases quoted by Sir Victor Horsley had come under Paton's observation at Queen Square, and he points out that in 6 cases Sir Victor Horsley has given the measurement

of the highest point on the surface of the disc without stating that a refractive error existed. In one case 4 D. of hypermetropia had been noted.

In this connection the reviewer would like to give it as his opinion that in very many cases of optic neuritis ·5 D. is a ridiculous amount of exactitude to claim for the measurement of the relative amount of swelling of the disc in the two eyes. So many disturbing factors exist. When one takes into account refractive errors, especially astigmatism, the natural difference in the refraction of the eye at the disc and at parts more peripherally situated, the impossibility of determining to a fraction of a dioptre when the focus of the summit of the swelling is reached, the frequent unsteadiness of the patient, and last of all the personal factor in observation, then it becomes plain that little stress should be laid on observed differences in the amount of swelling unless the difference is definite and distinct, amounting at least to 1 D. Paton also points out, apparently with good reason, that the brevity of the summaries regarding the appearances and relative swelling of the discs as given in Sir Victor Horsley's table does not always give a fair representation of the conditions actually observed. In support of this contention he gives fuller notes of the appearances in some of the cases. The reviewer agrees entirely with Mr. Paton in this criticism of Sir Victor Horsley's tabulated results.

The whole question is one which is bound to be soon definitely settled by more extended observation. At the present time the balance of evidence appears to favour the view that the relative severity of the optic neuritis in the two eyes provides at most a very uncertain guide in the determination of the side of the brain affected by the tumour.

J. V. Paterson.

Lt. Col. F. P. Maynard, I.M.S. **Preliminary Note on Increased Intra-ocular Tension met with in cases of Epidemic Dropsy.** *The Indian Medical Gazette*, Vol. 44. No. 10.

In this short article Maynard draws attention to a condition of increased intraocular tension, occurring as a complication of, or at all events, in association with epidemic dropsy. At the time of writing he had met with more than twenty cases. The ocular signs he has found are a slightly steamy cornea; a small

or moderately dilated pupil, acting sluggishly to light; an absence of vascular injection; a decided increase of tension Subjectively the patient notices dimness of sight and coloured rings, and occasional pain. In $\frac{2}{3}$ of the cases pathological cupping of the disc was present. The retinal veins were usually engorged and they and the arteries showed pressure-pulsation. In some, recovery had ensued: in others complete blindness.

Two-thirds of the patients were men, one-third women. The ages of all but two were under 36.

Maynard discusses the question of the exact nature of the conditions he has described, and its relation to epidemic dropsy. At the time he wrote his preliminary note he was not prepared to supply a definite reply to such queries. It is to be hoped that he will publish the results of his later investigations into this glaucomatous condition, and also that he will record the method of treatment he has adopted in such cases.

Alling (New Haven, Conn.). **Transplantation of Fat into Tenon's Capsule after Enucleation.** *The Ophthalmic Record*, March, 1910.

This is a procedure recommended in place of the well known device of introducing globes of glass, gold, or paraffin into Tenon's capsule after enucleation so as to prop forward the artificial eye afterwards used.

The fat is obtained from the abdominal wall or gluteal region.

It is claimed that the use of fat is preferable to metallic or other foreign bodies as it is less likely to be extruded in after years.

The technique is practically the same as in previous operations for introducing supports for artificial eyes.

In the same Journal there is also a notice of a similar operation by A. E. Hershoff, M.D., of Cleveland, Ohio.

C. B. Goulden.

Reber (Philadelphia). **Toxic Amblyopia of Diabetic Origin Occurring in a Young Woman. A Rare Symptom of Toxæmia of Diabetes.** *The Ophthalmic Record*, March, 1910.

In this paper, after drawing attention to the fact that the amblyopia of diabetes most usually occurs in patients who are also tobacco smokers, Dr. Reber reports an interesting case of

diabetic amblyopia in which tobacco could not be regarded as an assistant factor.

It occurred in a young woman aged 29 years, who had suffered from glycosuria for six months at least. The vision in either eye could not be improved beyond $^5/_9$, and upon examination with a red disc 2·5 mm. in diameter a colour scotoma could be detected extending 7° towards the normal blind spot.

Eighteen months later the vision was still the same and the colour scotoma was then charted with a 2 mm. red disc and extended irregularly from 2° to 5° from the fixation point.

The author refers to similar cases that have been reported by Nettleship, Samuel and Moore (2 cases). All occurred in women and tobacco as a causative factor could be excluded.

There is appended a good list of the literature dealing with the subject.

C. B. Goulden.

F. de Lapersonne and A. Cantonnet. **Visual Disturbances Produced by Tumours of the Pituitary Body without Acromegaly.** *Archives d'Ophtalmologie*, Feb. 1910, p. 65.

The authors consider the diagnosis of pituitary tumour comparatively easy when acromegaly is present, the deformities of the bones and alteration of the figure is so characteristic, but it is not so when acromegaly is absent. In such cases the character of the ocular symptoms is of prime importance, and with this, the taking of proper radiographs will make the diagnosis assured.

The symptoms of the disorder are divided into three groups:

(1) Glandular. Due to alterations in the body state by excess or loss of internal secretion. These signs are less discernable so far as the pituitary body itself is concerned, than they are in a coincident disturbance of other internal secretions: as of the thyroid, producing a temporary myxœdema; or of the sex glands, with consequent sexual inability. These signs constitute a 'glandular syndrome.'

(2) Physical symptoms. To be observed in radiographs, in the altered relations of the sella turcica, and in the presence of dark masses within its hollow.

(3) Mechanical effects. Such as intercranial hypertension, and the phenomena of localised compression. Recurrent headaches which are improved by extraction of cerebro-spinal fluid.

By effects on the lower cranial nerves, the oculo-motor, and the optic tracts. Of these, the last, as seen in the altered visual fields, is of by far the greatest importance.

The authors then cite a case of their own observation: A shepherd lad, aged 23, of good intelligence, small stature (1 m. 59), large head and full moon face, suffered from recurrent headache and giddiness from September, 1907; by March, 1908, vision had begun to fail, and in July the left eye had p.l. only. By February, 1909, the right vision had failed to $^1/_{50}$. Treatment with electric currents and a mercury syrup produced rapid improvement. At the present time: R.V. acuity normal; field, loss of temporal half except for a small zone with minimal perception of white (a comma-shaped patch on the 30° circle measuring 10° × 15°), the sound half of the field showed indentations of its periphery. L. no quantitative vision; field, temporal half retains its perception for white. There was right lateral homonymous hemianopsia, and inequality between the eyes. This inequality they consider distinctive of a basal tumour. The pupil reactions were present, fully in the right but feebly in the left eye. Wernicke's reaction could not be shown. The right optic disc was slightly pale, and the left white; the outlines were distinct without blurring, showing a descending atrophy and no neuritis.

The radiograph, of which a reproduction is given, showed a considerable enlargement of the sella turcica, which was filled by a dark mass larger than a walnut. The anterior limit was distinct, the posterior undefined owing to rarefaction of the bone or because of the spread of the tumour. The frontal sinus was enlarged and the thickness of the cranial wall irregular as in acromegaly. Lumbar puncture showed no hypertension, the fluid was normal and without cells. There were some signs of myxœdema, a general adiposity, and sexual inability

The authors pass in review a very large literature, of the greater part of which they present short summaries. They divide the cases published into groups: (1) Including 18 where the data of the visual fields are incomplete. (2) A group of 61 in which full details are given. They reject 13 as unsuitable for comparison, but they are inclined to include within this group cases of bi-temporal hemianopsia occurring in 'myxœdema,' for they deem such diagnoses uncertain in the absence of radiography of the skull, and consider the myxœdema may have been a secondary feature.

Out of a total of 80 cases the sex was given in 71; of these

41 were males, and 30 females. The average age of the affected males was 38, of the females 31. Of the visual fields: 21 per cent. had bi-temporal hemianopsia; 11½ per cent. hemianopsia in one eye only, but they consider the total loss of the other eye to have been a later stage of probable bilateral defect. Bi-nasal hemianopsia was never found; superior, inferior and left homonymous were all equally absent. Right hemianopsia was recorded thrice, including their own case, and in these the radiographs show a definite extension of the tumour backwards so that the optic tracts would be affected.

Optic atrophy was noted in 46 per cent., but this symptom must depend upon the time of the observations. So also with papillary stasis, it was rare, being noted in 16·2 per cent., a figure which agrees with the infrequency of hypertension on lumbar puncture. They consider that this is to be accounted for by the comparative youth of the patients, for Douglas has shown the liability to papillitis increases with age, and because the slow growth of the tumour expands the bone and enters into possession of the region of the body of the sphenoid. They compare the figures of papillitis, thus:— Pituitary tumour 16·2 per cent.; Cerebellar tumour 90 to 95 per cent.; Cerebral cortex 50 per cent. Papillitis is rarer the nearer the growth is to the eyes. Temporary visual obscurity is a common symptom despite the rarity of papillitis. Exophthalmia was noted 7 times, they consider it due to invasion of the orbit, or to pressure on the cavernous sinuses. Ocular paralyses were found in 29 per cent.

Treatment they confess to be still experimental. Pituitary extract appears to have little effect, but the treatment of intercurrent myxœdema by thyroid extract is useful, they suggest that sex-gland extract should be used in addition. Radiotherapy has been spoken well of by Béclère and Gramegna, and since knowledge is only obtained by the multiplicity of experiments, they suggest it should be given a reasonable trial. Surgical interference they believe rarely warranted; the approach to the seat of the growth is immensely difficult, and it is well nigh impossible to keep an entry from the pharynx aseptic.

They conclude by the suggestion that these affections are not so exceptional as is commonly supposed.

N. Bishop Harman.

R. Deutschmann. **On Detachment of the Retina and its Treatment.** *v. Graefe's Archiv für. Ophthalmologie*, Vol. 74, 1910.

Deutschmann's contribution to the Festschrift got up by his former pupils in honour of Professor Leber takes the form of a summary of his experience in the treatment of detached retina, a subjct to which he has given a great deal of attention.

The cases on which this paper is based are 260 in number, and the total number of eyes treated is 345. In this series are included only the cases that have been submitted to operative treatment up to July of last year.

Of the 345 affected eyes 12·7 per cent. were emmetropic, 2·8 per cent. hypermetropic, and 66·7 per cent. myopic. The amount of the myopia did not seem of any special importance, the exact figures being:—

Myopia of 1—6 D. : 15 per cent.
Myopia of 7—12 D. : 14·4 per cent.
Myopia of 13 D. and over 16·5 per cent.

In 32·6 per cent. of the patients the detachment was double. This admittedly high percentage the author attributes to the fact that the most severe cases have come under his treatment.

In 6·4 per cent. of the myopic detachments the lens had been removed.

In 44·3 per cent. of the eyes the lens became opaque.

Of the 44 emmetropic eyes affected only 7 gave a history of injury.

The author observed tears and perforations in the detached retina in 16·2 per cent., but notes that this is probably too low a proportion, as the tears heal spontaneously, may be hidden by folds or may be too peripheral for ophthalmoscopic examination. While almost all the perforations were above, with only two exceptions the tears were below.

Deutschmann has never observed a case that controverts the statement that all detachments begin above.

In only 13·3 per cent. of the cases was there any noticeable diminution of the intraocular pressure.

275 eyes in all were submitted to operative interference, with the result that 26 per cent. were cured, 35·2 per cent. improved and 38·7 per cent. unrelieved. If those eyes which were operated on at the earnest request of the patient and in which there was little or no prospect of improvement are excluded

from these calculations the percentage of complete cures reach the astounding figure of 31·1 per cent.

The author expresses the opinion that the customary treatment of detachment of the retina is valueless and that the cases that recover in this way would have healed spontaneously in the absence of any treatment.

Deutschmann prefers to allow his patients with fresh detachments to remain unrestricted except as to violent movement until the subretinal exudate has had time to settle and any tears to heal before making use of what he terms the only proper therapy for this affection.

As regards the pathology of the affection he maintains the view that a chronic form of equatorial choroiditis forms the starting point of an alteration and shrinking of the vitreous. As evidence of this fact he details the examination of an eye with spontaneous detachment and extreme lowering of intra-ocular pressure previously recorded (Deutschmann's Beiträge zur Augenheilkunde, vol. i, 1893).

Although Deutschmann claims such a great result from his operation other surgeons who have tried his methods are unable to confirm his results. It is however only fair to state that no very extensive use of his methods appears to have been made. The author insists on the necessity of repeated operations at comparatively short intervals and does not claim that a single "Durchschneidung" is expected to result in any very great improvement.

Full accounts of his methods are to be found in his Beiträge, vol. vi, 1907, and in an account specially written by him for the Ophthalmoscope, 1908, and these should be referred to by any surgeon who feels inclined to make trial of this operation.

E. E. H.

MELLER. **Embolism of a Cilio-retinal Artery.** (From the Clinic of Prof. Fuchs in Vienna). *v. Graefe's Archiv für Ophthalmologie*, 72, 3.

THE author's case was that of a married woman of thirty-five years of age, who suddenly became aware of a blinding sensation in the left eye, and on shutting the right eye saw a cloud moving in front of the left; there was also a stabbing pain in the præcordial region. For the last two years she had been under treatment for some uterine trouble dating from the birth

of her last child: catamenia had begun two days before, had been in abeyance for a day, and had recurred profusely on the day the blinding sensation was noticed.

The patient's general condition was good, though examination revealed a pleuritic rub on the left side of the chest.

On admission the right eye was found to be healthy in every respect, and vision was $^{6}/_{6}$, the vision in the left eye was reduced to counting fingers at a metre, and the fundus examination revealed a state of affairs, which is well shown in the accompanying lithograph. The outer half of the disc was pale, and its boundaries were not quite so clearly defined as on the right side, there was a small cilio-retinal artery starting from the inner edge of a small temporal crescent, and running outwards towards the macula; the retina to the outer side of the disc was œdematous, and of an opaque grey colour, and there was a typical cherry-red spot at the macula: the central vessels were normal in appearance, but their macular branches were practically non-existent, their place being taken by the cilio-retinal vessel described.

On pressing on the globe with the finger the central retinal artery pulsated, whereas the cilio-retinal collapsed. There was an absolute central scotoma of 10° breadth.

Next day fine pulsations could be detected in the cilio-retinal vessel, and a week later vision had risen to fingers at two metres, the scotoma had shrunken on the nasal side almost to the fixation point, but still had a breadth of 5° on the temporal side.

At the end of a month vision was $^{6}/_{36}$, the scotoma extended for 5° just outside the fixation point, the outer half of the disc was pale, and the œdema had disappeared.

Meller finds only three similar cases in the literature, those reported by Hirsch, Zentmayer and F. Krauss; he thinks that vessels of small size may be obstructed without the patient being aware of anything being wrong, as long as the scotoma is not central, especially if the other eye is sound; in other words that if the macula in his patient had been supplied with larger twigs from the central vessels, the obstruction of the small cilio-retinal one would possibly not have been noticed.

R. R. James.

E. H. Pagenstecher. **On Mydriasis and Congenital Defects of the Eye in Keratoconus.** *v. Graefe's Archiv für Ophthalmologie*, Vol. 74. Leber's Festschrift.

The author bases his paper on the examination of eleven cases of keratoconus. In six of these cases the anisocoria was very conspicuous. De Lapersonne has suggested that this difference in the size of the pupils might be connected with some paralysis of the sympathetic, but Pagenstecher found in his cases no evidence of any such affection. Neither did he find any evidence of other nervous disease. In five of the six cases the wider pupil was on the side of the most affected eye. As the author was able to exclude any nervous cause for the apparent difference, he came to the conclusion that the phenomenon was probably an optical one. He was able to observe the eyes in two of his cases, when immersed in normal salt solution, and then found that the difference in size of the pupils disappeared. He then made measurements of the corneal radius and depth of the anterior chamber, and so was enabled to calculate the difference in magnification under which the two pupils were examined. In two cases the calculated magnification corresponded with that observed clinically. In a third case the difference between the two pupils was greater than could be accounted for by the magnification. As in this case the difference between the two pupils did not entirely disappear under salt solution, there was probably some real anisocoria present.

In all nine of his cases in which special search was made for any signs of other congenital defects, some anomalous condition was found Nine times this took the form of punctate opacities in the lens and four times that of remains of capsulo-pupillary membrane. This observation is opposed to Parisotti's statement.[1] Pagenstecher favours the theory that keratoconus is due to a congenital disposition, probably a hypoplasia of the central part of the cornea. Keratoconus like hydrophthalmos may occur as a family complaint, and although it is not probable that there is any connection between the two, they both apparently are connected with congenital defects of development.

E. E. H.

Weinstein (St. Petersburg). **A Case of Buphthalmos with Congenital Hypertrophy of the Upper Lid.** *Klinische Monatsblätter für Augenheilkunde.*

After referring to the classical description of von Recklinghausen, and to the more recent views of M. Borst and Ziegler

1. Parisotti, *Annal. d'Oculist.*, May, 1909, p. 360.

on neurofibromata, the author divides those affecting the lids into the three following groups: (1) Neuroma plexiforme (Bruns, Billroth, "Rankenneurom"). (2) Fibroma molluscum. (3) Unilateral hypertrophy of the face (J. v. Michel), and remarks that each form may be combined with buphthalmos.

He then briefly summarises the ten previously reported cases, and proceeds to describe his own case, which was shown by Dr. Karnitzky before the St. Petersburg Ophthalmological Society in December, 1907.

Weinstein's case was that of a peasant of sixteen years of age, who was otherwise healthy. The history procured from the parents was that the boy was born with a thickened lid, and that the tumour gradually increased in size, and extended on to the left temple: the eye had some vision in it at first, but subsequently became blind and painful.

The condition of the patient is shown in an illustration; the upper lid is enormously thickened and covers the globe completely, the eyebrow on that side is deficient in its outer half, and the tumour extends on to the left temple.

The conjunctiva of the upper lid is thickened and wrinkled, while the lower lid is normal.

The left eye is said to be typically buphthalmic, the tension is +, and the fundus cannot be seen. The right eye is healthy. The patient was admitted for excision of a piece of the tumour, which proved to be a typical neuro-fibroma, as is well shown in an accompanying illustration.

The rest of Weinstein's paper deals with the pathology of buphthalmos, and he apparently agrees with v. Michel in thinking that the occurrence of buphthalmos with one or other form of neurofibromatosis of the lid is not accidental.

R. R. James.

Zahn (Tübingen). **Ionisation—Experimental and Clinical Results.** *Klinische Monatsblätter für Augenheilkunde*, Jan., 1910.

This paper is a record of practical experiment carried out by Dr. Erwin Zahn on the eyes of living rabbits with a view further to investigate the subject of ionisation and the theories of its action which Wirtz and others have advanced. Towards the end of his article Zahn refers also to a number of cases of eye disease in man in the treatment of which this method was adopted. Wirtz attributes the healing action of ionisation in

eye diseases such, for example, as serpiginous corneal ulcer to a direct destruction of the active cause, while zur Nedden holds that through the influence of the ions driven into the tissue the natural healing factors of the blood are conveyed to the infected area in a higher degree and that recovery is thus only indirectly brought about. Whether at bottom there is really so very much difference in the two theories we need not stop to consider but we may as well say here that Zahn's results convince him that in such local infective processes ionisation acts directly as well as indirectly in its attack on the origin of the disease. His bacteriological experiments on the point are not yet completed.

Almost all the experiments were undertaken without the use of cocain: in a few instances however cocain was used in one eye and not in the other for the purpose of comparing results, but without eliciting any noteworthy difference. The author emphasises the importance of using absolutely clean distilled water as the least impurity may seriously prejudice the effects produced. In his experiments on animals Wirtz used almost exclusively a large electrode but Zahn preferred smaller ones, generally using No. IV.: the changes which follow the use of the small electrodes are more marked than when larger ones are employed. The current strength varied between 1 and 5 milliampères and the time of application between $\frac{3}{4}$ of a minute and 5 minutes.

It is unnecessary to describe in detail the series of experiments or the graduated effect produced, varying according to the severity of the application, but we may with advantage give the results obtained in two typical instances and for the rest briefly summarise the writer's conclusions.

Experiment I (Zinc). R. eye, application 1 minute; L. eye, application $\frac{3}{4}$ minute; 1 milliampère. The changes, both immediate and later, were practically the same in the two eyes despite the difference of the time during which the current was applied. Immediately after the application the corneal epithelium showed a greyish-white, dry, sharply-cut erosion the size of which corresponded exactly to that of the electrode employed. Owing to the density of the epithelial opacity any estimate of the condition of the deeper corneal layers could not be made. The surrounding cornea was clear; the iris slightly hyperæmic. After 24 hours the epithelium had so cleared that a greyish-white opacity of the corneal parenchyma, most pronounced at the centre, could be clearly distinguished; the iris injection had

disappeared. The opacity gradually got less until at the end of a fortnight both corneæ were perfectly transparent.

Experiment IV. (Zinc). R. eye, 2 minutes, 5 milliampères; L. eye, 5 minutes, 2 milliampères. The immediate changes were a little more marked in the right than the left eye. The eroded epithelial area was white rather than grey; the surrounding ring of deeper opacity more marked than where, in the intermediate experiments, weaker applications were used, and the iris injection much more intense. Twenty-four hours later a central opacity in the deeper layers was seen to be sharply marked off from the surrounding less affected tissue, and the whole corneal surface up to the limbus was slightly clouded. The corneal tissue in the immediate neighbourhood of the thickest nebula was somewhat swollen and was unduly sensitive. Iris deeply injected. Conjunctiva a little œdematous. After four days a definite keratoconus-like projection of the corneal surface occurred, the apex of the cone corresponding to that part of the cornea which was most opaque. The whole cornea was swollen and much clouded; intense iritic injection persisted and in the left eye exudation into the anterior chamber had taken place. During the following days the cornea slowly cleared and the cone-shaped projection gradually went back, rather more rapidly in the left than in the right eye. Three weeks later the corneal curvature had again become normal. Both corneæ showed opacities, dense, small, and central in the left, while, in the right eye, the clouding was thinner but more extensive. Epithelium rather irregular. At the end of two months the same condition of corneal opacity held good except that it was just a little less pronounced.

The above two experiments are more or less typical examples of all those performed—the results varying in degree with the strength of current and the time during which it was applied. In one case where a current of 5 milliampères was used for 5 minutes the ultimate issue was perforation of the cornea with extrusion of the lens.

With these two instances before us we may in a few words summarise the changes observed in the whole series of the author's experiments.

The first effect is a sharply defined necrosis of the corneal epithelium with a somewhat dried up condition of the cornea over an area corresponding to the size of the electrode employed; the degree of epithelial change is dependent on the strength of the current which has been used: with a weak current the

resulting opacity is grey or greyish-white, with a stronger current more white than grey. Shedding of the injured epithelium usually occurs within 24 hours and its complete regeneration in the course of a few days. When the over-dry condition of the cornea has passed off a corneal swelling sets in, the amount of which is also in direct proportion to the current strength, and at the same time there occurs a general cloudiness in the peripheral parts of the cornea which have hitherto been clear. With weak applications the deeper parenchymatous opacity is—like the epithelial—of the size of the electrode which has been used but with stronger and more prolonged treatment (2 m.a. 2 min. and over) it is more extensive and is surrounded by an area of less pronounced scar-like opacity. Transparency is not regained for some weeks. With applications of 2 m.a. 2 min. and under it is eventually complete, but with stronger applications permanent scars usually remain; alteration of the corneal curvature resulting in kerato-conus or even kerato-globus is brought about by strong applications, and such cases always show so marked a swelling of the corneal tissue that a probe or blunt instrument laid on its surface leaves a deep mark or groove which persists for some time. Sensibility over the swollen area is greatly increased. Except in extreme cases where perforation may occur the normal curvature is, with the subsidence of the swelling, gradually restored, but permanent corneal scarring, more or less intense, remains. In subsequent experiments made by the author with comparatively weak applications (2 m.a. 2 min.) he was able to produce less degrees of kerato-conus, and in one instance, in a very young rabbit, a small but distinct corneal cone, which, however, completely disappeared in 24 hours, followed an application of only 1 m.a. 1 minute. The iris is always injected and in some cases a definite iritis with exudation developed. Inflammatory changes in the conjunctiva vary between slight hyperæmia and œdema with purulent discharge. The corneal opacity and contraction of pupil made any ophthalmoscopic examination impossible, but in the later stages when the deeper parts could be seen no abnormality was detected.

Results in the experiments made with reagents other than zinc were very much the same as those already described except that the inflammatory changes were less severe. When saline solution was employed the changes were least marked of all.

Pathological Examination. For the sake of comparison Zahn arranged that in all cases two eyes should be submitted at the

same time to exactly the same conditions. One of these eyes was examined immediately after the experiment, the other 24 hours later. The results were shortly as follows. In the fresh specimens destruction of the superficial and flattening of the deeper epithelial layers had occurred and there was also marked thinning of the substantia propria over an area corresponding to the electrode's size. This corneal thinning in the majority of cases amounted to half the normal depth. Descemet's membrane was unchanged. While, with weak currents, the endothelium remained perfectly intact, it was thinned when stronger currents were used. The iris vessels were appreciably enlarged. In the specimens examined 24 hours after the experiments had been performed the epithelium was in all cases so much destroyed that the substantia propria was exposed. In place of the original thinning of the substantia propria there was thickening due to the swelling which had set in. The line of demarcation between the injured and the healthy tissue was absolutely sharp. The injury to the corneal tissue was as marked and extensive in the deeper layers as in the superficial —a noteworthy testimony, as Zahn remarks, to the effective working of the ions. Descemet's membrane was healthy, but the endothelial cells were injured over an area corresponding to that of the superficial changes. Only where severe applications had been made (5 m.a. 5 min.) were the iris vessels at this stage much enlarged, and in this case also serous exudation cells were found in abundance in the anterior chamber. The pathological results in the experiments made with solutions other than zinc showed, as in the case of the living animals, less intense and less extensive injury.

We may close our notice of this interesting paper with a very brief résumé of the 57 clinical cases in which ionisation treatment was made use of. They are as follows:—

1.	Serpigenous corneal ulcer (pneumococcus).	17 cases
2.	Corneal ulcer (diplobacillus)	10 ,,
3.	Corneal ulcer (bacillus not isolated) ...	6 ,,
4.	Keratitis dendritica	6 ,,
5.	Interstitial keratitis (hereditary specific)...	5 ,,
6.	Corneal maculæ	5 ,,
7.	Scleritis	4 ,,
8.	Blepharitis ulcerosa	4 ,,

1. Of the 17 cases treated 14 healed completely: in 3 cauterisation was also used.

2. Clinically the condition looked like serpiginous ulcer: in the majority of the cases there was acute iritis with hypopyon. In all 10 cases, healing, but with dense opacity remaining, occurred after ionisation had been employed from 1 to 4 times.

3. All the cases rapidly healed after only one application.

4. After one or two applications there was an arrest of the disease, which had, till then, been spreading. Healing followed with thin opacities.

5. Repeated treatment made no apparent impression.

6. No improvement.

7. Here also no improvement could be made out.

8. Rapid healing with very delicate nebulæ.

NORMAN M. MACLEHOSE.

SALUS (Prague). **Researches on the Biology of the Lens.** *v. Graefe's Archiv für Ophthalmologie*, 72, 3.

ACCORDING to Römer's theory senile cataract is caused by the action upon the lens cells of toxins existing in the blood stream, which are produced by the absorption of the products of tissue metamorphosis (autocytotoxins). Under normal conditions the ciliary body does not permit the passage of such substances into the aqueous humour. If, however, the ciliary body becomes permanently impaired in any way, especially through the degenerative processes associated with old age, its protective power may become lost and toxins may be admitted to the aqueous and may thus injure the lens.

On this hypothesis Römer then proposes to procure the fixation of such toxins by means of free lens-albumin in the blood and therefore recommends the internal administration of lens-substance in cases of senile cataract.

Salus considers both on theoretical and experimental grounds that Römer has failed to demonstrate the truth of his premises.

If toxins in the aqueous were the cause of senile cataract all such cataracts would be subcapsular, whereas there is no sharp line of division between the nuclear and the subcapsular varieties. Importance is attached to the point that Groenouw has shown that while senile cataract is frequently hereditary it is merely the opacity and not any particular variety of cataract which is inherited.

In order to establish Römer's theory the presence in the lens

of receptors capable of anchoring the toxins to the lens cells must be demonstrable. The author has undertaken numerous experiments for this purpose.

He finds that there is no evidence to show the presence of true agglutinins or receptors of the second order, and that the toxophile and complementophile properties of lens matter are due to alcohol-soluble substances which are therefore non-albumenoid and not genuine receptors of the first and third orders. As the complementophile properties of the lens are possessed by many other tissues it would be natural to expect senile cataract to be only one of many degenerative changes instead of, as is often the case, the only appreciable defect.

Having immunised against vibrios three cataractous but otherwise healthy patients the author found that while anti-bodies for vibrios were present in large amount in the blood, none could be detected in the aqueous humour. He concludes that Römer's view as to the action of the ciliary body in cases of senile cataract is unfounded.

There is no evidence in favour of the presence of cytotoxins in increased quantity in the blood of cataractous subjects, while they are more abundant in syphilitic individuals who are not specially prone to cataract. Toxins of other kinds are also unacceptable as the cause of senile cataract, on the ground that, as in diabetes for example, cataract would not be the only defect produced. He finally sums up in favour of regarding senile cataract as a physiological accompaniment of old age.

In the second part of the paper the treatment of senile cataract by lens substance is discussed.

Albumins administered in this way are digested and do not enter the blood in their original form and are therefore incapable of causing the formation of antibodies. This may however occur in the case of herbivorous animals such as the rabbit whose alimentary tract is not normally called upon to deal with food of this kind.

Lastly Salus suggests that Römer's results are to be ascribed to causes other than the ingestion of lens substance, especially as not only cessation of the cataractous process but also actual improvement was obtained. He does not commit himself as to the probable nature of these causes.

H. M. Traquair.

SALUS (Prague). **The Behaviour of the Ciliary Body to Anti-bodies.** *v. Graefe's Archiv für Ophthalmologie*, Vol. 75, pt. 1.

STARTING from the well-known difference in composition between the fluid withdrawn from the anterior chamber, "the first aqueous," and that which refills it, "the second aqueous," the latter being more albuminous and approaching more closely in nature to lymph, the author has set himself three problems for investigation. Firstly, the relation between the known antibodies and the ciliary body; secondly, the causes of difference, if any, in the behaviour of the various antibodies; and lastly, whether these relationships suggest any alteration in our views as to the production of the aqueous itself.

After discussing the work of other authors which bears upon this subject, Salus deals with antitoxins, agglutinins, precipitins, hæmolysins and bacteriolysins in order. Details of these experiments, which were conducted on rabbits, should be read in the original article.

It is interesting to note that the anterior chamber lends itself advantageously to the demonstration of biochemical reactions, with which we are more familiar in vitro. If a rabbit be given an intravenous injection of 10 cc. of human serum and its anterior chamber be immediately tapped, within five minutes it refills with a clear red fluid showing very beautifully the hæmolytic action of the serum on the rabbit's red corpuscles. Again, if both anterior chambers of a rabbit, previously treated with human serum, be tapped and a drop of horse serum be injected into one and human serum into the other, the reaccumulating aqueous will cause a visible precipitate only in the eye in which the human serum was injected, thus demonstrating the passage of specific antibodies through the ciliary body.

Generally speaking, the author found no basis for the hypothesis of "cytotoxin retention" by the ciliary body and considers Römer's views and conclusions on this subject to be unfounded.

The gist of this interesting and important paper may conveniently be conveyed by a slightly abridged translation of the author's conclusions.

1. Agglutinins and antitoxins (in passive immunisation) pass most freely into the aqueous, bacteriolysins somewhat less and hæmolysins least of all. Complement is not demonstrable in the first aqueous.

2. After puncture the antibody-content of the aqueous is

much increased but remains below that of the blood serum at the same time.

3. Albuminoid precipitins are peculiar in that they entirely fail to pass through the normal ciliary body.

4. They are however present in the second aqueous, in common with all the other antibodies.

5. Precipitins are removed from the second aqueous very rapidly, perhaps more rapidly than the other antibodies.

6. As this retention of precipitins by the ciliary body does not appear to depend upon any peculiarity in their molecular constitution, it may be regarded as the expression of a definite secretory power of the endothelial (and epithelial ?) cells of the ciliary body.

9. In animals immunised against albumin a qualitative passage of the antigen injected intravenously occurs in the same way as in the unimmunised, which justifies the conclusion that the antigen is not fixed in demonstrable amount by the antibodies of the serum.

A bibliography of the subject is appended.

H. M. Traquair.

Buri (Basel). **Is Chalazion Acne?** *Deutschmann's Beiträge zur Augenheilkunde*, pt. 74., Dec., 1909.

Many have been the theories of the pathology of chalazion, and the dermatologist, Dr. Buri, reviews these in chronological order. Some authorities have considered it due to disease of the hair follicles and others that it was a retention cyst. Later it became to be regarded as a granuloma arising from the meibomian gland and was relegated to the category of scrofulous inflammations.

Deutschmann in 1891 settled the question with regard to chalazion being tubercular. He could find no evidence whatever of this. He agreed with de Vincentiis and Fuchs that it was a chronic inflammation of the meibomian gland with proliferation of the gland epithelium and a consecutive chronic infiltration of the surrounding connective tissue, a chronic adenitis and periadenitis of the meibomian gland. More recently the matter has been gone into by French investigators.

Lagrange (1904) pointed out that the chief mass of the chalazion developed in the connective tissue of the lids, far from the glands, and consisted of embryonic connective tissue surrounded by a thick fibrous capsule which was absent in a

young chalazion. This granulation mass in the connective tissue he called a chalazion externum, whereas the mass occupying the tarsus and glands he termed a chalazion internum. The former arose from the latter destroying the tarsus and invading the connective tissue.

Terson (1906) defined chalazion as granulation tissue with no specific characters, giant cells being present in variable numbers. He believes that it is certainly not a tubercular condition, but that some organism gives rise to it, the soil having been prepared by some general or local disease. He considers that chalazion has more resemblance to lichen scrofulosum than to acne.

Sabrazes and Lafond studied the cells in chalazion and found that they consisted of plasma cells, giant cells, lymphocytes, large phagocytes, and leucocytes,—all the cells found in granulation tissue. They believe that chalazion resembles, both clinically and histologically, acne, and that it arises in the meibomian gland.

Dr. Buri's work was undertaken to decide this question. For this purpose he obtained portions of chalazia only two of which were extensive and enabled the relation between chalazion and the meibomian gland to be studied properly. Into the minute histology of these specimens Dr. Buri goes very thoroughly.

In Case I the swelling occupied the loose connective tissue above the tarsus. It was œdematous and consisted of cells, plasma, spindle, and giant varieties. The latter were scanty. There was no real capsule. Only portions of the meibomian glands remained in the specimen. The acini in the upper part of the tarsus appeared diseased and were smaller, owing to atrophy of the fat cells. There was a proliferation of the gland cells and some, not undergoing separation, gave rise to giant cells. No obstruction to the duct could be seen and no hyperkeratosis of the epithelial lining, such as is met with in a comedo, was present. The periacinous zone showed infiltration by plasma cells. In some places these were sharply demarcated from the gland, in others the gland cells were disintegrating and mixed with the periacinous infiltrate. Similar changes to those in the meibomian glands were found in the accessory tear glands. Here changes were more pronounced so that the mass was ill-defined as far as its cellular constituents were concerned but contained a few giant cells. Indeed these glands were changed almost beyond recognition. Further these presented a more

intimate relationship to the chalazion mass than the meibomian glands. A healthy zone separated the latter from the former.

In Case II only small portions of the glands were present in this specimen, and they were perfectly normal. The peri-acinous tissue was richly infiltrated with plasma cells. The granulomatous mass was situated away from the glands and at the periphery consisted chiefly of plasma cells which were absent in the centre where it consisted of leucocytes, connective tissue cells, and nuclear remains. No giant cells could be found. The fluid centre was due to cellular disintegration. The other specimens which were fragmentary helped to throw further light on the subject and confirmed the findings in the above mentioned cases. Buri gives drawings of the various cells met with.

In concluding, Buri, although regretting the paucity of material at his disposal, nevertheless considers it sufficient to settle the question as to whether there is any relationship between chalazion and acne.

The chalazion is a granuloma, arising in the loose connective tissue behind the tarsus and above the fornix, which is prone to undergo œdematous softening in its interior. Its constituents are always the same and can be recognised in zones from without inwards as follows. At first hypertrophied spindle cells, then large plasma cells, further small plasma cells with a few multinuclear and giant cell-like plasma cells intermixed. Further towards the inside, if the chalazion is old, follow the signs of blood and lymph obstruction, enlarged capillaries, œdema, hæmorrhage, and dissolution of cells. The intercellular material is scanty from the very beginning. There are no gland elements or even remains in the granuloma nor has it developed around any glands as far as one can judge. This is the uniform character presented by a chalazion. Buri could find no relation between the swelling and the meibomian glands so far as his material went. Indeed in his second case what remained of the meibomian glands was quite normal. He concludes from this case alone that any etiological relationship between meibomian gland and chalazion is excluded.

If such did exist one would have to explain it by supposing that the dense tarsal tissue prevents a granuloma forming in the meibomian gland and a toxin diffusing into the connective tissue gives rise to the granuloma there. If not this, then the disease affects the mouth of the gland first and extends up to the fundus whence it spreads to the connective tissue. But this is not so. In his second case quite the upper two-thirds of the

meibomian gland were there and quite healthy too. In some of his specimens the meibomian gland was affected, but that only slightly, and it was separated by a healthy area from the granuloma. When the meibomian gland is affected it may be so secondarily. It is more likely that the accessory tear glands in the fornix are related to the chalazion. They were certainly more affected in Case I above, indeed altered beyond recognition. Buri is therefore in favour of the primary site and point of origin being in the region of the fornix and its glands.

From these findings he feels he can reply with safety to the question whether chalazion is an acne as Sabrazes and Lafond believe.

From his investigations, Buri says he must maintain the contrary, namely, that the two are entirely different affections of the skin. He begs to emphasise the point that in every case of true acne one meets with the comedo in which there is circumscribed hyperkeratosis of the duct. Without comedo there can be no acne. This is absent in chalazion. He knows of no evidence of a chalazion having an excretory opening at the lid margin. In acne the stratified, lamellar, carnefied body in the duct is produced by hyperkeratosis and this is never wanting. In chalazion it has never been shown to be present. There is no evidence of an abscess of the meibomian gland or a cyst wall due to retention and stretching. Further the cells of the granuloma arising around an acne pustule are quite different to those in the chalazion. And again if the bacteriology is investigated the two conditions are not in agreement in this respect. He concludes therefore that chalazion is a granuloma *sui generis* and differs in many important points from acne so that one can recognise the two as different affections.

All this is supported clinically. Acne is seldom met with in combination with chalazion in spite of the former being so common. Chalazion is more common in cases of seborrhœic eczema and like rosacea thrives well on seborrhœic soil. If chalazion was an acne it would be commonly met with in multiple rather than single form. BEATSON HIRD.

Ch. LAFON and M. BONNET. **Voluntary Nystagmus.** *Receuil d'Ophtalmologie*, October, 1909.

AFTER referring to the literature on this phenomenon, the authors proceed to describe the method by which voluntary nystagmus can be provoked, as evidenced by one of their com-

panions. In order to obtain the greatest degree of oscillation, an object is placed at 10 centimetres distance from the eyes in the median line a little below the horizontal; the object is then strongly fixed while the lids are opened as far as possible. A forced contraction of the external ocular muscles is then made including the occipito-frontalis, when a slight effort of convergence immediately sets the eyes in motion. The oscillations are 3 mm. in amplitude, and have a rhythm of 4 to 5 per second; if the fixed object is removed the oscillations diminish to 1 mm. amplitude, with not more than 2 per second in rhythm; the nystagmus is always horizontal, indentical in the two eyes, and the displacements are equal and synchronous; the movements are no longer possible when one eye is covered.

Following the nystagmus no abnormal sensation is experienced beyond a feeling of dull aching at the back of the eyes, and a slight diminution in visual acuity.

MALCOLM L. HEPBURN.

GREEFF, F. **Atlas of External Diseases of the Eye.** Translated by P. W. Stedd, M.D. 42s. net.

IN his preface Professor Greeff explains that his object was to produce pictures of distinctly better technique than those hitherto published. The plates were obtained by making, after a special method, a mask of the living subject, which was then filled with wax. From the wax models photographic reproductions in four colours were made. The result is a very beautiful series of plates illustrative of morbid conditions of the parts near the eye and of the eyelids. One could hardly imagine anything more wonderfully life-like and natural than many of these plates. When we come to the illustrations of the more purely ocular affections we confess to a feeling of disappointment. No doubt we expected the impossible for the reproductions have evidently been made with singular care and skill from specially selected cases. In some of the plates illustrative of diseased conditions of the conjunctiva and cornea the colouring appears crude and sometimes there is marked over-accentuation of certain features, the whole effect being to give a hard diagrammatic appearance to the picture. Descriptions of the diseases which the plates illustrate are provided in the text. Particular mention might be made of the carefully elaborated descriptions of blepharitis in its various forms.

We would recommend this atlas as likely to be of value to teachers of ophthalmology in the various medical schools.

Berlin Ophthalmological Society, 26th May, 1910.

Reported by Dr. Curt Adam.

Fehr showed a patient on whom *Krönlein's operation* had been performed for lymphangioma of the orbit. The whole functions were preserved with this exception, that there was a partial paralysis of the external rectus. He also showed a case of choked disc cured by trephining.

Halben showed a *Morgagnian cataract* in which a dark nucleus could be seen moving when the head was moved, in a pulpy, chalky, cortex.

Thorner: *The limits of Visual Acuteness.* Thorner maintained that in questions relating to the limits of visual acuteness sufficient attention has not been devoted to the diffraction phenomena caused by the pupil. As the result of experiments he was of opinion that conclusions regarding the resolving power of the eye should be based on the perception of fine bright lines. He also found that in testing for high degrees of visual acuteness the size of the pupil must not be neglected; for example for a visual acuteness of three times the normal the size of the pupil must not be less than 5 mm.

Levinsohn: *The influence of the Exterior Muscles of the Eye upon intraocular Tension.* One of the numerous theories of advancing myopia is that during prolonged close work the contraction of the exterior muscles of the globe raises the intraocular tension, causes elongation of the globe, and so leads to increase of the myopia. Levinsohn has made a number of manometric experiments on cats, and has come to the conclusion that increase of tension can occur as the result of pressure from without by the muscles only if other factors enter in, *e.g.*, contraction of the unstriped muscle of the orbit, and if the vasomotor and vasodilator mechanism be actively involved also. The author has also satisfied himself by actual observation with a Schiötz tonometer that there is no rise in the intraocular pressure even on the strongest convergence or other ocular contraction of muscles. He is all the more thoroughly convinced of this since the anatomical conditions found in highly myopic eyes rather contradict the theory of increased tension at any rate.

Paderstein: *A Foreign body in the Lens without the formation of Cataract.* He had observed two cases in which it was only after a lapse of 4 weeks in the one case and of 8 in the other,

that cataract began to form although a chip of metal had pierced the eye. In a third case a chip of considerable size had remained for seven years in the iris and lens without giving rise to any trouble in the lens at all. Even when the foreign body had been extracted with forceps cataract was not totally complete even after a lapse of six months. In the second of the cases Paderstein recommenced prompt removal of the foreign body lest glaucoma should ensue. Should the attempted removal by the wound of entrance not succeed, a peripheral discission and subsequent extraction would probably be the most suitable method of treatment. Were such an occurrence to take place in one eye whose fellow was amblyopic or aphakic, the better course would be to leave it.

In discussion Fehr said that he had seen the lens in such a case remain transparent even after extraction of the foreign body. Others though it probable that even after six months had elapsed the lens would after all become opaque.

W. G. S.

OPHTHALMOLOGICAL SOCIETY OF THE UNITED KINGDOM.

Thursday, June 9th, 1910, at 8 p.m.

The President, Dr. G. A. Berry, *in the chair.*

Extensive Subconjunctival Rupture of a Buphthalmic Eye: Recovery.—Mr. C. Blair.

J.G., aged 5, came with a history of having fallen against the iron wheel of a perambulator, and struck the right eye. On examination there appeared a large vertically-placed rupture on the inner side of the eyeball extending half-way round the globe, and situated just behind the ciliary region. A pressure bandage was applied, and the wound soon healed; but this eye was afterwards distinctly more prominent than the other.

The buphthalmos in this case was associated with other congenital defects, and the child was actually undergoing treatment for a club-hand.

Guttate Iritis.—Mr. R. W. Doyne.

This condition was described in a case shown before the Society last December, and it was observed to be more common in gouty people. Mr. Doyne regarded the condition as one not usually recognized, and

certainly very rare. It was shown that adhesions do not necessarily occur at the situation corresponding to the guttæ, which disappear or alter in position and appearance in the course of a few weeks. In this patient the lens capsule was seen to be freely dotted with iritic pigment.

Test Lenses for the Dark Room.—Mr. R. W. Doyne.

These lenses were set in frames which were made with various marks on the rims and handles of different shapes, so that by merely feeling the rims or handles one was enabled to ascertain the strength of glass which was being used, thus obviating any necessity for examining the lenses by sight.

Vertical Nystagmus, with movement so fine as to escape notice with the naked eye.—Mr. A. H. Thompson.

This was the case of a boy, aged 11, who had some refractive error, and the vision, when corrected, was $^{6}/_{12}$ in each eye, and the fundus was normal. The nystagmoid movements were so fine that they could only be detected with the ophthalmoscope.

Microscopical Sections of an Eye with unusual Yellow Patches in the Iris, shown at the last Meeting.—Messrs. E. Treacher Collins and A. C. Hudson.

A.M., aged 19, lost the sight of the left eye from ophthalmia neonatorum, the right eye being also affected at the same time.

On examining the left eye, there was a large, oval, densely white opacity of the cornea at the lower and outer part, with some straggling new vessels passing into it, and to which the iris was adherent. In the substance of the iris were several yellow-coloured patches with sharply defined margins and of an irregular shape, situated about midway between the ciliary and pupillary margins, but the anterior surface of the iris was not raised over them. On investigation some blood-vessels were seen to course through them, which did not appear to be of new formation, but merely the normal iritic vessels showing up more clearly than usual on the light-coloured background; they were lost to view where they passed into the unaffected stroma. The vision in the eye was no P.L., and the tension normal. That in the right was $^{6}/_{18}$, and, although there was nothing abnormal about the iris, the cornea showed some nebulæ, and there was lateral nystagmus.

Lymphatic Growth of Conjunctiva cured by Radium.—Mr. W. Lang.

A drawing of this case, which was shown at a previous meeting of the Society, showed that, whereas both eyes formerly exhibited a similar appearance, or, indeed, the left was somewhat worse than the right; as a result of radium treatment, the condition of the left showed considerable improvement.

A Case of Raynaud's Disease with Retinal Hæmorrhage, and other Changes in the Retinal Vessels.—Dr. Rayner Batten.

A female patient came for treatment for failure of sight in the left eye of three or four weeks' standing. In April, 1910, she had sudden failure of vision, from which she partially recovered, followed by another attack in a month's time, accompanied by sudden pain in the eye. With the ophthalmoscope there were seen several hæmorrhages in the fundus, and the upper temporal artery appeared to terminate suddenly where crossed by the corresponding vein, and became lost in an area of retinal disturbance.

Raynaud's disease had existed for eleven years, and two toes were gangrenous.

New Growth involving the Lacrimal Gland.—Mr. Blair.

A patient, aged 42, had first noticed the right eye prominent three months ago. The vision in the right was counting fingers, and the left $^{6}/_{6}$. There was no pain, the movements of the globe were limited, and in the region of the lacrymal gland was felt a hard fixed swelling, neither tender nor nodular.

Complete Congenital Dislocation downwards of the Lens.—Mr. Blair.

Secondary Contracting Scirrhus of the Orbit.—Mr. Arnold Lawson.

In this case, three years ago, the right mamma was removed for scirrhus of the retracting type, and the breast had been noticed to be undergoing cicatricial contraction for six years. About ten months ago it was noticed that the right eye was becoming fixed, and the upper lid began to droop, but there was never any pain. The vision was $^{4}/_{60}$, and the fundus was very indistinctly seen. At the present time there was great retraction of the upper lid and eye, the lid drooped completely, and there was total loss of voluntary movement, except slight lateral movements; the lower lid was also fixed, but not retracted. There was a hard elastic resistance felt on pressure through the lower lid, evidently due to a swelling in the orbital cavity, and it suggested some deep cicatricial contraction in the orbit pulling both the lids and the eye backwards. The patient's general health was quite satisfactory, and there was no loss of flesh.

Papers.

Advanced Optic Atrophy following the use of Soamin and Orsudan for the treatment of Syphilis in Two Patients.—Mr. Ernest Clarke.

The first case was a man, aged 46, who was first seen in October, 1908, and had become infected in August of the same year. After ten injections of soamin gr. v, the sight began to fail; and in February, 1909,

he had five more injections, when the sight again failed after the third. At the end of 1909 he had some mercury injections, and at the present time his vision was found to be only hand movements in the right eye, and $^{6}/_{12}$ pt. in the other; while both discs showed optic atrophy of the primary type; the vessels were normal, and there was no other change.

The other case was a man, aged 49, who came under observation in October, 1909, having become infected in August. After receiving nine injections of orsudan his sight began to fail, and the vision in both eyes had become reduced to counting fingers. Both discs showed primary atrophy, and the vessels were practically normal; in addition there were degenerative changes in both maculæ.

Mr. Clarke alluded to similar cases already described by others—viz., by Major Ward, Bagshaw, van Someren, and Leudie and Blaikie; and mentioned that soamin was a sodium para-amido-phenyl arsonate, and orsudan was a sodium tri-methyl tetra-acetyl amido-phenyl arsonate. It was probable that these drugs acted by producing degeneration of the ganglion cells of the retina, or possibly a secondary atrophy of a retrobulbar type.

Mr. Clarke urged greater caution in the use of these drugs, and careful attention to the general health before employing them.

Further Notes on Family Choroiditis.—Mr. R. W. Doyne.

Mr. Doyne remarked that he was preparing a family tree, some of the cases having been already described. The changes were mostly observed in the region of the disc and macula, but in other cases showed the margin of the disc mainly or solely affected, while, on the other hand, the macula in some cases was the only part where the condition was found. In one of the cases exhibited by Mr. Doyne there was a white spot, partly on the disc, showing that these areas were exudates, and not of atrophic origin.

Mr. Doyne summarized the condition as follows:—The first appearance of family choroiditis appeared in early adult life, though more commonly later. It might affect either the disc neighbourhood or the macula region, or both. It consisted of circular patches of exudation, which increased during middle life, and at last set up some irritation and pigmentary disturbance, for, though pigment was not always present, in some cases there was a good deal to be seen. During this stage the sight was not much affected, but in old age there was some optic atrophy with corresponding failure of vision.

Malcolm L. Hepburn.

CHRONIC TUBERCULOUS IRIDO-CYCLITIS.

By Elmore Brewerton, F.R.C.S. (Eng.).

I do not propose to enter into all the clinical varieties of tuberculosis of the iris and ciliary body but to consider only one type, of which I have unfortunately had two cases under treatment throughout the disease in the second eye. Both cases ended disastrously, both had already lost one eye, and gradually, in spite of treatment, lost also the other.

The first case was that of a young man aged 24, whom I saw in August, 1901. He gave the following history. Both eyes were quite normal till four years previously when keratitis began in the right eye; he was treated by Henry Power for 12 months with mercury to salivation; no improvement resulted. He then went to Brussels and saw Coppez who treated him also with mercury, pilocarpine and Turkish baths for 6 months; as no improvement had taken place an iridectomy was then done with disappointing results. The eye at this time was practically blind. Twelve months after the operation the left eye became inflamed and remained very irritable and painful for six months and then apparently recovered.

In October, 1900, inflammation returned in both eyes and he went to Wiesbaden. Pagenstecher took him into his Clinique and treated him with mercury for four months; then as the right eye was still painful an optico-ciliary neurectomy was done. Both eyes remained free from pain till July, 1901, when the inflammation returned.

The patient was one of five, all well and healthy, except the first child which died with convulsions at 9 months. He had suffered from mild pleurisy some years before and had had painful lumps on the tibiæ. No venereal history. When first seen in August, 1901, the right eye was soft and squared, cornea thickened and opaque so that the iris could not be seen. The eye was somewhat painful and irritable and quite blind. The left eye showed a patch of scleral inflammation up and out; in the anterior chamber lying against the back of the cornea and corresponding in position with the scleritis

was a yellowish tongue-shaped mass. There were two spots of keratitis punctata and some pigment on the lens capsule, no posterior synechiæ. Vision under atropine $^{6}/_{18}$; $\bar{c}$ $-.75$ D. sph. $= {}^{6}/_{12}$; with pin hole diaphragm $= {}^{6}/_{5}$.

A week later the right eye was excised. At this time two more patches of scleritis and nodules had appeared in the left eye and the iris was somewhat discoloured. Soon after this two posterior synechiæ formed and a flocculent white mass of lymph appeared in the lower part of the anterior chamber. Tension remained about -1.

Early in September the inflammation recurred, the nodules became more marked and the keratitis punctata increased; there was much pain for some days. Towards the end of September the patient was sent to Margate where at first considerable improvement took place. At this time there were four nodules in the anterior chamber, the pupil was partly dilated and bound down to the anterior capsule by three fleshy whitish adhesions. The anterior chamber was filled with a gelatinous mass which obscured the details of the iris and fundus. Vision was reduced to $^{1}/_{60}$.

After another attack of pain and inflammation it was decided to try the effect of x-ray exposure; there was a considerable improvement at first then another recurrence. The nodules became quite flat and the aqueous cleared; the pupil was almost completely blocked with lymph. The vision was now only hand movements. Field full.

It was decided to continue the x-ray exposures; ten days later much pain again; x-rays given up and pain ceased.

I did not see this patient again for four months; then a great change had occurred; secondary glaucoma had appeared, the cornea was slightly hazy, anterior chamber absent, the pupil was partly dilated and fixed, and the iris was much atrophied. No red reflex could be seen by the ophthalmoscope. Vision, no perception of light. Tension $+3$.

In this case although a diagnosis of tuberculosis was made in the early stage, tuberculin was not used owing to the danger of a local reaction. Treatment consisted

of general tonics, cod liver oil, etc., and locally atropine and fomentations with complete rest to the eye.

The excised right eye after division showed that the cornea was much thickened and opaque; the iris was in contact with the cornea and bound down to the lens. Behind the lens was a mass of connective tissue with the detached retina incorporated in it.

Microscopically no tubercle bacilli could be discovered, the iris, ciliary body and anterior part of the choroid showed much round celled infiltration and proliferation of pigment cells. The mass behind the lens consisted of organised granulation tissue with remains of retina; a few giant cells were found.

The second case was that of a lady aged 30, unmarried, whom I saw first in April, 1908.

She gave the following history. In 1905 both eyes suffered from iritis and recovered. Twelve months later the iritis returned in the left eye and the right gradually failed till only perception of light remained. The right eye had been perfectly well till a week ago.

Patient had had 17 operations for glands in the neck during the last 7 years and had recently been undergoing x-ray exposure for these glands. She had suffered for years from a form of rheumatoid arthritis of the joints of the fingers and toes, causing much distortion and almost preventing the patient from walking or using her hands.

When first seen the right eye showed a well marked patch of scleritis up and in extending into the cornea as a triangular interstitial opacity. The lower half of the cornea showed no definite spots of keratitis punctata but a general smudge on Descemet's membrane, no doubt due to endothelial changes. There were a few iritic adhesions. Vision $^{6}/_{9}$ partly. Tension slightly diminished. After homatropine the fundus was seen with difficulty and appeared to be normal.

The left eye was shrunken, cornea clear, anterior chamber very shallow, iris thickened and muddy looking, pupil contracted, bound down and filled with lymph. Tension -1. Vision = good perception and projection of light.

During the following ten days the inflammation in the right eye increased, minute spots of keratitis punctata

appeared and the iritic adhesions became more fleshy. Tuberculin treatment was now commenced; 2 injections of $^1/_{5000}$ milligram, T.R. at intervals of 10 days, then 2 injections $^1/_{2500}$, and then $^1/_{1000}$ every fortnight till the end of August. After the third injection a steady improvement took place in the appearance of the eye; the vision remained poor owing to vitreous opacities.

In September the patient went to Folkestone for a month and sight became very much worse at the end of three weeks owing to a rapid increase in the vitreous opacities. When next seen hardly any red reflex could be obtained; vision was now reduced to $^1/_{60}$. Tuberculin injections were continued from October till January with marked improvement; then after six weeks interval $^1/_{2000}$ milligram was given every fortnight till August, 1909. At this time the vision had sufficiently improved to enable the patient to distinguish the cards of a small Patience pack. The left eye now had no perception of light although the external appearances had not changed.

In August, 1909, the injections were left off and the patient went to Eastbourne for four weeks. On her return, although her general health was much better, the vision had sunk to counting fingers at 10 inches. The fundus showed a faint red reflex only in periphery. Field of vision good. The injections were resumed, $^1/_{2000}$ every two weeks, but vision slowly sank owing to increasing vitreous opacities and posterior cortical lenticular opacities. Tension reduced to -3.

The projection of light had failed on the nasal side and below no doubt due to detached retina, and the condition was now quite hopeless.

A noticeable point about this case is that on each occasion when a short holiday was taken a severe recurrence took place. On the first occasion it took three months to get back to the previous condition and since the second holiday she had steadily lost ground.

The chief difficulty in such cases as these lies in the diagnosis. It is impossible to prove that either case was due to tuberculosis; the evidence is only presumptive. In the first case the absence of venereal history, either hereditary or acquired, and the resistance of the disease to mercurial treatment practically excludes syphilis.

The microscopical examination of the blind eye is on the whole what one might expect from any intra-ocular destructive inflammation years after the inflammation had subsided.

The second patient had undergone 17 operations for tuberculous glands in the neck.

In both cases the appearance of the inflamed eye was very suggestive of tubercle and the course of the disease, chronic inflammation with periodical relapses, was similar in each.

The point I wish to bring out is the advisability of early treatment with tuberculin in all cases of chronic iridocyclitis when the type of the disease is suggestive of tubercle and when syphilis can be excluded by Wassermann's test.

I feel convinced that these two patients might have been cured if tuberculin had been used before the first eye had been lost.

MINERS' NYSTAGMUS AND FORMIC ACID.

By Archibald Stanley Percival, M.B., B.C. (Cantab.),

Senior Surgeon to the Eye Infirmary, Newcastle-upon-Tyne.

I have lately been using formic acid in the treatment of miners' nystagmus and have had some striking results. My object in publishing these notes is to ascertain if the experience of others corroborates my belief in its efficacy, or if a wider experience will show that I have formed too hasty a conclsuion. I know well that the originator of a new method of treatment is always inclined to take too rosy a view of its curative value.

Hearing that formic acid had been recommended in paralysis agitans and kindred disorders, I tried it on some of my cases at the Eye Infirmary, always enjoining them to give up work underground. Last year a pitman came to the Eye Infirmary from Yorkshire with nystagmus, but when I gave my usual instructions about giving up work underground, he said that that was what they had told him at his local Infirmary, but that a

friend of his had told him that I could cure him while continuing his pit work, as he himself had been cured in six weeks while still "holing." This was news to me, but I allowed this pitman to continue his work and ordered him formic acid. He sent me a card some months afterwards saying that he was quite cured.

Two months ago I saw another case with a persistent nystagmus that could not be stopped for a moment even after screwing up his eyes. He had been off work for 18 months and had been regularly treated at another Infirmary. It was the most marked case I have ever seen after a period of rest. I gave him m v of formic acid (25 per cent. sol.) in water three times a day. The next week I increased the dose to m x, and the following week the nystagmus was only elicited on his looking upwards. He is now working above ground.

REVIEWS.

Dr. Richard Cords (Leipzig). **Experimental and Clinical Experiences Concerning the action of Scharlach Red in Corneal Diseases.** *Klin. Monat. für Augen*: Jan. 1910.

Dr. Cords opens his paper with reference to the work of Fisher (1906) who injected scharlach red in oil into the tissues of rabbits' ears and observed that this resulted in proliferation of the tissue cells and connective tissue so that the tissue took on a myxomatous appearance and where the surface epithelium proliferated it resembled a carcinoma. He next mentions the work of Wessely on rabbits. This investigator injected scharlach red oil under the conjunctiva of the lid and he found that there resulted a proliferation of the epithelium not only of the conjunctiva but also of the ducts of the meibomian glands. Injection under the conjunctiva bulbi gave rise to proliferation at the limbus only. When the scharlach red oil was injected into the parenchyma of the cornea it remained there for months until reabsorbed and it brought about no changes in that tissue. The effect of injection into the anterior chamber was a little thickening of Descemet's endothelium.

But besides these experimental researches we are interested in the therapeutic value of scharlach red. From a surgical point of view it has been investigated by Schmieden and after him by many others. Its value has been proved in cases of fresh granulation tissue, as, for example, burns, large deficiencies after operation for carcinoma, and as a dressing for

Thiersch skin grafting. The resulting scars possess a thick healthy epithelial covering which presents throughout a normal appearance. It has also been reported of value in dirty granulating wounds. Wolfrum and Verf used scharlach red in the treatment of different diseases of the cornea. It did not appear to have much effect on simple erosions, but was successful in deeper and more extensive loss of tissue. In the after treatment of ulcus serpens, descemetoceles, and corneal fistulæ, it proved of much service.

Scharlach red is a red-brown powder which melts at 184°–186° and decomposes at 260°. It is amidoazotoluoazo-β-naphthol and is closely related to Sudan. Its reaction is neither alkaline nor acid. It is insoluble in water, dissolves on the contrary in chloroform in proportion 1 : 14; it is easily soluble in phenol, fats, and fatty oils, as, for example, heated paraffin and vaseline. Its formula is

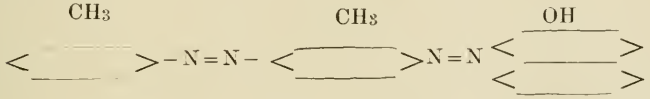

In an ointment it is important that it be finely divided and well mixed. Schmieden advocates that the dye should be first dissolved in chloroform, but Reinhardt says the warmed ointment basis should be sufficient. Dr. Corls used 5, 8, and 10 per cent. ointment. Auerbach says 4 per cent. ointment should have sufficient action.

Dr. Corls performed his experiments on rabbits (with one exception, viz., a cat) because he thought their eyes would behave similarly to human eyes. Clinical experience has shown the action on human eyes to be more constant and striking than in animals. He divides his investigations into four different groups and quotes examples from each. Before doing these experiments however he tried the action of ointment on the normal eyes. In rabbits 10 per cent. ointment on no occasion gave rise to any irritation. The daily application of ointment for 3 or 4 weeks was entirely free from action on normal tissue. In disease of the human eyes sometimes indeed the ointment did act in an irritable manner. This was probably due to a trace of chloroform, which is always present in fresh ointment, and is naturally a severe irritant.

Group I. Effect on epithelial defects of the cornea. Artificial abrasions of rabbits' corneæ were brought about. In each case both eyes were affected but only one treated with 5 per cent.

scharlach red ointment, which was applied twice daily. It was found that the epithelium of the eye so treated began to regenerate first.

Group II. Effect on defects of the corneal stroma. In order to inflict like injuries on the corneæ of a rabbit Dr. Cords used v. Hippel's trephine. He records several experiments. One eye was always treated with scharlach red ointment varying from 5 to 10 per cent. and the eyes were examined histologically afterwards. In the eye treated with the ointment he found a quicker regeneration of the corneal tissue with more marked cell increase and a quicker and healthier formation of epithelium. A typical epithelial growth did not take place.

Group III. Effect on corneal ulcers. Corneal ulcers were artificially produced in rabbits by inoculating their corneæ with pure culture of streptococci. These were treated with 10 per cent. scharlach red ointment. In two experiments quoted in the paper the corneal ulcer went on to perforation and prolapse of iris, but in the third, which was inoculated with staphylococcus pyogenes albus, recovery took place in 22 days without perforation. These experiments show that scharlach red has little or no antiseptic property.

Group IV. Effect in perforating wounds. Dr. Cords says that it was not easy to produce similar perforating wounds in the two eyes. The cases he quotes again show that scharlach red has no antiseptic property. In these experiments the cornea was trephined and the centre perforated to let aqueous escape. Four experiments are reported fully, including the microscopic appearances afterwards. The ointment in varying strength was used and had a beneficial action.

Finally, Dr. Cords gives records of ten clinical cases treated with scharlach red.

Case 1. A. K., æt. 44, suffering from central serpiginous ulcer of right cornea. Fifteen days after, when the ulcer was clean, 5 per cent. scharlach red ointment was used twice daily. Two weeks later the ulcer was healed and there was a firm scar covered with epithelium.

Case 2. H. L., æt. 68, suffering from ulcus serpens of right cornea. This was twice cauterised. Perforation took place and the hypopyon escaped. Two weeks later 10 per cent. scharlach red ointment twice daily was begun and a week later resulted in a good fairly transparent scar with uneven surface.

Case 3. H. L., a baby 8 days old, suffering from ophthalmia neonatorum with circular central ulcer of cornea, which went

on to perforation and prolapse of iris. Then 12 days afterwards was treated with 8 per cent scharlach red ointment and the result was a firm scar with anterior synechiæ 15 days later.

Case 4. W. H., æt. 2, suffering from eczematous ulcers of the cornea. A resulting descemetocele was treated by 8 per cent. scharlach red ointment and 3 days later the protrusion had disappeared.

Case 5. H. P., æt. 65, suffering from corneal ulcer due to diplobacilli and pneumococci. This was treated with zinc but developed a large central descemetocele. Five per cent. scharlach red ointment was used twice daily. The descemetocele had disappeared in about ten days and in its place was a firm fairly transparent cicatrix. The patient was again seen five months later and the scar found strikingly clear though the surface was uneven.

Case 6. S. T., æt. 8, had perforated eczematous ulcer with iris adherent and no anterior chamber. The ulcer was treated with oxide of mercury ointment till clean and four days later the anterior chamber was still unformed. Treatment with scharlach red ointment 8 per cent. twice daily was begun. Next day the anterior chamber was restored and two days later there was bulging with the iris adherent. Three weeks after the first visit the site of ulcer was quite even and the eye free from irritation. Xeroform ointment was then used and a good firm scar with anterior synechiæ was the result.

Case 7. L. S., æt. 50, with a large spreading ulcus serpens which had perforated. This became blocked by iris which protruded. It was treated with 10 per cent. scarlach red ointment twice daily. Just over two weeks later the bulging had disappeared and there was a thick cicatrix at the site of prolapse.

Case 8. J. S., æt. 54, suffering from a traumatic ulcus serpens which after many weeks' treatment perforated. It was treated with 5 per cent. scharlach red ointment twice daily. In course of healing a descemetocele developed in the scar and this continued to enlarge. Tension was raised in the eye. An iridectomy was performed and then the descemetocele disappeared and a good thick opaque scar resulted.

Case 9. W. F., æt. 58, had a central ulcus serpens which was twice cauterised. A week later it was treated with 5 per cent. scharlach red ointment and a good scar formed. There was a relapse afterwards, the eye having been treated with xeroform

ointment. The former ointment having been resumed it healed and a firm white polished scar resulted.

Case 10. S. L., æt. 53, had been under treatment for some time for lagophthalmos due to cicatricial contraction. Then there occurred a corneal ulcer due to the diplobacillus only. The whole cornea was involved in spite of the treatment with zinc. The ulcer perforated and a fistula formed. It was treated with scharlach red ointment 8 per cent. every two days, later once, and then twice a day. The fistula became blocked by a plug of granulation tissue. It became firmly closed, the bulging entirely disappeared and the whole surface was polished but uneven. The scar was non-transparent and the iris adherent.

In conclusion Dr. Cords remarks that after considering his experiments and clinical observations on the action of scharlach red in corneal affections he can say that in almost all the cases it hastened the regeneration of the stroma and the process of cicatrisation. This is in agreement with the findings of Fischer and Wessely. Scharlach red appears to have no antiseptic properties. It is to be recommended for use in clean corneal ulcers, especially when deep, in descemetoceles, and in cases of small iris prolapse or when fistulæ are left behind.

BEATSON HIRD.

COUTELA and VELTER. **A Case of Traumatic Homonymous Hemianopia.** *Archives d'Ophtalmologie*, March, 1910.

THE description of this case is briefly as follows: A woman of 27 years was shot at point-blank with a revolver. For several minutes she was rendered unconscious and on recovering was able to walk to the hospital. On arriving there she had lost a considerable amount of blood and complained of a heavy feeling in the head, giddiness and nausea. A circular wound, 5–6 mm. in diameter was found in the right occipital region, 2 cm. from the middle line and a little below the external occipital protuberance. A small quantity of brain substance was protruding through the wound. The only symptom discoverable was a left homonymous hemianopia, otherwise the patient was fairly comfortable, but vomited a little during the succeeding night. On the following day her temperature was 38·7° and the skull was trephined in the area of the wound: spicules of bone and a large amount of blood clot were removed

through this aperture. The temperature became normal on the same evening and remained so throughout the further progress of the case. During the following days an encephalocele developed, and a radiograph discovered the bullet in its interior, flattened but quite superficial. The general condition of the patient was excellent. On carefully examining the fields of vision a complete left homonymous hemianopia was present, sharply defined by a line practically vertical. And, a point which the writers lay particular stress upon, this line of demarcation went through the fixation point in both eyes. There was a slight concentric contraction of the right half of each field, for white and colours. The visual acuity $= {}^{7}/_{10}$ in each eye: reading and writing were of course extremely difficult. No motor or sensory disturbance was present and the skin and tendon reflexes were normal.

About a month later the bullet was extracted from the encephalocele without difficulty, and the latter commenced to retract.

When the patient was examined three months later, her general health was quite good, the hemianopia was precisely the same in extent, but a faint perception of light was present in the blind area extending out as far as 55° in the left and 60° in the right eye. The concentric contraction of the right halves of the visual fields had almost entirely gone.

Comparatively few records of bullet wounds of the visual centres and tracts exist. In the Franco-German War one case of bilateral blindness and two of hemianopia were noted: in the Transvaal War, Makins reported 3, and Critchett and Fisher 4, such injuries: in the Russo-Japanese War, Tatsuji-Inoye recorded 6 cases of homonymous hemianopia, 4 of inferior hemianopia, 2 superior quadrant and 2 inferior quadrant hemianopias. Wilbrand and Saenger could collect only 20 cases of bullet wounds of the visual centres.

Cases of hemianopia uncomplicated by other cerebral lesions, such as hemiplegia and hemianæsthesia, are recorder by Tscherning, Hense, Makins (2), Fisher, Von Bergmann, Bishop Harman and Bradburne.

Cases complicated with such lesions are reported by Von Limbeck, Eulenbourg, Abadie, Hartmann and Gamble.

In a small number only have autopsies been made. Eckridge found complete destruction of the left cuneus. Ratimoff found a large abscess in both occipital lobes. Léonard, a hæmorrhage in the second and third left occipital convolutions.

Viggo-Christiansen, destruction of the superior half of the optic radiation on the right side, and of the anterior part of both lips of the calcarine fissure. On the left side the bullet had traversed the corresponding region of the internal aspect of the occipital lobes and optic radiation.

Donath found a bullet in the right occipital lobe which also had destroyed the visual tract in the region of the internal capsule. Cases of double hemianopia due to bullet wounds of the occipital lobes are reported by Beck, Arndt, Von Bergmann, Saunders, Stevenson, and Pflüger.

Henschen relates a case of a child of 14 years, struck with a bullet in the occipital region to the right of the middle line, resulting in complete right hemianopia, and in addition a scotoma identical in both fields, in the superior quadrant of each left field. De Lapersonne and Grand quote cases of both superior and inferior hemianopias due to violent traumatism of the occiput. Henschen found a bullet in the second right occipital convolution which had produced diminished visual acuity in the left inferior quadrant of the field of vision of the right eye. Van Duyse reported a case where the bullet had entered the skull in the right temporal region and had produced a scotoma of the superior left quadrant of each field.

In the case quoted by the writers the following points are remarkable, viz.:—

The sharply defined hemianopia without motor or sensory trouble.

The concentric contraction of the right halves of the fields of vision, and the reappearance 4 months after the accident of a certain amount of light perception in the blind halves.

The hemianopia was limited by a vertical line, which, contrary to what is usually observed passed through the fixation point, so dividing the macular region of each field.

The bullet was a small one, 5–6 mm., and only possessed a feeble penetrating power, for though it was fired at close quarters it was found lying quite superficially. The fact that a certain amount of light perception returned in the blind area raises the point as to the localisation of the centre for light perception.

In this latter connection Bard cites 3 cases in which a certain degree of light perception existed in the hemianopic areas. Wilbrand considered that in the visual cortical area were three distinct superimposed layers, for colour, form, and light vision respectively, but no known anatomical facts justify

this idea. Perhaps amid the optic radiation certain fibres have the function of conduction of light impulses only, and these fibres may be more resistant to injury. In support of this view is the well-known fact that a slowly progressive lesion occasionally will first destroy colour vision (the most highly specialised visual faculty), then form vision and finally the cruder faculty of light perception.

Bard has suggested that there are certain homolateral fibres which do not decussate, but go direct from the retina to the cortex on the same side, and that these fibres conduct light perception only. The concentric contraction of the right halves of the fields found in the case quoted cannot be put down to traumatism of the left occipital region but probably may be included under the phenomena of hystero-traumatism.

As a rule in such lesions of the occipital cortex producing hemianopia, the macular region of the visual field escapes injury, and according to Wilbrand and Sänger it is rare to find the demarcation line going through the fixation point. Indeed Henschen is sceptical as to whether this ever occurs; but Wilbrand, out of 77 cases of hemianopia due to various causes, found 29 in which the hemianopia was of the latter type. He believed that in the majority of individuals the macular region is supplied by fibres, some of which cross to the opposite side of the brain, and some proceed to the visual centres on the same side; and also that a vertical strip of the retina above and below the fixation point is supplied in a similar way by crossed and direct nerve fibres.

This view is also held by Dejerine, Vialet, Henschen, Förster and Bernheimer.

Ramon y Cajal found in an embryo cat certain fibres which he considered to be macular fibres, dividing in the chiasma and sending a prolongation into each tract, thus connecting each cone at the macula with the cortical centres on each side.

Wilbrand and Sänger suggest that in the macular region, crossed and direct fibres supply alternate cones.

Von Monakow thinks that the two maculæ are connected with a considerable number of cellular elements in both external geniculate bodies, and that from these cells radiate very numerous branches which spread over the whole surface of the cortical visual centres, extending beyond the usually ascribed limits of these regions.

Rochon-Duvigneaud agrees with Wilbrand; he contends that each cortical centre innervates both maculæ. But that this

arrangement is not constant is proved by the present case; and it is not surprising that variations are possible when one considers that it is only in the most highly developed members in the animal scale that macular fixation is present; and that between the completely crossed visual fibres of the lower animals and the partially crossed fibres in man many intermediate arrangements may exist; the bilateral innervations of the maculæ being merely the highest development of the visual apparatus.

WILFRID ALLPORT.

SYDNEY STEPHENSON and W. P. HERRINGHAM. **On Puerperal Amaurosis.** *The Ophthalmoscope*, March, 1910.

THE authors place on record two cases which were recently under care at Queen Charlotte's Hospital.

The first case is one of albuminuria and headache in a primipara followed shortly after delivery by temporary blindness without ophthalmoscopic changes. No eclampsia. Recovery.

The second is one of albuminuria, temporary blindness without ophthalmoscopic changes, and eclampsia in a primipara. Recovery.

In the first case a woman of 23 years lost her sight completely and suddenly soon after normal labour, before which she had suffered from severe headaches and her urine was known to contain albumin. At the same time as the sight was lost she was affected with headaches, vomiting and became semi-somnolent. The pupils retained their direct action to light. Improvement in sight speedily set in. Two days after delivery she had perception of light. On the following day large objects could be recognised. Five days after delivery she could count fingers at six feet and on the next day she could read ordinary newspaper type with one eye. Twenty-one days after delivery vision with correction was R.E. $^{6}/_{6}$, L.E. $^{6}/_{12}$, 1 letter.

In the second case delivery was by forceps under chloroform. As soon as the patient recovered from the anæsthetic she complained of headache and vomited once. It was then found that she was completely blind. The pupils preserved their normal reaction. After six hours of blindness she developed a typical eclampsial fit, which lasted for about a minute and was followed by a period of unconsciousness lasting about 10

minutes. When she regained consciousness sight had returned. Four days after delivery the patient could read and readily distinguish things about the ward. She left the hospital a fortnight later.

About 50 cases are cited from the literature on the subject. In these cases amaurosis or amblyopia, apparently not dependent upon uræmia, supervened during pregnancy, labour or childbed. Many were accompanied by eclampsia and nearly all by albumin in the urine. It is probable that the ætiology of these cases is essentially the same whether they occurred before, during, or after labour, and the authors make the following comments upon them:—

1. The existence in most cases of convulsions—so called "puerperal eclampsia."

2. The presence in the urine, which is usually excreted in scanty amount, of albumin, blood, and various kinds of tube-casts.

3. The existence of headache.

4. The co-existence of œdema of the eyelids, face, and elsewhere.

That the defect in sight may be a premonitory sign of puerperal eclampsia is shown in the authors' second case as well as in others cited. It is more common for the amblyopia or amaurosis to supervene after one or more "fits" have taken place.

Eclampsia need not occur, as in the authors' first case, where the blindness alone occurred. The occurrence of eclampsia in some pregnancies and of amaurosis in others is an argument against the dependence of one on the other, and in favour of a common causal factor. Moreover eclampsia may occur in one pregnancy and amaurosis in another as in a case quoted.

Eclampsia, and so amaurosis, according to modern views is due to a poisoning of the mother by products of her own metabolism, and possibly those of the fœtus which her excretory organs are incapable of removing. The amaurosis in association with the severe vomiting of pregnancy is mentioned as being most probably of a similar nature. The authors draw the following conclusions:—

1. That a form of amaurosis or amblyopia, not accompanied by ophthalmoscopic signs, or, at least, by none adequate to account for the condition, may supervene during pregnancy, parturition, or the puerperium.

2. That rarely it may assume the form of a hemianopic defect or of a central scotoma in the field of vision.

3. That it is often associated with such signs and symptoms of toxæmia as headache, œdema, eclampsia and scanty urine, containing albumin, casts and blood.

4. That it appears to form one of the rarer manifestations of toxæmic poisoning.

5. That it is not proved to be dependent upon uræmia, although it has usually been confused with so-called "uræmic amaurosis."

6. That it recovers, as a rule, completely within a few hours or days.

The paper concludes with a note by Herringham in which he includes notes of three cases more or less analogous to those reported by Stephenson.

In Case 1 there was chronic nephritis, toxic amblyopia and slight choroiditis in a primipara. The patient recovered.

Case 2 was one of eclampsia and amblyopia.

Case 3 was one of puerperal eclampsia and temporary amaurosis.

Chronic renal disease is present in some of the cases of amblyopia associated with pregnancy. He maintains that the subsequent history of good health in so many cases excludes the possibility of it always being present. Moreover albuminuria though almost always, is not always present. He disposes of the contention that the condition is due to an acute or subacute nephritis, by the fact that he has never seen transient amblyopia without fundus changes except in connection with pregnancy.

It occurred to him that it would surely be met with in cases of scarlatinal nephritis if it was associated with nephritis, and he accordingly consulted Foord Caiger on the subject. The latter's opinion founded on his vast and special experience was entirely contrary to the supposition. J. F. Cunningham.

N. Forti (Sienna). **The Fields of Vision during Gestation.** *Archivio di Ottalmologia*, xvii., 8.

Some years ago two observers, Bellinzona and Tridondani, made a series of observations upon the fields of vision in pregnant women. They were careful to choose patients in whom there was no other disturbing cause which might have injuriously affected the accuracy of vision and thus have

vitiated their statistics. They believe that they were able to establish the following conclusions:—

(*a*) That a bilateral limitaton of the fields does occur in pregnancy.

(*b*) That this restriction consists, not in a uniform or concentric restriction, but in a bitemporal pseudo-heminanopsia, a limitation of the fields in the temporal area of each.

(*c*) That in nearly every case the field of the left eye was more severely affected than that of the right one.

(*d*) That these alterations are more evident in the primipara than in those who have borne several children, and that they progress as pregnancy proceeds.

(*e*) That there is no tendency to dyschromatopsia or to achromatopsia, the colour fields following their usual order of white, blue, red and green.

(*f*) That the accuracy of vision is not in any way interfered with.

The authors believe that they have been able to establish a relationship between the gravid state and certain visual manifestations which are truly functional rather than the effects of definite pathological alterations, and they support their assertions in part by the observations of one of their number who in the course of investigations regarding certain nerve reactions in pregnancy was struck by the analogy or resemblance between these reactions and those in the condition of hysteria.

Forti has himself repeated the procedure and examined in numerous cases the field of vision in pregnant women whose condition was normal otherwise, and he has arrived at the following conclusions:—

(*a*) That there is a very slight limitation of the field in the nasal half of the field, and a decidedly more definite restriction in the temporal.

(*b*) That as regards right eye and left there is no difference: they are equally affected.

(*c*) That the alteration is more marked in the primipara, but that the advance of pregnancy makes no difference: certainly not for the worse.

(*d*) That the acuteness of vision remains unaffected, and there is normal amplitude of accommodation, but when the patient is compelled to keep the eyes fixed upon an object for a certain space of time very definite hysterical symptoms began to manifest themselves.

As will thus be seen, Forti is quite unable to confirm the statement of Bellinzona and Tridondani that the left eye is

more seriously or more frequently affected than the right; he suggests that possibly the authors have been misled by examining the right eye first as a routine; in the case of any functional defect or lesion such as has been suggested the eye examined after the fatigue of the other would be sure to exhibit the lesion spoken of. The two authors do not say whether they consistently examined the eye of one side in particular before that of the other, but Forti throws out the suggestion for what it may be worth. The "fatigue-field" would in that event show itself with more constancy in the eye examined later than in the other. He confirmed the truth of this in the cases he examined, for if he took the field of the right eye before that of the left, it, the right, always had the better field, and vice versâ.

There is a fairly clear distinction between hysterical restriction of the fields and that seen in the gravid patient in that in the former the limitation is (in the ordinary though not precisely in the etymological sense of the word) concentric, while in the latter the tendency is rather towards hemianopic, or at all events the reduction is more obvious in the two temporal fields than in the two nasal halves, but it is just possible that this apparent difference may be related to the usual custom of examining first the nasal field and then the temporal, in which case the fatigue-symptom of additional limitation would of course appear in the temporal half. This would provide an additional proof of the necessity of examining the fields not in various meridians but in concentric circles. By repeated trials Forti has thoroughly satisfied himself of the fact as stated in regard to the reduction of the field.

With the opinion of Bellinzona and Tridondani that these phenomena are more common in primiparæ Forti is so far in agreement, but he doubts if they are correct in saying that the symptoms increase as pregnancy proceeds; if so, that is rather contrary to the usual course of "sympathetic" reactions in pregnancy. Further, Bellinzona and Tridondani's results as regards the colour fields he does not confirm at all; they say that the colour fields are restricted in a manner similar to that of the white field, and that neither achromatopsia nor dyschromatopsia occurs among those patients. From this view he dissents altogether, and finds that constantly the colour fields are irregularly altered, their boundaries crossing one another, the limits for some colour extending beyond those for white, and so on. In short his results agree with the typical hysterical indications.

Among his patients he did not find any reduction of visual acuteness or any weakness of accommodation, though fatigue on fixation was well marked. W. G. S.

LOHMANN. **On the Theory of the Genesis of Myopia.** *Klin. Mon. f. Aug.*, April, 1910.

IN the review of current theories of myopia which occupies the first part of this article, that of increased intra-ocular tension during convergence finds little favour. Stilling's theory of the gradual moulding of the eyeball into the myopic form by the constant pressure of the superior oblique tendon in cases of unusually low orbit finds more favour but is manifestly insufficient to account for all cases. The author's own contribution to a complete theory is that the innate tendency to growth of the eyeball is greater in some individuals than in others. The effect of excessive use of the eyes for near work during adolescence is not disputed, but the author suggests that the effect is due not so much to the direct action of the converging number as to the increased blood supply brought to a tissue with a predisposition to excessive growth. His argument may be summarized thus:

1. The ratio between the size of the eyeball and that of the orbit is widely different in the adult from what it is at birth. The growth of the eyeball is therefore determined not by that of the orbit but by an innate tendency.

2. This innate tendency especially affects the sclera. It is inherited but may be favoured by an increased blood supply caused by excesssive use of the eyes during adolescence. The retina and choroid are only affected to a less extent, being more under the influence of the optical requirements of clear vision. (In this connection Straub's theory of the origin of emmetropia is referred to, *v.* "Ophthalmic Review" for 1909, p. 223.)

3. The different forms of conus are explained by the varying extent to which the elastic lamina of the choroid keeps pace with the growth of the sclera, and by the different forms of enlargement which the sclera itself may undergo, the centre of growth being usually at the posterior pole but sometimes to its nasal side.

As the author himself suggests, the causation of myopia is probably complex, no simple explanation being sufficient to meet all the varieties that occur.

A. H. T.

Major Kilkelly, I.M.S. **Lt-Colonel Smith's Operations in Bombay.** *Indian Medical Gazette*, May, 1910.

Several papers on extraction of cataract in the capsule were read before the Bombay Medical Congress in 1909, and a review of the more important of these papers was published in the "Ophthalmic Review" in November of the same year. All the papers referred to were written by surgeons whose experience had led them to advocate the method of operating now commonly known as Smith's operation.

The recent brief paper on this subject by Major Kilkelly, Ophthalmic Surgeon, Bombay, deserves serious consideration. Although the number of cases dealt with is small, they are recorded with more completeness and detail than many of the previously published reports from India.

In February, 1909, Major (now Lt.-Colonel) Smith operated upon 23 cases of cataract at the C. J. Ophthalmic Hospital, Bombay, at the request of Major Kilkelly, and the paper before us contains the record of these cases.

The patients were kept in the Hospital for periods varying from 15 to 27 days. The results are given in tabular form: the date at which the measurement of vision was made is not stated but presumably it was at the time of the patient's discharge from the Hospital.

The record of visual acuity is as follows:

Cases.	Vision.
1	$^6/_{15}$
2	$^6/_{20}$
7	$^6/_{30}$
3	$^6/_{40}$
4	$^6/_{60}$
5	fingers 10 to 18 ft.
1	moving bodies.

That the best vision obtained was $^6/_{15}$, and this in only one instance cannot be regarded as encouraging. The one case in which there was only perception of movement, occurred in a patient with granular lids, and infection of the eye followed: at the operation the capsule ruptured and some escape of vitreous resulted.

Accidents during operations.

Capsule ruptured	5 cases.
Escape of vitreous	2 cases.

Complications.

Incarceration of iris in lips of wound	5 cases.
Capsule tags in wound	4 cases.
Vitreous opacities	9 cases.
Iritis	7 cases.

The occurrence of iritis in 7 out of 23 cases is noteworthy; this number includes two of the instances in which incarceration of iris occurred. It has been claimed by some writers that iritis is not a frequent complication of this method of operating; not as frequent as in the older capsule-laceration method.

Major Kilkelly writes: "The results of these 23 operations performed by Lt.-Colonel Smith confirms me in the opinion I expressed at the Medical Congress last year, when I invited Lt.-Colonel Smith to operate at the C. J. Ophthalmic Hospital. I then stated that I had performed some 600 extractions in the capsule, but that I had given up the operation as a routine procedure, being convinced that the best interests of the patient were not considered if it were done save in exceptional cases. It is clearly shown by these cases that accidents occur, and a high percentage of bad results follow intracapsular extraction even when the operation is performed by Lt.-Colonel Smith, and for my part I now feel that the average patient is exposed to an altogether unnecessary danger by the operation."

In the same number of the "Indian Medical Gazette," the Editor gives an interesting and valuable *resumé* of a number of recent papers in various medical journals, all dealing with Smith's operation for cataract. This *resumé*, or the original articles, most of which are in American Ophthalmological Journals, will repay perusal by those interested in this subject.

J. B. L.

TROUSSEAU. **Cataract Operation in Old Subjects.** *La Clinique Ophtalmologique,* Oct., 1909.

OLD people must not be confused with aged people, thus, a man of 65 may be free from physical defect, whereas it is rare to find a man of 80 whose physical activity is not reduced to a minimum, a slight emotion or change of habit being sufficient to upset his equilibrium, and the smallest shock being enough to end his life. In practice it is impossible to determine by

his age alone that a man has become old. One must also remember that it is not fair to refuse even a very old man the pleasure of seeing, if only for a few months— all depends on the patient. Knowing what may happen, operation should only be undertaken with special precaution. The traumatism of the actual operation is so slight that it can be safely disregarded. If the patient is suffering from an affection which may kill him soon, operation must be refused; and one must not forget that in very old people rapidly fatal illnesses may happen, of which the cause may be anything but obvious. Trousseau operated on a man æt. 85, who died 4 or 5 days afterwards of intestinal obstruction—*apparently* he had been in good health.

Cerebral affections, however slight, are a contra-indication to operation. Precautions must be extreme where there is pulmonary congestion.

The urine must in all cases be examined qualitatively and quantitatively—the latter being regarded by Trousseau as the more important of the two; in fact he operates without fear on albuminuric or diabetic subjects, but not if urine is passed in small quantity.

Dangers to old patients—

(*a*) During operation } local dangers.
(*b*) After ,, } general ,,

(*a*) The same dangers as in all subjects, but tending more to hæmorrhage either from iris, or after expulsion of lens from collapse of globe in old people. Trousseau thinks cocain favours the latter condition, and uses it sparingly on that account.

(*b*) (1) Prolapse of iris, because of restlessness, or cough. (2) Slow healing of wound; 2 to 4 weeks in some cases, owing to defective vitality. (3) Secondary hæmorrhage more common in the old. (4) After first dressing an acute conjunctivitis may appear, in spite of aseptic precautions. The pus does *not* contain known virulent microbes, *e.g.*, pneumococcus, but in spite of this may cause iritis, infectious irido-choroiditis, and even panophthalmitis.

General dangers. Delirium generally appears first to third night after operation, is variable in form, from slight loss of knowledge of place, time and events, to furious delirium. It may indicate pulmonary congestion or uræmia, but is generally due to want of orientation, and to being bandaged up.

It generally yields to taking off the bandage and putting a pad only on the operated eye. The preoccupation due to the operation, the change of habits and abode, the relative isola-

tion, all work on the mind of the old man, and this with complete darkness excites him, and delirium results. Trousseau is opposed to a dark room as it is too depressing, and he only bandages one eye in nervous patients.

During the first 24—48 hours cerebral hæmorrhage or diabetic coma may supervene and may be due to mental shock of operation combined with previous ill-health. Pulmonary congestion and even pneumonia is too frequent to be due to chance, and is almost always due to lying on the back. If patient is a little delirious, tongue dry, and dry râles heard over the bases, he must be got up into a chair and kept there day and night. The bed is the danger in old people.

Fromaget and Trousseau have called attention to operative uræmia, a condition only seen in old people, and not necessarily in cardiac and kidney cases. Delirium comes on 24 hours after operation, the patient may vomit a little, and the quantity of urine suddenly falls to 200—250 cc. till anuria may come on and death ensue. Hence value of quantitative examination, which should be done daily during treatment. If any diminution occur, Trousseau orders a milk diet, injects caffein and gives theobromin. He considers it due to vasomotor spasm in vessels of kidney. E. Harries Jones.

Bentzen. **Holth's Iridencleisis for Glaucoma.** *v. Graefe's Archiv. für Ophthal.*, lxxiv. (*Leber's Festschrift*).

Bentzen reports upon 22 cases in which during the past two years he has relieved or attempted to relieve glaucoma by establishing subconjunctival prolapse or incarceration of iris. A detailed description is given of each case, and after this the main facts are shown in tabular form. Surely somewhat unnecessary in dealing with a mode of treatment which has now little to recommend it unless in quite exceptional cases! Bentzen's experience is not particularly favourable. In only the first half of the cases was a method attempted to which Holth's name may properly be attached, though it is a method which has been given up by Holth for some little time. A small peripheral tongue of iris was drawn out through a sclero-corneal incision under the conjunctiva. The small flap of iris was fashioned by iridotomy alone; there was no iridectomy, and the pupillary zone of the iris was left intact. At least this was the intention. The operation as designed was only carried out once. In two other cases the small flap was cut without division of the pupillary sphincter; but no visible incarceration of the flap

resulted, and the operation was therefore a failure. In the remaining eight cases the required prolapse was secured, but not without dividing the whole breadth of iris. The procedure was then changed to an iridectomy with subconjunctival inclusion of one pillar of the coloboma in the wound. This was accomplished in eight of eleven attempts. Twice the operator failed to draw out the iris through the small wound made. And another operation failed completely through vitreous loss and intraocular hæmorrhage. In the last case of this series the operation was subdivided. A preliminary iridectomy was performed and, later, at a subsequent operation, a subconjunctival prolapse was made. The author thinks this is the surest method of obtaining the desired impaction of iris.

Summarizing the results of the total 17 operations in which a prolapse was produced, in 13 cases the tension was satisfactorily lowered, though in 2 of the cases apparently only with the aid of a miotic. The remaining 4 operations failed to reduce the tension permanently to normal. Three of these eyes showed degenerative changes from advanced glaucoma. But the other failure—the last operation of the series—was most disappointing. The case seemed most favourable in every way. (The case, however, was only under observation 4½ months. Possibly the slight rise of tension which recurred might not have been permanent.) H. Herbert.

Stargardt. **On Injury of Dark-adaptation.** *von Graefe's Archiv für Ophthalmologie*, 73, 1.

In the introductory portion of this long paper the author discusses the physiology of normal dark-adaptation. Although in recent text-books, such as Axenfeld's, references to dark-adaptation are still based on the work of Aubert who found that maximal retinal sensibility was attained after ten minutes exclusion of light, Piper's more accurate researches have shown that hardly any alteration occurs during the first ten minutes and that only after this does the rise in sensibility take place. This rise may be slow or quick in different individuals and after thirty or forty-five minutes the maximum adaptation is reacted, when the retinal sensibility may vary between 1400 and 8400 times its original value.

For an explanation of the anatomical and physiological changes which underly the process of adaptation we are however practically dependent on theory.

The author is an adherent of the "Duplizitäts-Theorie" which

ascribes separate and specific functions to the rods and cones. The former can only be stimulated by light through the agency of the visual purple. They are colour blind and react to light stimuli which are so weak as to be below the threshold of the cones. These react directly to light, perceive colour and are affected only by relatively strong stimuli. The cones take practically no part in adaptation which according to this view depends on the visual purple, removed from the bleaching action of strong light, gradually accumulating and sensitising the rods.

A wide range of ocular affections was investigated with the object of ascertaining the rapidity of adaptation and the retinal sensibility attained in different conditions after forty-five minutes light exclusion.

Piper's adaptometer was used, consisting of a box 75 cm. long, containing a fifty candle-power lamp at one end in front of which at distances of 25 cm. are placed three partitions of milk glass each fitted with an adjustable diaphragm. The eye to be examined is first exposed to daylight for about half an hour and then the minimum illumination visible in the dark is obtained by the adaptometer. This gives the primary value and by reducing the illumination as adaptation progresses the maximum sensibility at any moment can be found. This is expressed as a multiple of the primary value and is obtained from scales attached to the diaphragms.

By means of a special perimeter and test-object having a variable illumination the field of vision was taken under similar conditions.

Among conditions of refraction, emmetropia and hypermetropia presented no peculiarities and the same held good for astigmatism although in two cases of mixed astigmatism a considerable reduction of adaptation was found associated with poor vision after correction. In anisometropia the adaptation was sometimes equal, more often better in the eye with the smaller error, especially in cases of myopia. No connection could be traced between the differences in adaptation found in these cases and any ophthalmoscopic findings, or the age of the subject, or variations in local or general pigmentation.

A considerable part of the paper is devoted to myopia. Sixty-eight persons were examined and the results are given in several tables and plates of curves showing the relation of the adaptation to age, to the degree of myopia, and to the amount of visible change in the fundus oculi. Great reduction in

adaptation was often present and on analysing the cases this was found to correspond for the most part to the last mentioned factor. In about 50 per cent. of the cases examined a reduced field was found and in most, but not all, of these, ophthalmoscopic changes were detected.

Under affections of the retina and choroid the author mentions opaque nerve fibres, Berlin's retinal opacity, retinitis, albuminurica, siderosis and intraocular hæmorrhage from various causes, in all of which reduction of adaptation was found.

Details are given of seven cases of retinitis pigmentosa, in nearly all of which the reduction in adaptation was extreme. By dark room perimetry it was found that this loss extended over a much larger area than that found to be scotomatous by the ordinary method. The author's view is that in this disease loss of adaptation precedes other visual disturbances. Unfortunately in the field reproduced it is not quite clear which area of shading is intended to represent the area of least retinal sensibility.

Fifteen cases of retinal detachment are fully discussed, especially in relation to the comparison of the field of vision as found by dark-room perimetry with that found by the usual method. This point is illustrated by comparative charts of several cases.

Stargardt considers that the field for white gives no accurate indication either of the presence of a detachment or of its extent, and that the colour field is in most cases unreliable, the field for blue showing the extent of a detachment only in a few cases. On the other hand, as adaptation is totally absent in the detached area, the dark-field indicates correctly the presence and boundaries of a detachment. Adaptation, once lost from detachment, never returns unless reattachment occurs.

Varying results were obtained in twelve cases of choroiditis. Reduction of adaptation was not always found and no constant relationship between the ophthalmoscopic appearances and the amount of adaptation could be established. The dark-field however showed scotomata corresponding to the diseased areas.

Great reduction of adaptation was found in tabetic atrophy. Here a much greater restriction of the field for white and especially for colours was found than of the adaptation field. Neither the appearance of the optic disc nor the vision corresponded in any way to the amount of adaptation.

In retrobulbar neuritis central scotomata were sometimes

demonstrated in cases in which the ordinary method failed to show them.

While admitting that many of these disturbances of adaptation have only a theoretic interest, Stargardt attaches practical importance to certain points brought out by his investigations. He believes that accurate information as to the boundaries of a retinal detachment or the extent of the lesion in retinitis pigmentosa is only to be obtained by taking the dark-field, because by this method functional disturbances may be detected which are not demonstrable by the older method. This conclusion is based on a comparison of charts of fields of vision taken by both methods.

In the absence of detailed statements as to the size of the test-object and the radius of the perimeter used for examining the light-field—as opposed to the dark-field—the validity of such comparisons seems to the reviewer to be extremely doubtful.

The author does not appear to have used Bjerrum's method of mapping out the field of vision, which is capable of detecting amblyopic areas easily missed by perimetry at 300 mm. with a test object even as small as 0·5 to 1·0 mm. Dark-room perimetry has however the advantage of being more easily applicable to peripheral lesions.

A list of nearly sixty references to the literature of the subject is appended. H. M. Traquair.

L. Pierce Clark and H. H. Tyson. **Horizontal Oscillation in certain Rare Types of Pontine Lesions resulting in Seventh Nerve Palsy.** *Medical Record*, Jan. 1st, 1910.

The authors refer to the observation which has been made that in Bell's palsy the upward, and inward or outward, rotation of the globe is a physiological and not a pathological process and may be shown in the normal individual.

The action of cocaine may abolish it or prevent it from occurring except on very firm closure of the lids.

In other words, Bell's sign would seem to occur under ordinary circumstances as a co-ordinated associated movement, but with spasmodic intentional lid closure the phenomenon involves other pontine elements.

The phenomenon of lateral oscillation, to which the authors particularly call attention and in evidence of which they cite three cases, is rarely seen. It occurs in some types of traumatic and rheumatic facial palsy, in which the nerve trunks or end

branches supplying the orbicularis palpebrarum are much involved.

In some cases at the beginning of lid closure the eyeball behaves as in Bell's phenomenon of facial palsy, *i.e.*, the eyeball is moved upward and inward or outward; the voluntary impulse attempts transmission over the paralysed facial nerve, but this being impossible, a part of the impulse overflows by way of the posterior longitudinal bundle, and a co-ordinated associated movement, that of Bell's phenomenon, occurs.

The new eye sign does not stop here. The more forceful attempts at lid closure being persisted in, the eyeball begins a see-saw oscillatory movement of 40 to 60 vibrations a minute. The eyeball on the side opposite to the facial palsy participates in the same movement. The excursion of movement and the time of oscillation are maintained synchronously with those on the side of the affected facialis. The new eye sign is partly under the control of the will at times. The movement may be inhibited completely or in part at the beginning or the end of attempted forcible lid closure. The oscillation is not controlled at all when the strongest effort at lid closure is made.

The lateral oscillation occurs only on attempts to close the eyes. No other facial movement or attempt at movement brings it out.

After this description the authors refer to the fact that careful analysis of all cases shows a paralysis of varying degree of conjugate movements. It is necessary in these cases that the lesion shall be in or shall have extended to the pons.

They also refer to a case reported by Schlesinger some two years ago where the limitation of conjugate movement was not recorded.

They conclude that "however one may view the matter, a lesion in the pons at the level of the sixth nucleus, probably hæmorrhagic in character, must be postulated to fully account for this rare eye sign in some cases of seventh nerve palsy, and that finally one must admit that the manner in which a steady tonic contraction is broken into a clonic contraction as seen in this eye sign is as obscure as that for ordinary nystagmus."

The normal association of the eye movements, however, enables us to understand something of the cause that produces it. They consider the sign is due to a disorder in conjugate movements of a paralytic nature. J. F. Cunningham.

RUDOLF TERTSCH (Vienna). **About Ring Abscess of the Cornea.** *v. Graefe's Archives für Ophthalmologie,* Vol. 73, 3.

THIS paper deals with seven cases of ring abscess of the cornea, due to various causes. Of these seven cases the first five fall into a group by themselves, and the remaining two cases are merely introduced to emphasise points of difference between the genuine ring abscess, and certain conditions where a ring infiltrate of different significance is sometimes found. Of the first group of cases two were due to injury by a splinter of iron, and in each case the foreign body was found in the eye at the histological examination; one was due to an injury by wood, one by stone, and one the result of an extraction of cataract.

Bacteriologically, cases 1 and 2 were due to the bacillus subtilis ,case 3 to the pneumococcus, case 4 to a streptococcus and a diplococcus, while case 5 was due to bacillus pyocyaneous.

In each of these cases there was a perforating corneal wound, a ring abscess, and panophthalmitis.

The bacteriology is described in detail and needs no comment.

The histology is also given in four of the above cases, where it was possible to examine the eye after enucleation: the findings were similar to those described by Fuchs in this Journal in 1903, and consisted, broadly speaking, of a primary necrosis of the inner surface of the cornea, together with a purulent infiltration in the periphery of the cornea, which took the form of a ring; for the rest of the eye the findings were those usual to cases of panophthalmitis.

Two of these cases require going into a little more fully. In case 1 the purulent contents of the globe were allowed to work their own way out, and the shrivelled stump was excised a month after admission.

When examined, the cornea appeared somewhat thickened, the epithelium proliferated, with wide in-sinking in the region of the wound.

The structure of the lamellæ was throughout well preserved, only the lamellæ were separated here and there by streaks of scar-tissue, spindle formed cells, and new blood-vessels. The corneal corpuscles though distorted in their arrangement, took the stain well. The scar tissue was broader and better marked in the region of the ring infiltrate. Bowman's and Descemet's

membranes were well preserved, except where the wound had penetrated them. The wound itself was full of granulation tissue. The cells of Descemet's membrane were absent.

Tertsch comments on the remarkable fact that in spite of the severity of the corneal condition on admission, yet one month later the cornea had so far recovered as to show only trifling changes.

In case 2 the histological findings in the cornea were similar to those described by Fuchs, the rest of the contents of the globe were in a state of purulent disintegration, and the sclera showed a remarkable amount of change: in its inner $\frac{1}{3}$ it was necrotic, while the outer $\frac{2}{3}$ was densely infiltrated with small round cells.

The remaining cases conformed to the findings described by Fuchs.

Case 6 is a case of ulcus serpens, which showed a ring infiltrate which at one spot reached up to the limbus, and at other spots was separated by a rim of more or less clear cornea 1 mm. broad.

Tertsch differentiates sharply between such cases of ulcus serpens, where the infection of the cornea is from before backwards, and cases of ring abscess where the reverse is the case, and the necrosis is in the posterior layers of the cornea, and is due to bacteria or their toxines, developing in the vitreous and uvea.

Case 7 is one of a melanotic sarcoma of the choroid, with ring abscess of the cornea, where the ring-shaped opacity formed the demarcation zone between healthy and diseased tissue.

The paper contains a mass of details on the bacteriological side, and there are full accounts of the results of experimental inoculations of cultures of the different bacilli in the eyes of rabbits.

Tertsch's conclusions are as follows:—

(1) The primary necrosis of the posterior corneal lamellæ is only a part phenomenon of a severe pathological change in the inner coats of the eyeball.

(2) This necrosis may be due to various poisons, toxins of either bacterial origin, or arising from tissue necrosis in tumours.

(2) This necrosis may be due to various poisons, either toxines of bacterial origin, or arising from tissue necrosis in tumours.

(3) In ulcus serpens a condition simulating genuine ring abscess may occur, and it is possible to separate such cases, as

in ulcus serpens the disease is a localised (at least in the beginning) affection of the cornea, and the rest of the eye may be preserved, whereas in ring abscess which is only a part of a severe destructive panophthalmitis, the eye is lost.

A copious bibliography is appended to the paper.

R. R. JAMES.

THE OPHTHALMOLOGICAL SOCIETY OF THE UNITED KINGDOM.

Friday, July 8th, 1910.

The President, Dr. G. A. BERRY, *in the Chair.*

CASES.

Mr. E. A. Dorrell showed a case of "Unusual Form of Anterior Cortical Cataract" in the left Eye of a man æt. 47.

Both eyes showed conjunctival and corneal scars, and the right eye had suffered injury. The left eye shows atrophic iris pierced by small pin holes, and a minute anterior synechia. The lens shows above the centre a clear grey fan-shaped opacity of ten rays lying in different planes, each ray is denser at the periphery than centrally. There are opacities in the vitreous. $V = {}^{6}/_{12}$.

Mr. Arnald Lawson showed a case of "Unusual variety of macula hæmorrhage, with anastomosis between the retinal and choroidal circulation."

The defect in the right eye was found out accidentally, and there is no knowledge of the cause of the hæmorrhage. Formerly he had frequent epistaxis. Vision is reduced to fingers.

The macula is mapped out by a trellis-like pattern of minute dark hæmorrhages, this is surrounded first by a ring of whitish-yellow spots and secondly by a dark circle, and thirdly by an outermost ring of buff tint which fades into the normal choroid. Cholesterin crystals are seen in retina and vitreous. There is also a curious anastomosis between an anomalous retinal vein and the choroidal or extra-ocular circulation.

Mr. Arnold Lawson showed a case of alternating convergent strabismus in which the patient habitually employs the apparently squinting eye for fixation whenever the object is to one or other side of the median line.

Mr. Inglis Taylor showed a case of Tubercular Iritis.

A youth of 16 years was seen in May last with K.P. and ciliary exudate formed on the iris which later on became well defined tubercles. Enlarged glands were found in axilla and over both clavicles but no lung trouble.

Mr. H. L. Eason showed a case of massive exudate of the choroid. (? subretinal).

PAPERS.

Dr. Geo. Mackay (Edinburgh) read a note on "A Case of Interfascicular Endothelioma of the Choroid situated at the optic disc," of which the pathological report was made by Mr. Treacher Collins.

A man, æt. 60, of full habit, suffered attacks of temporary faintness, and later found a defect in his right eye. Direct vision was fair, but the nasal field was lost. The disc of the eye showed a grey mass of tumour substance with fine inherent vascularisation; the border was round and clear cut towards the macula, but sloped gradually on the nasal side. The mass appeared to project forward 2 m.m. The tension of the eye was slightly raised. The case was watched three months, then excision was decided upon; the nerve was cut far back. On examination it was found that the tumour mass extended backwards into the nerve 7 or 8 m.m., and an isolated excrescence was noticed on the sheath at a distance of 14 m.m.

Mr. Treacher Collins examined the eye and gave it as his opinion that the case was one of malignant new growth, an interfascicular endothelioma of the choroid.

Mr. J. B. Lawford. Further report on a case of Optic Atrophy and Oculo-motor Palsy: New Growth in the Region of the Pituitary Fossa. Shown at the meeting of the Society on February 10th, 1910.

The patient died May 7th, 1910. There was increase of proptosis and a mass of new growth bulged between the eyeball and the right nasal bone. Other tumours appeared in the left temporal fossa, the roof of the mouth, and the jaw movements were restricted. The right 5th nerve was paralysed and the right cornea sloughed. Headache, delirium, paralysis of the abdominal viscera, and at last coma ushered in death. Post mortem a large tumour was found in the base of the skull beneath the dura. It filled the sella turcica, ethmoid bone, the right middle fossa, and half the left; it projected from the basisphenoid. The cranial nerves and sinuses were stretched by it. The growth was glistening, rather firm, and of even texture. Mr. Shattock (Pathological Curator of the Royal College of Surgeons) reported it to be a rapidly growing chondroma.

At the Annual General Meeting held at the close of the ordinary meeting the officers for the ensuing year nominated by the Council were elected unanimously; the report of the Council was read and the accounts were passed.

A motion to amend the rule of the Society on the eligibility of candidates for membership, so as to permit of the election of foreign ophthalmologists was carried unanimously. N. BISHOP HARMAN.

A CASE OF DELAYED REFORMATION OF THE ANTERIOR CHAMBER AFTER CATARACT EXTRACTION.

By T. Harrison Butler, M.D. (Oxon.),

Honorary Ophthalmic Surgeon to the Coventry and Warwickshire Hospital and to the Warneford, Leamington, and South Warwickshire General Hospital.

Delayed union of the wound after cataract extraction is a rare complication of the operation occurring once or twice on an average in every hundred extractions. The accident is, however, sufficiently serious to merit a close study, for, not infrequently, an operation perfect in itself may have a most unfortunate ending if the reformation of the anterior chamber be delayed more than a day or two.

Before discussing the general aspect of the question I will describe my own case, the only one which I have noticed among my own extractions.

G.M., aged 53, a healthy bricklayer, came to the Coventry and Warwickshire Hospital on January 25th, 1900.

He complained that the sight of his right eye had been failing for twelve months.

P.C. There is a complete cataract on the right side. Projection and light perception normal, no lacrymal affection.

The left lens shewed early haze.

Operation. On June 7th, 1909, patient was admitted and a preliminary iridectomy was performed in accordance with my usual routine. The incision was made with a keratome 1 m.m. behind the corneo-scleral

margin, and the iris withdrawn with Matthias' (Liebreich's) forceps. The operation was followed by considerable injection, but no changes were detected in the iris itself. After a fortnight all injection had disappeared.

On August 27th the lens was extracted. The incision was made accurately in the corneo-scleral margin with a very short conjunctival flap which almost disappeared at the extreme apex of the incision. The capsule was ruptured with v. Graefe's capsulotome and the lens expressed with Pagenstecher's glass expressor. The most stringent aseptic precautions were adopted and a mask and head cap was worn. The operation was absolutely normal, and the patient quite quiet.

During the night patient was alarmed by a noise in the hospital and sat up in bed suddenly.

When the dressing was removed on the third day, August 29th, the wound edges were in apposition and there was no injection. Atropine was instilled and the bandage reapplied. On the 31st the eye was quiet but aqueous was oozing out of the wound and there was no anterior chamber.

On October 4th it was noticed that there was a little tag of iris entangled in the outer lip of the wound, but no prolapse. The bandage was reapplied.

The anterior chamber did not re-form till 17 days after the operation when patient was discharged.

VR. c. $\frac{+10}{+4}$ axis horizontal $= 5/20$.

October 18th. TR. -2, no injection, the anterior chamber has again disappeared.

The tag of iris has retracted from the inner lip of the wound leaving a central fistula.

November 1st. The patient has during the past week had violent pain in his eye which is better now. The

anterior chamber has re-formed. T+1. VR corrected $=5/20$.

November 8th. Tn. There is a small cystic swelling in the site of the original fistula at the outer angle of the wound.

VR. c. $\frac{+10}{+4}$ at 170 $=5/10$. Reads "small pica" with $\frac{+14}{+4}$ at 170.

November 15th. The incision has now healed firmly, but there is a grey patch at its extreme apex.

VR. c. $\frac{+10}{+4}$ at 170 $=5/5$ ptly. Reads "bourgeois."

At this stage I congratulated myself on having escaped the perils of delayed union and subsequent glaucoma, but somewhat prematurely, for on—

December 6th, 1909, patient appeared again, with shallow anterior chamber. The wound is now leaking at its extreme apex where there is a dark spot, obviously a fistula. T. $-1\cdot5$. Vision has sunk to $5/20$ again.

December 20th. The anterior chamber is normal again, but T -1. Patient advised to come in shortly and have the fistula touched with the actual cautery.

February 4th. Patient came up for operation, but it was found that the fistula had healed spontaneously.

February 5th. VR c. $\frac{+10}{+4}$ at 170 $=6/9$. TN. No leakage detected.

May 25th. Seen for last time. Fundus clearly seen, and normal, media clear. T slightly lowered. The old fistula can be seen as a grey spot under the conjunctiva; it is surrounded by an area of definite subconjunctival œdema.

V. c. $\frac{+10}{+4}$ at 170 $=6/6$ all.

Remarks. The wound was probably held open by a tag of capsule which floated in when patient suddenly sat up. Later a piece of iris entered the corner of the incision but the pull of the atropine gradually withdrew it. The wound remained so long open that when it finally closed the conditions of equilibrium between secretion and excretion were suddenly altered, and transient glaucoma resulted. The treatment adopted was rest in bed and firm bandaging.

My last cataract patient had a little vomiting after the operation, caused by the cocaine, a complication I have experienced three times this year.

At the first dressing the wound had not closed, and did not do so until the 4th day, when I was able to see that there was a small entanglement of iris at the inner angle of the wound although there was no prolapse. In this case the act of vomiting had allowed the wound to reopen and slight encleisis prevented due apposition of the edges of the incision and determined late healing. Both these cases shew the value of a conjunctival flap of adequate size.

The whole subject of delayed re-formation of the anterior chamber has been ably treated by the late Professor Widmark of Stockholm in the current volume of the *Mitteilungen aus der Augenklinik der Carolinischen Medico-chirurgischen Instituts zu Stockholm,* 1910.

Widmark has searched through all the recent records of the Seraphim Lazarette and has tabulated the cases of late union among 600 extractions. They number 31. The longest time the wound remained open was 60 days. Eleven of them were combined operations, the others simple. In none of the cases was the vision entirely lost, in most of them it was fair, averaging about 0·3.

The best vision recorded is 0·8, the worst is fingers at 2-3 metres.

It has been suggested that the failure to heal rapidly is due to the action of the cocaine or of cocaine and perchloride lotion combined. Widmark thinks that it is due to error in technique in carrying out the section, and points out that it is commoner after the simple operation because many operators confine their section for this method to the cornea. When the incision is exactly in the corneo-scleral junction, or just in the sclera, the accident is much more infrequent. The reformation of the anterior chamber has only once been delayed over the week in his last 107 extractions, special attention having been given to this point. Widmark does not think that the inclusion of capsule or iris has as much influence as the corneal position of the section. On the other hand it must be borne in mind that many eminent operators recommend a corneal incision. Personally I have not been able to detect any difference in the healing of a corneal or a scleral incision provided that there is no foreign body, iris or capsule between the lips of the wound.

Delayed healing may have several endings. Generally after a longer or shorter time the wound closes and the final result is not influenced adversely. But often the cornea becomes more or less clouded. The opacity may be slight and transient or so dense as to necessitate optical iridectomy. Or the eye may fall a victim to infection and panophthalmitis. It has happened that the wound has never closed, a permanent fistula has remained and the eye has been totally lost. Finally in some cases glaucoma ensues, and more frequently, according to Widmark, after the combined than after the simple operation.

The best treatment is rest in bed combined with a pressure bandage. Lavage with sublimate solution 1–5,000 is often useful, and it may be necessary to use the actual cautery. The best treatment is, however, prophylaxis.

CONGENITAL BLENNORRHŒA OF THE LACRYMAL SAC.

By John Foster, M.B., F.R.C.S. (Ed.),
Ophthalmic Surgeon, Cameron Hospital, West Hartlepool.

The subject of blenorrhœa of the lacrymal sac in the newly born has not received the attention it deserves; it is due to catarrh of the mucous membrane of the sac, which, owing to obstruction somewhere in the nasal duct, most probably where it opens into the inferior meatus of the nose, results in accumulation of muco-pus or pus in the lacrymal passages above the stricture; this leads to distension of the sac, which discharges its contents through the lacrymal puncta, into the conjunctival sac, when pressure is made over the region of the lacrymal sac. In the textbooks little is said about the pathology, and almost less, speaking exactly, about the treatment. Two decidedly different lines of treatment are followed by ophthalmic surgeons. One based largely on the results of the individual experience, the other based in a great measure on the results of embryological findings. The first is the expression treatment, which may be briefly described as consisting of frequent emptyings of the sac by pressing that structure against the lacrymal bone, coupled with the employment of zinc chloride or other astringent drops to the conjunctiva afterwards; the second method consists in slitting up the

canaliculus and passing a probe down the nasal duct into the inferior meatus of the nose.

During the last two years I have met two cases of blennorrhœa of the lacrymal sac in newly born babies so placed socially that it was possible to have the expression treatment carried out properly, and to keep the cases under careful observation. The results have tended to strengthen the view I had previously held that given the circumstances, which are generally to be found in a good home, the expression treatment is, ordinarily speaking, quite sufficient to cure absolutely the great majority of these cases.

As regards the literature on the subject, a careful search unearthed only two papers, the first by Mr. Donald Gunn, published in the *Ophthalmic Review*, February 1900; the second and more recent by Mr. Stephen Mayou in the Reports of Moorfields Hospital, 1908. Mr. Gunn, whose article is entitled "Lacrymal Obstruction in the Young," publishes an account of seven cases of this condition, in which, if I read him aright, he ascribes the condition to obstruction of the lower end of the nasal duct, where it opens into the inferior meatus of the nose, and the consequent distension of the passages by the accumulation of epithelial waste, which should have been removed in due course, if no such obstruction had existed; the dilatation of the passage he surmised from the quantity of pus and proved actually by the use of the probe. Mr. Mayou does not quite agree with this view, as he considers that the discharge accumulates in the sac itself, which is capable of much distension into the orbit without producing much outward and visible sign. In six of the cases seen by Mr. Gunn he slit the canaliculus and passed the probe; he found the dilatation of the nasal duct with

obstruction at the lower end in all the cases; they were promptly cured by the operation; the expression treatment was not systematically tried.

Mr. Mayou's conclusions, the result of sectional examination of the head of several fœtuses are as follows:—

(*a*) That throughout development the lower end of the lacrymal duct is extremely small, and remains so at birth, being partially occluded by the inferior turbinate bone.

(*b*) That the duct is filled with débris, as well as the sac and the canaliculi.

(*c*) That at birth the duct is either not patent or only partially so.

Mr. Mayou is apparently a believer in the passage of the probe.

My own cases in brief:—

Case I. Margaret —, aged 3 weeks, daughter of a medical man had had several attacks of muco-purulent conjunctivitis, with a watery eye, even in the intervals of freedom from the conjunctivitis; repeated expression of sac failed to elicit any discharge from the puncta; still, however, the expression was practised intermittently, *i.e.*, when the attacks of conjunctivitis appeared and were under treatment. Zinc chloride and boric lotions were used for several months and Ag No_3 (gr. ii ad ℥i) painted on the everted conjunctiva, when thought necessary. When the child was about 5 months old all symptoms disappeared; the child left this town when she was 18 months old, but there were no further symptoms of the trouble.

Case II. George —, the son of another medical colleague, was 10 days old, this case a typical case with

much muco-purulent discharge, this being readily expressed from the puncta; frequent expression was instituted, the mother taking upon herself the duty, and so well was the procedure carried out that the child never developed any conjunctivitis worthy of the name; zinc chloride and boric acid drops—with occasional changes to alum drops, which were not so suitable, protargol 1 per cent. was used at times when the discharge threatened to become more purulent in character. This child was quite well at the age of 16 months, the obstruction disappearing along with the cessation of matter on expression of sac.

The first case was a mild one, but nevertheless a true case. Singularly enough the baby's brother had the same condition on the same side, at birth; this child had no pus from the puncta, whilst he remained under my care, nothing but the attacks, which were mild, of muco-purulent conjunctivitis with wateriness. During one of the intervals of freedom from conjunctivitis he was taken south by his mother, there he developed a typical marked blennorrhœa of the sac, so much so that a surgeon who was consulted advised and performed the slitting of the canaliculus and passage of the probe.

MYOPIA DEVELOPING AT 26 YEARS OF AGE.

By Campbell Munro, Barrackpore, India.

The following case of myopia, developing at the unusually late age of 26, may be of interest.

Patient came to me on 19th March, 1910, complaining of headaches and deterioration of distant vision, during the last few months. He was a well-developed man, living an out-of-doors life—he was a Sowar in a native cavalry regiment; age, about 26. Until recently, he

was an expert signaller, passing "First Class" in the 1908 and 1909 regulation tests, a feat, for the accomplishment of which, extremely good distant vision is required. During the last six months he has had increasing difficulty in seeing the signalling flags, and, in his 1910 test, he failed completely.

On examination, V.A. in both eyes was found to be $^{6}/_{18}$. The fundi were normal in appearance. By retinoscopy, 3D and 2·75D of myopia were made out in the right and left eyes respectively, combined, in each case, with −·5D astigmatism 'against the rule.' The necessary correcting glasses improved the V.A. to $^{6}/_{6}$ in both eyes.

The case is of interest in that the error of refraction (as nearly as possible equal in the two eyes) developed in *adult* life, this fact being vouched for, not merely by the patient's statement, but by a strict sight test, applied before and after the condition occurred.

REVIEWS.

TROUSSEAU, A. **Imperceptible Incurvation of the Flap as a Cause of Non-reestablishment of the Anterior Chamber after Cataract Operation.** *Archives d'Ophtalmologie.* April, 1910.

IN this communication Trousseau does not give any detail of his method of operating, and from the frequency with which he appears to have met with this complication it would seem that he does not make much use of a conjunctival flap.

He states that in his opinion delayed cicatrisation of the wound is invariably due either to the presence of some foreign material between the lips of the wound or else to a minute folding over of the edge of the flap. The latter complication is indicated by a delicate groove only to be seen with the aid of the corneal microscope. In one case quoted by him the anterior chamber had remained open for a month after the operation, but closed firmly three days after the incurved

portion had been replaced with the edge of the cataract knife. That this fortunate result was not necessarily due to the freshening of the edges of the flap is in his opinion proved by another case in which replacement of the flap by the repositor sufficed to permanently close the wound.

He lays stress on the necessity for examination of the wound with the aid of the corneal microscope in all cases of delayed union, as the fragment of the iris or capsule as well as this slight incurvation of the edge may be quite too minute for detection in the ordinary way.

E. E. H.

A. N. Natanson. **Two Cases of Solitary Tubercle of the Posterior Segment of the Eyeball in Early Childhood.** *Klinische Monatsblätter für Augenheilkunde*, Feb., 1910.

Natanson has had the opportunity of examining, both clinically and pathologically, two cases of tuberculosis of the posterior segment of the eyeball, which raise some interesting questions regarding the differential diagnosis of the affection from glioma and pseudo-glioma.

The first patient was a boy two years of age whose mother had observed a yellow colour shining from the pupil of his left eye. The eye was blind, tension was elevated and there was swelling of the pre-auricular gland. Glioma of the retina was diagnosed and the eye was enucleated. At the operation it was noticed that the optic nerve was thickened, and Natanson removed the remainder of the nerve as far back as possible. The patient was lost sight of after leaving hospital. Examination of the eye revealed a flat tumour occupying the disc and the choroid adjacent to it as far as the equator. A small mass was also found detached from the main tumour in the anterior part of the choroid. The optic nerve and its sheaths were thickened. The tumour presented all the microscopic evidences of tubercle. It had extended beyond the lamina cribrosa into the optic nerve and its sheaths as far back as these could be excised. It had also invaded the sclera and perforated into the retrobulbar tissues. The retina was uninvaded.

The second patient was also a boy two years of age. When first seen the eye was quiet and the tension normal. There was a yellow reflex from the pupil and the iris presented some posterior synechiæ. The eye was blind. Glioma was considered probable and enucleation was advised, but the mother

did not permit it. Two months later the child was brought again with swelling of the lids, proptosis and enlargement of the eyeball, bulbar injection, dimness of the cornea, discolouration of the iris and occlusion of the pupil by exudate. On the temporal side a small elevation was seen on the surface of the gobe presenting a perforation which admitted a probe into the interior of the eye. A diagnosis of tubercle was made and the eyeball removed.

The whole eyeball was found to be filled with a tuberculous and caseating mass. The optic nerve was not involved behind the lamina cribrosa, neither was there any tubercle of the iris, but the retina, choroid, and ciliary body were completely obliterated by it.

The first case was peculiar in the absence of the clinical signs distinctive of tubercle, and in the extensive thickening of the optic nerve which before microscopic examination rather strengthened the diagnosis of glioma. The author does not venture to say whether the disease commenced in the choroid or in the optic nerve. In most published cases of tubercle of the choroid the nerve has not been invaded behind the lamina cribrosa, while in cases of tubercle of the nerve the choroid has not been so extensively affected. This case shows that while signs of inflammation and normal or diminished tension are characteristic of tuberculosis as against glioma, yet tubercle may be present without inflammatory signs and with elevated tension.

Both of the cases occurred at an age at which glioma is liable to appear, which rather weakens the age factor as a guide in differential diagnosis. On the other hand these cases lend support to the already accepted distinction that glioma and sarcoma only perforate at a somewhat late stage when the glaucomatous state has arrived, and tend to grow rapidly after perforation, while tuberculosis perforates early without elevation of tension, and the extrabulbar growth is slow.

The author concludes that inflammatory symptoms and early perforation are the most reliable signs of tuberculosis although his cases show how difficult the diagnosis may be. He thinks that removal of the eye is the only satisfactory form of treatment when vision has already been lost. The optic nerve should be cut off as far back as possible, and if perforation of the globe has already occurred, or the retrobulbar part of the nerve has become widely involved, exenteration of the orbit should be resorted to.

The author points out that the literature of tubercle of the optic nerve and retina was summarised by Verderamme up to the year 1908 (Klinische Monatsblätter) and that of tubercle of the choroid to the year 1903 by Zur Nedden (Klinische Monatsblätter). Since 1903 he has found records of twelve cases of tubercle of the choroid.

A. J. Ballantyne.

S. Golovine. **A type of Orbital Inflammation not hitherto described.** *Annales d'Oculistique.* March, 1910.

The case described by Golovine under the above heading is of great interest.

As the author points out, there are several cases in the literature which are somewhat similar to the one now published, but the present record is unique inasmuch as the patient was under observation for so long a time as six years and was moreover submitted to an exploratory operation which afforded material for a pathological examination.

The following is a brief account of the clinical features of the case. The case itself is described at great length and should be consulted in the original by those interested.

The patient, a male, aged 30, and of Jewish extraction, was first seen in November, 1903.

On examination marked signs of inflammatory œdema were noticed. The œdema extended, on the left side, from the supercilliary ridge above to the zygoma below. The eyelids were swollen and red; the palpebral fissure was narrowed. The movements of the left eye were limited in all directions but chiefly laterally, and the eyeball itself was proptosed. The left fundus was normal except for a slight dilatation of the retinal veins. Lt. T. n. V. = 0·7. The patient complained of pain over the left half of the head and at the back of the left eye. Palpation of the orbit failed to disclose any signs of a tumour. The right eye at this time was normal.

The patient's general health was satisfactory and repeated examinations failed to discover any abnormality in the patient's nervous system. There was no evidence of syphilis. From the history given by the patient it would seem that the disease commenced early in the year 1900 when he experienced a sharp attack of pain in the left eye which was at the same time slightly injected. This attack lasted for two days. One week later the patient suffered another attack which lasted for eight days.

Many similar attacks were afterwards experienced. At a

later stage proptosis of the left eye was noticed. After such an attack the œdema and hyperæmia disappeared; a slight degree of proptosis, however, remained. In the autumn of 1901 this latter feature was changed and the proptosis showed no decrease between the attacks. At first only the left eye was affected, but later the right eye was the subject of similar attacks.

The attacks were sudden and irregular, but those on the left were more severe than those on the right, whilst their duration varied from a few days to two weeks.

After August, 1903, the right eye was proptosed from time to time.

Before consulting Prof. Golovine the patient had applied for relief to many medical men whose treatment ranged from anti-syphilitic remedies to electrical treatment and hot baths. Their diagnoses seem to have been almost as varied as their remedies.

Golovine himself at first suspected frontal sinus disease but soon discarded this diagnosis. A further course of treatment by potassium iodide failing to give relief, an orbital exploration was decided on. The method adopted was that described by Golovine in the Dec., 1909, No. of *Annales d'Oculistique* and noticed in the *Ophthalmic Review* for May, 1910, on pages 148 and 149.

The operation disclosed a mass, whitish in colour, and about the size of a hazel nut, placed on the inferior wall of the orbit to which it was feebly adherent. Several fibrous bands traversed the orbit in various directions binding the mass to the muscles; one of these bands in particular was observed to blend with the sheath of the optic nerve. The mass was removed and submitted to the microscope. The report of this examination stated that the mass was composed of proliferated conjunctival tissue which had undergone some inflammatory process the nature of which could not be ascertained. There was nothing to suggest a gummatous nature nor could any micro-organisms be found.

In the course of the year following this operation the attacks were not so severe or so frequent. This relief was temporary and the only permanent result was that the proptosis of the left eye was never so marked after the operation as it had been before.

In 1908 the patient for the first time showed signs of general weakness and exhaustion due, no doubt, to constant pain. As

a complication the patient was treated about this time for a corneal ulcer of the left eye.

A blood count showed a slight increase in the number of leucocytes not amounting, however, to a leucocytosis. The urine contained slight traces of albumen.

In February, 1909, the movements of the left eye were very restricted and the patient was treated for a hypopyon ulcer which had developed at the lower part of the left cornea. The condition of the right remained as before, viz.: slight œdema of the lids, slight proptosis, and movements very limited.

The inflammatory attacks became more frequent and longer in their duration whilst the intervals were shorter, and both eyes were affected simultaneously instead of alternately.

It was noted that, in spite of the œdema, the orbito-palpebral furrow was drawn back so as to be deeper than normal, and giving the impression that it was pulled back by some attachment at the back of the orbit.

In 1908 the patient, whose general health had been getting much worse, was admitted to hospital and treated for an attack of colitis. During this stay in hospital it was noted that the orbital attacks coincided with a slight rise in temperature and an increase in the number of stools, which latter were accompanied by much mucus. The urine contained a trace of albumen besides blood pigment and granular casts. For the first time œdema of the left leg and pain along the course of the nerves was noticed, both disappearing as the orbital condition improved.

With the discharge of the patient from the hospital the record ends.

Golovine devotes many pages to an exhaustive review of similar cases reported in the literature and to a discussion as to the origin of the disease. In many respects the case resembles one of angio-neurotic œdema, but yet it differs from such a case in certain essentials, since it is not usual in angio-neurotic œdema to have permanent changes, nor is the œdema accompanied by inflammatory signs.

Golovine is inclined to consider that the attacks from which his patient suffered were allied to erysipelas but points out that no definite conclusion can be come to on one case.

The original is illustrated with many photographs showing the course of the disease and with a photo-micrograph of the mass removed by operation.

Reginald A. Morrell.

Majewski (Cracow). **Scotoma Helioplegic.** *Revue Générale d'Ophtalmologie.* February, 1910.

The author proposes the name scotoma helioplegic for such cases as his own and Zirm's, where the uneclipsed sun is gazed at, as distinguished from scotoma heliecliptic.

The first half of this paper deals with the clinical features of eclipse cases and briefly with the experimental work done by various observers in exposing rabbits eyes to sunlight or to the voltaic arc-lamp. Lescarret excluded the influence of the heat and of the actinic rays by using solutions of alum and of quinine sulphate respectively, and he concluded that the lesions produced—which were mostly quite insignificant—were due to the visible part of the solar spectrum. Hence the name—phototrauma.

The most conspicuous thing in eclipse cases is not any conjunctival or corneal irritation as in electric ophthalmia, —for these signs are usually very trifling and fleeting,—but the central scotoma, which when absolute may reduce the vision to one-third or even one-fourth of normal. The scotoma, often a flickering one, is usually absolute but may become relative, although its size remains unaltered. The size corresponds to the retinal image of the sun's disc and, measured at the distance of the punctum proximum, rarely exceeds 2 mm. in diameter.

A short note is given of Zirm's case, recorded in the *Archiv f. Ophth.*, vol. lx, 1905, pp. 401–4. This was a young lad who without protecting glasses gazed for some minutes at the uneclipsed sun. He had great diminution of vision and an absolute scotoma in each. The fundi—examined by Zirm fully six months after the exposure—showed a large ovoid patch of red, dotted over with pigment granules, at each fovea. These changes Zirm believed to be the result of hæmorrhages. A coloured drawing of each fundus is given in the paper. Visual acuity—reduced to one-twentieth—was raised after subconjunctival injections of cyanide of mercury with acoin to one-twelfth—where it remained. The boy, who is stated to have been weak-minded, noted improvement in the vision the day after his first subconjunctival injection!

The second half of the article deals chiefly with a case which Majewski had under his care for some time. It was that of a boy of 11 who, in July, 1908, gazed at the uneclipsed sun not only without protecting glasses but with the help of a strong theatre lorgnette, which gave an apparent enlargement of objects of double their size. It was the eve of the school

holidays and the boy said nothing about the defect of reading vision which he noticed the day after the exposure, so that it was two months later, September, 1908, when, on his returning to school, the boy's inability to read and write was noted, that he came under observation. The boy had gazed at the sun for probably only a very few seconds and seemed to have had a slight momentary pain and then to have at once noted a thick fog obscuring his sight. He had had little or no conjunctival or corneal irritation. In September the external ocular appearances were normal. Ophthalmoscopic examination showed clear media and an absence of fundus lesions except for a slight deepening of red at each fovea. Vision was finger-counting at 1½ metres: the largest Snellen types could not be read. The fields were full on the perimeter, but an absolute central scotoma for white and colours was found in each. No other change—subjective or objective—was found about the eyes.

His general health was good; urine free from sugar and albumin. He had only had measles—no other illness. The father was not syphilitic but the mother had had three abortions, ascribed to accidental causes; four infants died of various ailments and the six living children were very healthy. Nothing was found in the history to negative the suggestion that the boy's trouble was due to the exposure to the sun's rays.

A collyrium of 5 per cent. dionin was ordered, sweatings were induced and complete rest in the dark was enjoined and at the end of eight days, whether post-hoc or propter-hoc, the boy could count fingers with each eye at 5 metres and could read Sneller D. = 3,0. The fundi and scotomata were as before.

The author, on the assumption that there was some retinal œdema, gave some iodone (Robin), ten to fifteen drops, thrice daily to aid absorption. After another eight days the boy read with his right eye Snellen 2,25 and with his left eye 1,75. Distant vision as before. This was on Sept. 21, 1908. Since then repeated examination had been made but no further improvement had been obtained.

The best that could be hoped for in such a grave case was the development of "vicarious foveæ," the paracentral retina taking up the function.

The boy retained the absolute scotoma in each, and within this grey area objects were tantalisingly invisible. He was able to draw his scotoma on paper and, at a distance of 15 mm. (this we suppose is a misprint for 15 cm., as at this distance

a scotoma of size described in text would be about twice that of the normal apparent size of the sun), he made for his right eye a nearly circular area of 5 mm. diameter, and one of 4 mm. for his left. These dimensions are greater than usual because of the optical action of the lorgnette. Within the scotoma he could scarcely read Snellen 1,75 without rapid lateral movements so that it is doubtful whether this was actually read by the part of the retina corresponding to the scotoma.

In December, 1908, no fresh lesion was discovered. Foveæ as before; retina, choroid and optic discs showed no visible change. This absence of ophthalmoscopic change seemed to support the experimental researches of Lescarret, whereas Czerny, Widmark and Deutschmann always got atrophic spots, hæmorrhages, migration of pigment and other gross changes in their experiments.

Aubaret reproaches these latter observers for not having eliminated the heat and actinic rays (which, he adds, do not play an altogether negligible part in the true scotoma heliecliptic cases), and he agrees with Lescarret that the visible part of the solar spectrum is almost exclusively responsible for the damage to the percipient retinal elements. He further asks if all the varied fundus changes that have been attributed to the sun's rays by such as Menacho, Sulzer, Fromaget, and Villard (and may one add Zirm) can honestly be classed along with the scotoma heliecliptic. Majewski considers that his case supports Aubaret's view, for in spite of a very severe phototrauma, the anatomical lesions or at least the ophthalmoscopic signs were for long imperceptible. Even in his case, however, changes occurred later on for in April, 1909, the boy was seen by Professor Wicherkiewicz at Cracow, who found an atrophic excavation of each papilla, the optic discs were slightly pale, and a little too well defined. The boy was given subconjunctival injections of NaCl (2–5 per cent.) and at the end of a month vision had gone up in each eye to 0,1. The vision remained, after the last improvement, the same for two months and Majewski presumes that the atrophic process has been arrested.

It is regrettable that the later records of the vision are incomplete and that the author did not himself have an opportunity of seeing the case subsequent to the apparent onset of the optic atrophy. One must not lay too much stress upon the value of the therapeutic measures employed.

In future it will be well to submit all such eclipse cases to the Wasserman reaction. W. C. Souter.

ELSCHNIG (Prague). **Researches on Sympathetic Ophthalmia.** *v. Graefe's Archiv für Ophthalmologie*, 75., 3.

I. EFFECT OF ANTIGEN WITHIN THE EYE.

THIS is the first paper of a series dealing with the interaction of antibodies between the eye interior and the blood-serum: Elschnig has undertaken these researches in order to attack the subject of sympathetic ophthalmia from a comparatively fresh aspect; histology and attempts at cultivation have been fully studied. The present paper gives the results of examination of the blood serum after introduction of certain substances within the eyes of rabbits.

An account of previous experiments in the literature notes a general immunity produced by conjunctival and corneal inoculations, but such may be obtained by absorption from any mucous surface. Leber has found an increase in the agglutinating power of the blood after introduction of dead cholera vibrios into the anterior chamber, but his experiments are not considered sufficiently exact.

In the present experiments animal blood and substances prepared from cholera vibrios have been used: these were injected into the anterior chamber and into the vitreous: care was taken against any leakage from the inoculation hole so as to prevent absorption from the conjunctiva. For introduction into the vitreous, it was found that the best method was to pass the needle perpendicularly through the cornea, permit escape of aqueous, and then transfix the lens. In this way injury to the coats of the globe and hæmorrhage were avoided, and there was no danger of leakage. If much inflammation ensued, the results were neglected.

1. *Blood Injections.* (*a*) Sheep's blood. A few injections were made into the anterior chamber, but the serum reaction was found to be very high: the experiments showed considerable increase in antibody, but not so high as after intraperitoneal injection.

(*b*) Ox blood. After one injection into the anterior chamber the hæmolytic value was increased, and a second into the same or opposite eye was followed by another rise: but with a peritoneal injection a greater effect followed. Induction of inflammatory reaction appeared to affect the result but slightly.

(*c*) Ox blood in the vitreous. The first injection produced a rise in antibody, but in nearly all cases bombé iris followed:

this was treated by transfixion, and later a second and even a third injection was given: the bombé iris reappeared, and ectasia usually resulted. In all cases the second injection produced no rise or even a fall in hæmolytic value, and the third at most produced a small rise. Intraperitoneal injection gave a slightly higher value than after the first, but a much higher one than after the second vitreous injection. One may infer that resorption of antigen from the vitreous takes place via the anterior chamber, thus explaining the diminution in hæmolysis when the anterior and posterior chambers are shut off from each other.

2. *Antigen Value of Cholera Substances in the Eye.* (*a*) Cholera extract. (1) In anterior chamber. The first injection gave a slight increase in agglutinins in the serum, but not so marked as after subcutaneous injection: a second injection produced an enormous reaction. The injections gave rise to only a transient inflammation. (2) In the vitreous. The results here were much the same, the rise after the second injection being very great.

(*b*) Cholera emulsion. Numerous experiments gave similar results to those in (*a*). The rise after the second injection into the anterior chamber occurred equally whether the injections were both into the same eye or into the two eyes alternately. The second intravitreous injection gave a very great increase. The addition of 5 per cent. NaCl solution to the injection increased the first effect, but affected the second injection scarcely at all. Subconjunctival injection of 5 per cent. NaCl after the anterior chamber injection also intensified the result, but this appeared to vary considerably in different animals.

Elschnig considers that the experiments point to the antibody being a non-local product. His conclusions are:—(1) That introduction of antigen into the eye produces a smaller effect on the serum than subcutaneous injection and a much smaller one than intraperitoneal or intravenous injection; (2) that the reaction is greater if the animal has already been immunised against the substance introduced; (3) that severe inflammation of the globe weakens the effect but does not abolish it, except in the case of vitreous injection with resulting seclusio pupillæ.

F. A. Juler.

WEIGELIN (Stuttgart). **Diagnosis of Sympathetic Ophthalmia from a Pathologico-Anatomical Standpoint.** *v. Graefe's Archiv für Ophthalmologie*, 75, 3.

BACTERIOLOGICAL examination of cases of sympathetic ophthalmia has failed to give any positive result, although sympathetic uveitis is universally regarded as bacterial in origin, especially on the ground of the anatomical findings in the exciting and sympathised eyes.

Sympathetic inflammation is a chronic uveitis in which all parts of the uvea present foci of round cells together with a rich fibrinous exudate on the surface of the iris and ciliary body. A great advance was made when Fuchs discovered that the condition could be distinguished by a characteristic lesion which is now familiar to all ophthalmic surgeons. In sympathetic inflammation these foci consist of lymphocytes, endothelial cells, and giant cells, and they are scattered throughout the uvea. When a fibrinous exudate is present there has probably been a mixed infection. This point however has been disputed. Further it has been questioned whether the diagnosis of sympathetic inflammation can be decided on purely anatomical grounds.

It was to elucidate this matter that Dr. Weigelin undertook his researches on the material at the Tübingen clinic. The eyes investigated by him were derived from the collection of the University eye clinic of Tübingen from 1881 to 1909. This collection consisted of eyes which had given rise to sympathetic ophthalmia, doubtful cases of the same, and also eyes which had become affected secondary to the exciting eye. As a control a large number of eyes, which had been removed for traumatic irido-cyclitis, were examined. All eyes, which had been removed earlier than fourteen days after the injury, were excluded because sympathetic ophthalmia has not been observed earlier than this. The total number of eyes examined were 41. They were grouped clinically as follows:—

Undoubted sympathetic inflammation in the exciting eye	17
Doubtful sympathetic inflammation in the exciting eye	8
Eyes causing sympathetic irritation in the other eye	4
Secondarily affected eyes	2
Eyes with traumatic irido-cyclitis	10

He revised this group according to the anatomical investigations, thus:—

Sympathetic inflammation in the exciting eyes ...	21
Sympathetic irritation	4
Sympathetic inflammation in the second eye... ...	2
Traumatic irido-cyclitis	14

Before going on to the details of these cases Dr. Weigelin goes into the question of the frequency of the occurrence of sympathetic inflammation. Fuchs, from a collection of 181 eyes removed later than 14 days after injury, found the typical lesion in 24 cases or 13 per cent. Dr. Weigelin from a larger collection came to the conclusion that it should be about 8 per cent. Literature on the subject is scanty. Schirmer found 3 cases amongst 157 infected wounded eyes or 2 per cent. Kitamura amongst 577 cases of perforating wounds found 17 cases or 2·94 per cent.

Dr. Weigelin has collected a large number of recorded cases of perforating wounds of the globe. He has excluded the cases of sympathetic ophthalmia following after operations and perforating ulcers, and he finds the percentage even lower. The total number of cases collected together by him were 1150, and it is interesting to note the classification of these injuries which were as follows:—

Perforating corneal wounds	465
Shot wounds	91
Ruptures and wounds of the sclera ...	248
Traumatic cataract	155
Foreign body in globe	191

Amongst these cases there were only 12 in which sympathetic inflammation occurred or 1 per cent. As he says, the percentage would be higher if we knew what number were capable of giving rise to sympathetic inflammation, and those eyes which through early removal prevented its occurrence. Only one conclusion however can be drawn and that is that sympathetic inflammation belongs to the rarer diseases.

The eyes were hardened in Zenker's fluid and cut in celloidin. He arranged the material into the following groups:—

Group I. Sympathetically inflamed eyes with doubtful sympathetic inflammation in the other eye. Fuch's characteristic lesion had to be present in these.

Group II. Eyes with traumatic chronic iridocyclitis in which the other eye was certainly not affected by sympathetic inflammation. The question arose as to whether in these eyes the same or similar anatomical changes are to be found as in sympathetically inflamed eyes. In this group were also included cases where sympathetic irritation existed in the other eye.

Group III. Cases of doubtful sympathetic inflammation.

Group IV. Secondarily affected eyes. These were cases of pure sympathetic inflammation.

These groups are considered in detail.

Group I. In this there were 17 cases. These are given in tabular form setting out the essential details of each case. They were due to perforating wounds, perforating ulcers, and post-operative. The shortest interval between injury and outbreak of sympathetic inflammation was 24 days and the longest 15 years. There was a chronic uveitis in them all. He subdivided them into three classes according to the severity and distribution of the inflammation.

Class 1. Cases with high degree of inflammation in all parts of the uvea, especially the choroid, in which the diagnosis could be already made by the help of a lens.

Class 2. Cases of moderate severity in which part of the uvea differed markedly and was not affected in the whole extent.

Class 3. Cases of slight changes in which also part of the uvea was unaffected.

The typical foci were found distributed about in the uvea in accordance with this, and excellent microphotographs are given to illustrate the cases. For details I must refer the reader to the original as they are far too lengthy to extract. Though the foci resemble tubercles yet caseation had never taken place in any of them. In the severe cases exudation played an important part in the forepart of the uvea but was not found on the surface of the choroid. In the less severe cases the choroid was but slightly involved, the iris and ciliary body being more affected. This may in some cases have been due to early excision before the inflammation had extended backwards. The foci consisted of masses of lymphocytes in the midst of which were epithelioid cells. Giant cells were present in 5 cases.

The way in which the three parts of the uvea were involved may be stated as follows for the 15 cases:—

Portion of uvea.	Silghtly involved.	Moderate.	Severe.
Iris	4 ...	8 ...	4
Ciliary body	4 ...	9 ...	3
Choroid	4 ...	6 ...	6

Typical foci were found in every portion though not always in them all at the same time. The retina was never involved and only very slight changes were found in the optic nerves.

Group II. This consisted of eyes affected by chronic iridocyclitis in which certainly no sympathetic ophthalmia existed. Eyes representing various periods after injury were examined so as to obtain the pathological picture of the condition in all its stages. In this group were included those eyes which had given rise to sympathetic irritation which had cleared up after excision. In all there were 14 eyes. Details are given in tabular form. No epithelioid or giant cells were found so that Fuch's typical foci were entirely absent. Only in a few cases was the choroid involved. Even in the eyes which had given rise to the sympathetic irritation no typical foci could be discovered. The inflammatory signs therefore in this group were quite different to those in Group I where sympathetic inflammation was definitely established. Doubt in the diagnosis then could only exist when merely slight changes had taken place in the uvea of the sympathetically inflamed eye, or when there existed in traumatic cases round cell infiltration in some parts of the uvea. Dr. Weigelin believes that cases falling under one of these two first groups can always be distinguished from one another if they are only examined with sufficient care microscopically.

Group III. This consisted of the cases of doubtful sympathetic inflammation in the other eye. Dr. Weigelin says it would be of interest to be able to apply the practical knowledge obtained in the examination of the former two groups to affirm or deny the diagnosis of sympathetic inflammation in these cases. Eight cases are dealt with in this group. Histological investigation was in favour of four cases being genuine sympathetic inflammation—three were certainly so, for in each the choroid presented the typical foci in two of which giant cells were present. Of the four cases which were not sympathetic inflammation according to the microscope, two were certainly doubtful from the clinical standpoint. One of the remaining two cases had certainly appeared to be sympathetic inflamma-

tion clinically but there were no signs of recent inflammation, let alone the typical foci. But considerable degeneration had taken place in the eye, so that this together with the possibility that the foci might have healed, as the inflammation had occurred a long time ago, must leave this case in doubt. The anatomical investigation of these eyes with questionable sympathetic inflammation could then with one exception decide the question for or against the diagnosis of sympathetic ophthalmia. The importance of this cannot be overstated. In this way can we clear up the relationship between inflammation in an eye where there is doubt as to the injury being a cause, even if it occurred years before.

Group IV. Under this group secondarily affected eyes were considered. Only two cases were forthcoming for this investigation and a detailed description of each one is given.

Case 1. Sympathetic inflammation after cataract extraction which affected both eyes. The secondarily affected eye was excised. In a mass of exudation there was a focus consisting of mononucleated leucocytes and epithelioid cells with some giant cells. Foci also occurred in the ciliary body and the choroid, but giant cells were absent in these. There is an excellent microphotograph of this case.

Case 2. Perforation of the cornea due to suppurative keratitis. Excision was advised but refused at first. The eye was removed 6 months later. Onset of inflammation took place in the other eye 14 days later and presented the form of a serous iritis. A diagnosis of sympathetic inflammation was made. The second eye was removed two years afterwards. Histologically it showed masses of lymphocytes in the iris and choroid but no typical sympathetic foci. Secondary glaucoma had taken place and there was a deep cupping of the optic nerve head.

In the first case there was no doubt as to the diagnosis of sympathetic inflammation for typical lesions existed throughout the uvea. There was also considerable exudate. On this account Fuch's view that the presence of plastic exudation is an accidental complication will probably have to be given up, for other cases have been reported. The idea that it is due to a mixed infection must fall through in this case. We conclude therefore that in severe cases of sympathetic inflammation it may arise from that alone. With regard to the second case Dr. Weigelin considers there was no doubt also

that it was one of sympathetic inflammation, the eye was destroyed by secondary glaucoma. As the eye was excised two and a half years after the sympathetic inflammation, which was certain clinically, he concludes that the inflammation had subsided. There was slight round-celled infiltration in the ciliary body and the choroid.

Dr. Weigelin finally considers a comparison of sympathetic inflammation with spontaneous chronic irido-cyclitis. Fuchs has stated that chronic irido-cyclitis could furnish a histological picture which could not be distinguished with certainty from that of sympathetic inflammation. Two such cases have been published by Botteri from the clinic at Vienna. Kitamura has described a case of a blind eye with similar histological appearances where there had certainly been no perforating wound. Dr. Weigelin examined two eyes in which the diagnosis of metastatic irido-choroiditis was established. These showed the exact picture of a traumatic irido-cyclitis with preponderance of the exudation on the surface and pronounced suppuration. In one case lymphocytes predominated in the tissue. A similarity to sympathetic inflammation could not be established.

Cases of chronic tubercular uveitis provide a very similar picture to that of sympathetic inflammation. The great point of difference is that in the latter caseation never takes place in the foci. However Dr. Weigelin records a case of tuberculous uveitis where the diagnosis was established beyond doubt both bacteriologically and by means of inoculation experiments and where caseation had not taken place in the foci. Another of his cases recorded, one of sympathetic inflammation, shows in an excellent micro-photograph considerable likeness to tubercle. He closes this section of his paper by describing in detail a case of severe uveitis arising spontaneously in which the resemblance to sympathetic inflammation was very striking. There was a doubtful history of syphilis and the Wassermann reaction was negative. Further there was no evidence whatever of tubercle either from the history or bacteriological examination. Typical foci of sympathetic inflammation were present throughout the uvea, without any signs of caseation. From this case Dr. Weigelin says there is greater support in favour of the fact that spontaneous chronic irido-cyclitis can also give rise to a histological picture similar to that of sympathetic inflammation.

Conclusion. The results of the research are as follows:—

(1) In all cases of genuine sympathetic ophthalmia there was

found in the exciting eye the characteristic typical inflammation described by Fuchs.

(2) In all cases of ordinary traumatic irido-cyclitis with and without sympathetic irritation in which the second eye was certainly not diseased, there was a varying anatomical picture that only sometimes exhibited in detail a distant resemblance to the picture of sympathetic inflammation.

(3) In cases of doubtful sympathetic ophthalmia the anatomical investigation was able to decide the question. Only in one case was a certain decision not possible on account of a high degree of degeneration in the eye investigated.

(4) The investigation of two secondarily affected eyes showed the same histological changes to be present as in the exciting eyes. One of these showed clinically the rare picture of sympathetic serous uveitis.

(5) In a case of spontaneous chronic irido-cyclitis affecting both eyes there was present in the eye first attacked the typical picture of a sympathetic inflammation.

As a result of these investigations Dr. Weigelin is in entire agreement with Fuchs that sympathetic inflammation has a characteristic histological appearance and can be distinguished from traumatic irido-cyclitis. Cases will now and again turn up where it will not be possible to make an absolutely definite diagnosis from the microscopic changes. This will especially be so in some cases of chronic irido-cyclitis of spontaneous origin.

In cases where the disease has arisen years after the injury he agrees with Heerfordt in supposing that the causal agent of sympathetic inflammation has remained latent in the eye. In these cases fresh foci of inflammation could always be found. He refers to Meller's work on "intraocular sarcoma and sympathising inflammation" (For review see *Ophth. Review*, Feb., 1910, p. 40). Dr. Weigelin says that as it has been shown that a similar histological picture to that of sympathetic inflammation may occur in cases of chronic irido-cyclitis of spontaneous origin, so such foci in cases recorded by Meller do not necessarily prove that the disease was genuine sympathetic inflammation. For the histological picture to prove the presence of sympathetic disease he maintains that a perforation of the globe must have occurred. In the cases of intraocular sarcoma he believes a chronic irido-cyclitis had arisen giving rise to the same picture as sympathetic disease. Dr. Weigelin also agrees

with Fuchs that on account of the anatomical relations of the blood-vessels to the inflammation the transference is a metastasis via the blood-vessels. BEATSON HIRD.

HALBEN, R. (Greifswald). **Myopia as a Pressure-deformity and the Laws of Growth of the Eye.** *v. Graefe's Archiv für Ophthalmologie*, 71., 2.

THIS paper is the outcome of an enquiry into the mechanical factors at work in the eyeball during the process of growth, and is a continuation of a previous publication in which Halben, in considering the mechanical causes of the lengthening of the eye in myopia, showed that the stretching of the sclerotic, which an increase in the intraocular pressure by the external ocular muscles effects, is practically entirely confined to the posterior half of the eye and that there is no need to assume any difference in resistive power between the anterior and posterior parts of the sclerotic. The growth of the sclerotic generally is dependent on the action of certain forces of which the intraocular pressure is the only one that exerts itself on the inner surface of this coat. The effect of this pressure must be to stretch the sclerotic, this tendency to stretching being proportional to the amount of the force. There are two other factors at work within the sclerotic itself: (1) its tendency to accommodate itself to the stretching effect of the intraocular pressure by an increase of its surface through growth, what the author terms "*philectenia*," as something distinct from mere elasticity; (2) the exactly opposite or reciprocal property of this, viz., the tendency the sclerotic possesses to resist the internal pressure exerted on it, which he calls "*alexectenia*." That these two factors really exist is shown, *e.g.*, in the case of the former, by the fact that in hydrophthalmia we find increased growth of the sclerotic with increased intraocular pressure, and that its growth is in abeyance when this pressure is absent. The contents of the orbit around the sclerotic, apart from exceptional conditions, may be regarded as negligible quantities as regards their effect in preventing the overstretching of the latter: even the external ocular muscles themselves offer very little resistance when the eye is at rest.

The intraocular, or static, pressure (*T stat*) is a constant factor and is dependent on physical conditions within the eye. It acts equally in all directions and thereby tends to produce or preserve the spherical shape of the globe during growth, *i.e.*, the spherical growth is in direct proportion to the *T stat*. On

the other hand the dynamic pressure (*T dyn*) is derived solely from the action of the external ocular muscles. It comes into play only when the component of the force of these muscles that compresses the eyeball rises above the static tension and produces an alteration in the shape of the eye although only to an infinitesimal degree. *T dyn* therefore acts as a mechanical factor on the sclerotic only when it exceeds *T stat*, while the latter is during that period in abeyance as regards its own tendency to produce a spherical globe. As was mentioned before the dynamic tension acts practically entirely on the posterior half of the sclerotic, and therefore tends to increase the antero-posterior diameter, without affecting the lateral or vertical diameters, of the eye. The height to which it rises is naturally dependent on the resistance offered to the escape of the intraocular fluid: otherwise it is proportionate to the compressing force of the external muscles, which is greatest during the act of reading. Other factors, such as the height of the orbit, the distance between the axes of rotation of the two eyes and other anatomical conditions that furnish according to some theories the explanation of the origin of myopia, have some bearing on this point; but for the question of the growth of the eye we are interested only in the static and the dynamic pressure which, as mentioned before, do not act simultaneously, their effect depending not only on their degree at certain moments but also very largely on the duration of their action.

As regards the factors, *philectenia* and *alexectenia*, the author does not express any definite opinion as to the part of the scleral tissue that corresponds to them, but he postulates that they possess a certain variability within "normal" limits just as is observed in the case of the tension of the eye and in the various tissues of different "normal" individuals, while they may vary in the same person through slight differences in the two eyes in the same way that asymmetry is observed in the structure of all bilateral organs.

The growth of the sclerotic (W) is proportional to the tension and the *philectenia* and inversely proportional to the *alexectenia* (A), or put as an equation in terms of the components of the total tension, the static and dynamic, $W = \frac{T\ stat + T\ dyn.}{A.}$

According as the dynamic tension forms the greater or less part of the total pressure on the sclerotic during growth the shape of the eyeball will become more elongated or more round.

The spherical growth is influenced solely by *T. stat*; but in the great majority of cases *T dyn* is operative and controls the growth of the eyeball for longer or shorter periods, and then *T. stat* determines the equatorial diameter and the equivalent amount of the antero-posterior measurement, the remainder of the axial length being due to the dynamic pressure. All close work that is of such a degree as to make *T dyn* greater than *T. stat* tends to increase the axial length of the eyeball and it is according to the strength of the resistive power that eyes may remain hypermetropic, emmetropic, or myopic, or their refraction be changed from H. to Em., or from Em. to M. A series of examples is given showing how within the different normal variations of these individual factors the refraction of eyes may vary between moderate H., Em., and moderate M. Where the *alexeetenia* is abnormally low or has been weakened as the result of malnutrition or disease of the sclerotic one can see that the static and dynamic pressure on the eye will tend to increase the length of the eyeball much more than otherwise, and thereby to produce a high degree of myopia. A study of the variations of these factors according to the equation above-mentioned also shows how the eyes of one person become myopic while those of another do not; indeed, this method of analysis gives a satisfactory general explanation of all shapes (not including astigmatism) and sizes of eyeballs from microphthalmia to high myopia.

The question as to how in one individual we find one eye myopic and the other not is explained by a difference in the strength of these factors in the two eyes due to some asymmetry in certain anatomical details, *e.g.*, the arrangement of the external ocular muscles, the filtration-angle, the blood-supply, or the presence of disease in one eye only or in one more than the other.

The author has long regarded myopia as a deformity analogous to the deformities observed in the bony skeleton and vascular system as the result of weight or pressure. In the case of the latter many individuals, as is well known, develop bow-legs, flat foot, or varicose veins in certain vocations where an abnormal strain is put on the normal resistive power of the bones, ligaments, or veins, and but for this excessive strain these persons would not be so affected: malnutrition or impairment of health may reduce the strength or tone of these structures, or where they are abnormally soft or are weakened by disease they give way under the weight even though it has

not been unduly great. To these varying conditions a parallel is found in the eye—the sclerotic may have normal resistive power but under the stress of excessive and long-continued *T dyn* it gives way and school-myopia is developed: exhaustion from too much school work or an alteration in the circulation of the head and neck temporarily weakens the *alexectenia* and thereby favour the onset of myopia: or where the resistive power is essentially weak or is impaired by disease myopia may supervene even when the static and the dynamic pressure are not abnormally great, *e.g.*, in illiterate persons and among uncivilised races.

The author does not seek to put forward this method of analysis as a full explanation of the origin of myopia but has endeavoured only to throw some fresh light on the subject by an analysis of the forces that are at work in the production of this condition. T. S.

Berlin Ophthalmological Society.

23rd June, 1910.

Report by Dr. Curt Adam.

Thorner: *An Ophthalmoscope without Reflexes.* The indirect method of ophthalmoscopy is in some respects superior to the direct, in that it is not rendered almost impossible, as the other is, when opacities of the media, high errors of refraction, and narrow pupil are present. Even Thorner's own model of stationary ophthalmoscope, which enables the veriest tyro to see the fundus, demands a large pupil and no interference with the path of the rays. He has set himself the task of so modifying the apparatus for the production of the inverted image that it shall be possible for an unpractised hand to employ it. To this end all the optical parts must be simplified and reflexes eliminated. The annoying reflexes from a convex lens are avoided in the new instrument by employing a concave mirror for the formation of the image. By means of a second reflection from a plane mirror the line of vision becomes parallel to the original direction; the observer sees the pupil between the two and is enabled thus to adjust the instrument. The corneal reflexes are avoided because there exists an indifferent zone between the illuminated area and the aperture. The lamp of the instrument seems to the examiner, on account of reflexion, to lie some 16° from the axis and the papilla therefore is at once fixed.'

Köllner: *Hemiachromatopsia.* The author was able to

exhibit three women, suffering from a bitemporal hemiachromatopsia from tumour of the hypophysis. In two of the cases there was genuine acromegaly, in the third infantilism. In cases like his it is not uncommon to find a central scotoma, which indeed existed in two of his. In the third case decided improvement had occurred, with the result that it had now become difficult to demonstrate the hemianopsia. This recovery of function is not uncommon in tumours of the pituitary body and has this point of importance that it may often enough be apparently the result of treatment with preparations of the pituitary body.

THORNER: *Fundus in Diabetic Lipæmia.* Thorner further demonstrated the fundus in a case of retinal lipæmia in a young diabetic subject. The retinal vessels seemed widened, and appeared as pinkish-white bands contrasting strongly with the dark marbled fundus, in which the brownish-red disc showed up strongly. At the same time the choroidal veins seemed to have undergone no change; they appeared of a beautiful red colour. The fat content of the blood actually came up to 26 per cent.—the highest on record. Thorner indicated that he might have something to say on a subsequent occasion in regard to this difference between the two kinds of vessels.

LEWINSOHN: *The Genesis of Choked Disc.* The author spoke first of some work which has recently been done by Schieck in this connection, who has been studying the anatomical condition present in choked disc. He believes that the direction of flow of the fluid is from the eye along the nerve and from the central system along the sheath space through the perivascular lymph spaces of the central vessels. The idea in this theory of the origin of choked disc is that the current of fluid from the eye is choked within the nerve-sheath when the cerebro-spinal fluid becomes altered by the presence of inflammatory products and increased pressure; under these conditions optic neuritis will be the result. The statement of Schieck that this theory is partly a mere variant of Leber's inflammation-theory and of Dayl's hypothesis of venous compression in the intersheath space the author regards as an error. He believes that a purely mechanical influence of increased pressure is not sufficient to dam up the current from the eye and produce choked disc. But whether the change in the cerebro-spinal fluid is due to the presence of some toxine or to some chemical alteration he is not as yet in a position to say. W. G. S.

GLAUCOMA PROBLEMS.[1]

By Priestley Smith, F.R.C.S.

Professor of Ophthalmology in the University of Birmingham.

Sixty years ago, the morbid process called Glaucoma was completely mysterious and completely incurable. To-day, happily, it is neither the one nor the other, but there are still dark places in its pathology, its diagnosis is still sometimes difficult, and we are still striving to improve our methods of treatment. My purpose is to speak of certain doubts and difficulties which still beset the subject, but in approaching these it will be necessary to traverse some familiar ground.

Causes.

The essence of glaucoma is an excess of pressure in the eye. What causes the excess? von Graefe found a means of relieving it in many cases—a brilliant and beneficent discovery—but he was not able to explain either the onset of the malady or the curative action of iridectomy, for in his day the physiology of the intra-ocular fluids had not been worked out. Let me remind you of some essential facts, now well established, concerning these fluids.[2]

The aqueous is derived from the capillaries of the ciliary processes. The rate of its production depends on the difference between the pressure of the blood and the pressure of the fluid in the aqueous chamber, and not

1. An address given at the Oxford Ophthalmological Congress, July 1910, revised and amplified.

2. For the most authoritative exposition of this subject, see Th. Leber, *Graefe-Saemisch Handbuch*, Vol. 2, part 2, 1903; and Parsons, *Pathology of the Eye*, Vol. 3, 1906.

on the action of specific nerves. The process, therefore, has the character of physical filtration rather than of active secretion.

The aqueous passes forward through the pupil, and in so doing meets with some resistance on the part of the iris—incalculably small, no doubt, but not entirely unimportant. The iris does not lie in one plane, but is concave towards the lens so that its sphincter and dilator fibres in acting on the pupillary zone exercise a slight backward pressure against the lens. This is witnessed by the fact that when the lens recedes the iris follows it. There is, therefore, at times at least, a minute difference of pressure on the two sides of the iris. This is not mere theory. It was demonstrated in a case where a congenital gap in the iris was closed by a very thin membrane. Under minute inspection the membrane was seen at times to bulge forward; then to subside and even become concave; then again to bulge forward: a proof that the aqueous did not pass through the pupil uninterruptedly, but collected and escaped alternately.[1]

The aqueous passes out of the eye by filtering into Schlemm's canal and probably, though in much smaller quantity, into the veins of the iris and ciliary body with which the canal is connected. Schlemm's canal is itself an extremely thin-walled vein, or plexus of veins, specially adapted for the removal of the aqueous. It is a mere tube of endothelium built into the inner surface of the sclera and separated from the aqueous only by the spongy tissue of the pectinate or cribriform ligament.[2] The latter contains much elastic tissue and is kept more or less tense by the tonic traction of the ciliary muscle which takes origin from it (see Figs. 1*a*, *b*, *c*, and 2*a*, *b*, *c*). Schlemm's canal is thus apparently protected

1. Ulbrich, *Report of Heidelberg Ophth. Cong.* of 1907, p. 105.

2. The term "cribriform," suggested by Thos. Henderson, seems better than "pectinate" as regards both the appearance and the function of this important structure.

against closure of its lumen by the pressure of the aqueous; its internal pressure, therefore, may be no higher, and may even be lower, than the aqueous pressure: a condition peculiarly favourable to filtration.

The iris veins, to which the aqueous has access through the crypts, appear to be less well fitted for absorption. Being little protected against compression, their blood pressure must, presumably, be a little higher than the aqueous pressure, or they would collapse, though this of course does not preclude a possibility of absorption, for in the case of fluids differing in density, as do the aqueous and the blood, osmosis can occur against a higher pressure. Another difficulty is that the iris may be atrophied or absent without noticeable effect on the tension of the eye. Experiment, however, appears to show that these veins can take some part in the removal of the aqueous.

The function of the filtration angle was discovered experimentally by injection of fluid, coloured or having particles in suspension, into the anterior chamber. The phenomena of disease occasionally afford a corroborative demonstration of similar kind. Figures 3*a*, 3*b* were taken from an eye in which pigment cells shed by a tumour of the iris were carried by the aqueous to the angle of the chamber at every part of the circle and there arrested in the filter.

The aqueous is formed at the rate of about 5 cub.mm. in a minute, so that the whole content of the aqueous chamber is changed in less than one hour. The rate of escape is, of course, equal to the rate of formation, except at those times when the volume of blood within the eye is increasing or diminishing, or when the globe is enlarging or contracting, a change which is possible only to a very small extent.

The vitreous fluid—that which fills the meshes of the vitreous body—has the same constitution as the aqueous, and is derived in like manner from the capillaries of the

ciliary processes. The amount passing through the vitreous body in a given time is very much smaller than that passing through the aqueous chamber. A very small amount of fluid perhaps escapes from the vitreous at the papilla, but this is hardly proved; in any case it is certainly less than $^1/_{50}$th of the amount escaping at the filtration angle. The hyaloid and zonule which form a partition between the vitreous and the aqueous chambers are permeable by the vitreous fluid, and under certain circumstances, if not continually, give passage to fluid from the vitreous into the aqueous chamber. For example, if we puncture the cornea after death so as to evacuate the aqueous chamber, it soon refills to some extent with fluid from the vitreous. So long as the permeability of the hyaloid and zonule is unimpaired, the vitreous fluid can filter readily through the partition and mingling with the aqueous escape at the filtration angle.

The pressures in the aqueous and vitreous chambers are equal, or so nearly equal that no difference is discoverable by the manometer. Experiment shows that a very slight excess of pressure in either chamber suffices to displace the lens forward or backward, as the case may be. The stability of the lens in its normal position is no doubt ensured by the permeability of the hyaloid, somewhat as that of the tympanum is ensured by the patency of the Eustachian tube. In some abnormal conditions of the eye, however, the aqueous and vitreous pressures are unequal, and the lens is displaced from its normal position. For example, when we lower the aqueous pressure by a corneal incision the lens advances until the increased tension of the zonule balances the higher pressure of the vitreous. In many forms of disease, and especially in glaucoma, we see a similar displacement of the lens. The point is important and I will venture to illustrate it in a homely way:—Hang a curtain across an open doorway. So long as the air is

absolutely at rest the curtain is subject to equal pressure on the two sides and will hang vertically. Let the slightest current of air arise and it will be more or less displaced. If the current is slow and the curtain made of open material, the displacement will be slight, perhaps undiscoverable; if the current is quick or the curtain less pervious, the displacement will be considerable.

The pressure of the fluid in the chambers of the eye is derived from that of the blood. In studying the problems of glaucoma it is necessary to realise the way in which blood pressure and chamber pressure act and react on each other. The matter, though at first sight somewhat complicated, need not detain us long.

The blood pressure in the interior of the eye is higher than the chamber pressure. Were the relation reversed the blood vessels would of course collapse. Were the pressures equal, even, the circulation would be in constant danger of arrest. On the papilla we often see a small part of the retinal vein, close to its point of exit, collapsing with every arterial impulse. The incoming arterial wave raises the chamber pressure for the moment above the venous; the two are about balanced; each in turn dominates the other. We know that the ordinary chamber pressure is about 25 mm. Hg, and we may be sure that the blood pressure in this part of the retinal vein is about the same. In the choroidal veins it cannot be lower. In the capillaries of the ciliary processes it must be considerably higher or they would not emit the aqueous fluid—it is estimated at 50 mm. Hg or more. In the arteries it is higher still, being certainly not less than 90 to 100 mm. Hg.

Further, the blood pressure dominates the chamber pressure not only under normal conditions, but under all conditions so long as the blood circulates. However high the chamber pressure may be, and whatever the cause of its excess, the blood pressure, even in the veins, is always higher still, for the chamber pressure can never

suffice to close the arteries, and the arterial blood will always raise the pressure of the venous blood sufficiently to overcome the excess of pressure in the chambers.

With these facts and principles in mind let us now turn to the problem of glaucoma. What are the *possible* causes of plus tension? Speaking broadly they are of two kinds, namely changes which raise the blood pressure in the eye, and changes which impede the escape of fluid from the chambers.

High blood pressure artificially induced, whether by increasing the inflow or by impeding the outflow of blood from the eye, is capable of greatly raising the tension of the eye for a while, but not of establishing a permanent excess. Clinically we often find high blood pressure in persons suffering from glaucoma; it is often a factor and sometimes a disastrous one in the morbid process; but it affords no sufficient explanation of it, for intense glaucoma may occur in persons whose blood pressure is low, and many in whom it is very high have no discoverable tendency to glaucoma.

Changes capable of obstructing the escape of fluid from the chambers, on the other hand, are discoverable in almost every form of glaucoma. We should expect them to be of various kinds and we find them to be so. We find changes in the fluid itself which render it less capable of filtering from the vitreous to the aqueous chamber, and from the latter into Schlemm's canal; changes in tissues, and silting up of spaces, through which the fluid has to pass; conditions which obstruct its passage through the pupil; and, commonest of all, compression and closure of the filtration angle.

We see glaucoma arise without discoverable cause, and we see it occurring as a complication of other disorders of the eye, but even in these latter cases the essential obstructive change is frequently hidden from inspection in the living eye. To investigate it we must

usually turn to eyes which have been blinded by glaucoma and removed for the relief of pain. Such eyes represent, of course, not the beginning but the end of the glaucoma process, but they give us invaluable information.

Eyes blinded by glaucoma and excised are hard not merely at the moment of excision; they remain hard a long while afterward; a proof that their high tension is not merely a consequence of high blood pressure. Tested by injection of fluid into the anterior chamber they are found to permit of little or no escape. Hardened, frozen, and bisected, they usually show changes which must have obstructed the escape of the aqueous. I exhibit photographs taken from eyes blinded by various forms of glaucoma, secondary and primary. The disc, when visible, should be scrutinised for evidence of tension, the filtration angle for evidence of obstruction.[1]

Figures 4*a* and 4*b* show a form of secondary glaucoma in which the high tension is due to a morbid condition of the aqueous fluid. A serous fluid injected experimentally into the anterior chamber of a normal eye after death escapes much more slowly than does a normal saline solution. A serous exudation from the ciliary processes entering the aqueous chamber is retarded in its escape, distends the chamber, and raises the tension of the eye. Hence the unusual association in this specimen of a widely open filtration angle with a deeply cupped disc. An objection has been raised to this explanation of the deep chamber of serous cyclitis.[2] If the hindrance to filtration through the cribriform ligament deepens the chamber in this form of glaucoma, why not in other forms also where access to Schlemm's canal is impeded in other ways? That is the argument. The answer, I think, is this:—When the fluid which fills the anterior chamber is highly albuminous, it can

1. A magnifier may be used with advantage.
2. Parsons, *Pathology of the Eye*, Vol. 3, p. 1073.

filter properly neither outward through the cribriform ligament nor backward through the zonule and hyaloid and the lens is thereby liable to displacement backward, but when the fluid is normal the permeability of the hyaloid is likely to obviate such displacement. In those forms of glaucoma in which an advance of the lens closes the filtration angle, the order of events obviously precludes any deepening of the chamber.

Figures 5 and 6 show a common form of secondary glaucoma due to occlusion of the pupil. If proof be wanted that it is the imprisonment of fluid behind the iris that raises the tension, cups the disc, and ultimately blinds the eye, it is afforded by the fact that a timely iridectomy or even a puncture through the iris, providing a passage for the retained fluid into the anterior chamber, immediately banishes the bulge of the iris, lowers the tension, and saves the eye. Where, as in figure 6, the iritis is a late development of a uveitis which has already detached the retina, the onset of high tension calls, of course, for removal of the eye rather than for iridectomy.

Figures 7*a*, 7*b*, and 8 show another form of glaucoma in which the initial obstacle in the path of the aqueous is situated, as in the last case, at the pupil. Here, however, the iris lies behind the lens instead of in front of it. The pressure of the aqueous imprisoned behind the iris leads to a solid and complete blockade.

(*To be continued.*)

REVIEWS.

Emil Juselius (Wiborg). **An Experimental Research into the Regeneration of the Corneal Epithelium under normal conditions, and also when influenced by therapeutic methods.** *v. Graefe's Archiv für Ophthalmologie*, vol. 75., pt. 2, p. 350.

This is a record of a most interesting piece of work. The author set himself to find out by experimental means what influences favoured and supported regeneration of the corneal

1 a.



1 b.

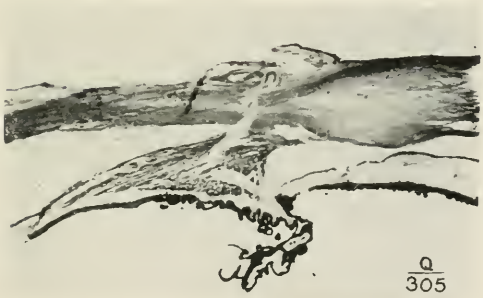

1 c.

Figs. 1 a, 1 b, 1 c. Sections from ciliary region of a healthy emmetropic eye removed on account of orbital tumour. Male: age 48.—Hardened in Mueller's fluid, stained with picro-carmine, mounted in glycerin jelly. —Ciliary body drawn away from sclera by traction of zonule. Tissues somewhat spread out by pressure of cover-glass.

2 a.

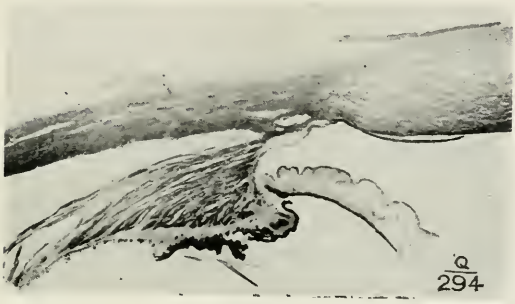

2 b.

2 c.

Figs. 2 a, 2 b, 2 c. From a healthy emmetropic eye removed after death. Male; age 57.—Prepared and mounted as last.—The free fibres passing from cribriform ligament to root of iris, seen in 2 a, 2 b, and in many other sections from this eye, are unusual in human eyes, but normally present in eyes of lower animals, in which they form the spaces of Fontana (see Leber's Fig. 25, *Graefe-Saemisch Handbuch*, Vol. 2).

3 a.



3 b.

Figs. 3 a, 3 b. From an eye affected by small melano-sarcoma of iris of many years' growth. Female: age 43.—Mueller's fluid: not stained: glycerin jelly.—Cells cast off by tumour are seen in tissues surrounding filtration angle throughout entire circle of chamber, in cribriform ligament, in anterior part of ciliary muscle, more sparingly in root of iris: also on anterior surface of iris, and here and there in crypts. Tension normal at time of excision. No pressure change in disc. (Report of case in *Trans. Ophth. Soc.*, Vol. 2, p. 257).

4 a.

4 b.

Fig. 4 a. Eye blinded by cyclitis with high tension. Male; age 21.— Mueller's fluid: glycerin jelly.— Filtration angle widely open and occupied in places by coagula. Anterior chamber deep. Disc deeply cupped. At time of excision tension high, pupil dilated, deposits on back of cornea and in lower part of chamber.

Fig. 4 b. Section from ciliary region of same eye.

5.

6.

Fig. 5. Blinded by posterior synechia with high tension. Male; age 20.—Mueller's fluid, thick section, glycerin jelly.—Pupillary zone of iris adherent to lens throughout whole circle. Non-adherent part of iris pushed forward by aqueous imprisoned behind it. Filtration angle closed thereby. Disc deeply cupped—not visible in this section.

Fig. 6. Detachment of retina. Later, iritis with posterior synechia, and secondary glaucoma. Male; age 32.—Formalin solution.—Disc cupped.

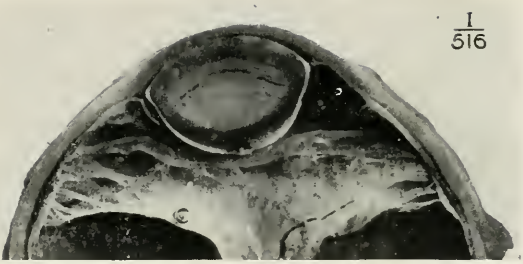

7 a.



7 b.

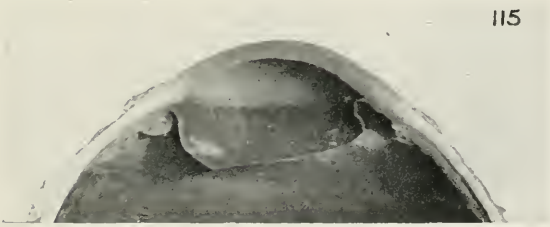

Fig. 7 a. Nearly blind through retinitis pigmentosa. Then spontaneous dislocation of lens into anterior chamber followed by severe secondary glaucoma. Excision on ninth day. Male; age 65.—Mueller's fluid and glycerin jelly.—Lens and unsupported part of iris driven forward against cornea by imprisoned aqueous. Access to filtration angle cut off. Case reported in *Ophth. Rev.*, Vol. 1, p. 209.

Fig. 7 b. Section from ciliary region of same eye—left side in Fig. 7 a.

Fig. 8. Dislocation of lens, as in previous case. No details known. Lens removed to show position of iris. Disc cupped.—Mueller's fluid and glycerin jelly.

epithelium after an injury; and what if any influences exerted a stimulating effect upon the healing process.

The work was done upon the eyes of rabbits and dogs. His method of producing the injury was to adjust a corneal trephine of v. Hippel's pattern so that it would make a circular incision 4 mm. diameter in the central area of the cornea down to and into Bowman's membrane. The area inclosed by the incision was then lifted off from its bed; in effect he completely bared the central area of the cornea.

The first part of the paper is occupied by a description of the processes of regeneration observed in microscopic sections taken at various intervals after the injury. He finds four stages:—(1) Karyokinesis begins at the rim of the cornea close to the limbus. (2) In about four hours the wave of mitosis has reached half way between the limbus and injury, and at six hours nearly up to the injury. (3) The mitosis has reached the edge of the injury. (4) A roll of growing epithelium has filled the face of the cut edge of the denuded area, and is beginning to spread centrally. The mitosis and growth takes place in the basal cylindrical cells.

In the study of therapeutic influences on healing he thinks surface injuries that simulate ulcers much more satisfactory than perforations. He used a graphic method of recording his results which are very clear. Drawings are made upon the same scale of the average rates of healing in the denuded area under different methods of treatment, in each instance the treated and untreated eyes are placed side by side for comparison.

(*a*) Effect of cocaine, tried upon 35 rabbits. Four per cent. solution, two drops four times daily. The stages are marked every six hours after 18 hours. The untreated eye was healed in 54 hours, the cocainized eye then presented an unhealed surface of the size shown at 42 hours in the untreated eye. Hence cocaine delayed healing.

(*b*) Subconjunctival injections of salts, tried on 38 rabbits. Normal saline 3 cc. daily. The treated eye healed rather more rapidly than the untreated, 2 per cent. solution common salt caused still more improvement. Four per cent. solution common salt hindered healing, and 6 per cent. delayed it considerably. Subconjunctival injections of sublimate tried on 14 animals. One injection of 1 cc., 1 in 10,000, healing very slightly enhanced. Solution of 1 in 2,000 healing greatly delayed, ingrowth of vessels into the cornea took place from

above; at 54 hours the untreated eye was healed, and the treated eye presented a raw surface as large as the untreated eye at 18 hours.

(*c*) Heat and cold, tried on 8 dogs. Moist heat proved of the greatest benefit of any of the reagents tried, the raw surface was nearly healed in 48 hours. Cold acted very badly; no attempt at healing at 24 hours, and very little at 36 hours; then the experiment was discontinued. Cold was bad.

(*d*) Dionine tried on 4 cats, 3 dogs, and 3 rabbits. He used a 10 per cent. solution, and concluded from his experiments that the drug had a slightly beneficial effect, "but not much"; more in rabbits than in dogs.

The finding of the benefit of moist heat is in confirmation of the experience of most surgeons, and an interesting scientific proof of the correctness of what is perhaps one of the most ancient, widespread, and comfortable methods of empirical treatment. The more elaborate and fashionable modes of stimulating healing come out rather poorly by comparison.

N. Bishop Harman.

Botlazzi & Scalinci. **Chemico Physical Investigation of the Crystalline Lens.** *Atte. R. Accad. Lincei*, V. 17 ii. 153, to 18, i. 228.

The aqueous humour of the eye contains normally a very small proportion of protein which is coagulable by heat, but has not the characters of lenticular protein, and probably has its origin in the blood or lymph. The vitreous body resembles a sponge, the network of which consists of protein substances coagulable by heat and contracts during coagulation expressing the liquid contained in the alveoli. This liquid contains a small quantity of a substance precipitable by acetic acid and insoluble in excess of the acid, and is possibly identical with the coagulable protein found in the aqueous. Neglecting these small quantities of proteins the ocular liquids may be regarded as aqueous solutions of crystalloids mainly of sodium chloride. With regard to their chemical reaction they behave like a solution of bicarbonate of soda containing sufficient carbon-dioxide to render it neutral to such indications as phenolphthalein.

The lens itself contains an electro-negative protein which is only soluble in water in the form of acid protein in the absence of alkali or of alkali protein which is soluble also in absence of salts.

The penetration of water into the lens and the swelling and increase in weight of the latter is due to some extent to a process of inhibition and not as is usually supposed, solely to the osmotic pressure of the lens. As there is not an imbibition equilibrium between the lens and the water in which it is immersed the water penetrates the lens at first rapidly and subsequently more slowly. The lens tends towards a maximum of imbibition, which is however only attained if the capsule is ruptured. In this imbibition there are two distinct periods—in the first of which water penetrates the lens and causes it to swell uniformly, whilst in the second the water accumulates between the lens and the capsule. Experiment shows that the percentage increase of weight of a lens from which the capsule has been removed is less than in the case of a lens which retains its capsule. When the capsule is present the lens increases rapidly in weight during the first half hour of immersion, after which the increase is first checked for a time and then proceeds more gradually. This is due to the diffusion from the lens of the soluble protein, the loss thus caused being sufficient to compensate for a time the increase in weight due to imbibition.

When suspended in saturated water vapour at 38° the crystalline lens does not increase but gradually diminishes in weight, a process of disimbibition taking place. From this point of view the lens resembles a block of solid gelatin which behaves in an exactly similar way. The amount of disimbibition of the lens in water vapour is for a definite time directly proportional to the initial weight of the lens whilst the increase in weight of a lens due to imbibition of water is inversely proportional to that weight. The mechanism of the process of disimbibition is essentially different from that of the process of imbibition. When the lens of the dog or rabbit is suspended in dry air it loses in weight rapidly for four to six hours and then slowly. Notwithstanding the great loss in weight which amounts to between 30 and 49 per cent. in four hours the lens does not become opaque but only wrinkles, so that the opacity of the lens is not due to dessication alone. When the dessicated lens is immersed in water vapour it increases in weight very slowly, the original weight of the lens not being attained after eighty to ninety hours. In some cases a slight loss in weight occurs during the first few hours of immersion in water vapour. When the dessicated lens is immersed in water the increase in weight is rapid during the first two hours, after which time the water is only taken up very gradually.

Lenses of dogs' eyes immersed in aqueous or vitreous humour were found in one case first to diminish and then increase, and in another first to increase and then diminish in weight. The diminution in weight may be explained as due to the diffusion outwards of the protein substances of the lens surpassing the penetration of liquid into the lens. The increase of weight can only be the effect of an increase in the degrees of imbibition of the lens in consequence of a diminution of the elasticity of the capsule.

In all the experiments the body of the lens remained quite transparent, not only when the uninjured capsule limited the inhibition, but even for nineteen hours after the capsule had been removed. Hence a much longer period is necessary for the increase of the degree of imbibition of the crystalline lens immersed in normal ocular liquids to produce opacity of the lens.

J. Burdon Cooper.

Deschamps (Grenoble). **On Serotherapy of Rheumatic Affections of the Eyes.** *La Clinique Ophtalmologique.* May 10th, 1910.

The pathogenic agent of rheumatism is, in the author's opinion, the bacillus of Achalme, which resembles anthrax bacillus.

Deschamps of Grenoble gives his experience with the Rosenthal-Berliox anti-rheumatic serum. He appears to have taken great pains to select only true cases of rheumatic iritis, but on carefully reading these one is inclined to think they may have been due to gonorrhœal infection. However, the cases selected were severe and aggravated types of iritis with much albuminous exudation into the anterior chamber, which did not yield to the ordinary treatment of salicylates, mercury, atropine, etc. The patients were subsequently subjected to injections of the anti-rheumatic serum (20 cubic centimeter doses), two and even three injections being given at short intervals with startling immediate results. That is, the exudation of the anterior chamber disappeared like magic. It would appear, however, that this relief was not maintained for any length of time, as after 10 days there were relapses, though mild, in each case.

The author's conclusions were that these injections were not altogether free from certain drawbacks, such as serum rashes, and in one instance they were followed by alarming symptoms.

It would seem therefore that this serum treatment is to be used as an adjuvant to the ordinary anti-rheumatic one, and when the injections are repeated, the patient must be carefully watched. M. Deschamps also recommends chloride of calcium in 2 grammes doses daily, as a preliminary to the serum injections.

G. W. Thompson.

---

de Kleijn, A. **On Affections of the Optic Nerve in Disease of the Posterior Accessory Sinuses of the Nose.** *von Graefe's Archiv für Ophthalmologie*, 75, 3.

This paper is based upon a study of the size of the blind spot, as determined by perimetric observations, in cases of ocular disease associated with disease of the accessory sinuses of the nose.

The commonest of these conditions is neuritis axialis, that form of retrobulbar neuritis in which the macular bundle alone is affected. In twenty-two cases, the sinus disease was diagnosed with certainty by rhinoscopic examination in nine and established by operation in thirteen. In sixteen cases the neuritis was bilateral. The peripheral field and the vision were normal in all.

Only small abnormalities, such as tortuous veins and slight hyperæmia of the papilla, were detected ophthalmoscopically. In nineteen cases the blind spot was enlarged, sometimes for colours only, sometimes for colours and white. In three cases this was absent, although operation showed distinct disease of the sphenoidal and posterior ethmoidal cells.

Decided improvement usually followed regular lavage of the nose, but as a slight enlargement of the blind spot remained, surgical measures were adopted. After operation the blind spot returned to normal dimensions.

Rhinoscopic examination proved indefinite in two cases in which posterior sinus disease was disclosed by operation, which was undertaken on account of enlargement of the blind spot; in two others in which there was uncertainty as to whether the anterior sinuses only, or the posterior as well, were affected, the absence of this sign suggested restriction of the disease to the former and this was found at the operation.

During tamponade of the sinuses the blind spot became smaller in some cases, in others larger. The author attributes the change in the first case to improved circulatory conditions, in the second to damming up of toxic products by the tampon.

It was also noted that the findings in regard to the blind spot varied from time to time in the same patient, a circumstance which is ascribed to the action of factors changing hourly in intensity. Several of the cases are described at length, and the remainder are tabulated. In a supplementary note the operated cases are brought up to twenty-two by the addition of nine which presented conditions similar to those already described.

Proceeding to discuss the neuritis axialis in association with detachment of the retina in connection with sinus disease, the author quotes cases reported by Kuhnt, Broeckaert, Fish, Widmark and v. Graefe, and adds three observed by himself. Besides detachment of the retina one showed a central colour scotoma and the other two enlarged blind spots. After opening up the sinuses complete cure resulted in two cases, in the other—the most extensive—reattachment occurred rapidly but relapse followed very soon.

These cases fall into three groups. The first includes cases of secondary detachment following vitreous opacities. These cases are probably more closely related to choroiditis than to sinus disease. Then there are detachments occurring after retrobulbar intra-orbital inflammation. Here the condition disappears with the subsidence of the inflammation and is to be regarded as due to a subretinal œdema. The third group contains cases in which there is retrobulbar neuritis but no intraorbital inflammation. Circulatory disturbances connected with the neuritis are to be held responsible for the detachment. In one case of post-neuritic atrophy of unknown ætiology sinus disease was diagnosed by exclusion, although only the slightest indications were found in the nose. The posterior ethmoidal and sphenoidal cells were found full of polypi and pus, and although no improvement was obtained further decline in the vision was checked.

In papillœdema without evidence of cerebral tumour the author recommends exploration of the post-nasal sinuses, having regard to the harmlessness of the operation on the one hand and the danger of atrophy on the other.

Lastly, in a case presenting the clinical picture of thrombosis of the central vein of the retina in which V. was equal to $^1/_{60}$, recovery ($V. = {}^2/_6$) rapidly followed operation on the nasal sinuses. The author suggests that the condition was due not to genuine thrombosis but to narrowing of the vein due to

surrounding œdema, followed by disease of the vein wall. This would explain the rapid recovery.

The paper is illustrated by a plate showing outlines of the blind spots taken from time to time in some of the cases.

In his conclusions the author urges the importance of perimetric observations on the blind spot as affording valuable indications as to diagnosis and treatment in cases of sinus disease, and considers the opening up of the accessory nasal sinuses justifiable in all affections of the optic nerve and retinal detachments where the ætiology is obscure, as the sinus disease is frequently completely latent.

Beyond stating that the observations were made with a perimeter no details are given as to the exact method of ascertaining or estimating enlargement of the blind spot. It is to be considered pathologically enlarged if the boundaries for white and colour do not coincide or if it is so large as to be obviously inacceptable as normal, or if, appearing normal at the time, it subsequently becomes smaller. The author gives no hint as to what he considers a standard blind spot, nor does he mention the normal occurrence of a ring of relative amblyopia around the blind spot. H. M. Traquair.

Smith Henry, (Amritsar). **Subconjunctival Injections of Cyanide of Mercury in Trachomatous Conditions.** *The Indian Medical Gazette,* August, 1910.

Col. Smith in this paper states that he has found that the subconjunctival injection of cyanide of mercury is far more successful in the treatment of trachomatous pannus than any other agent he has tried. He uses a 1 in 4000 solution and injects 20 cb.mm. at a time beneath the upper part of the bulbar conjunctiva. The injection should not be made below as if made there it does not reach sufficiently to the upper fornix. The pain at the time and for three hours afterwards is so severe as to necessitate a hypodermic injection of morphia. The pain ceases when the œdema of the eye-lids has set in. This œdema takes about seven days to subside. The reaction resembles that set up by jequirity, when that action is ideal, but differs in so far as it never gets out of control. If a second injection is considered necessary it should be given six days after the first. Three or four injections are, in the author's experience, generally sufficient for the most obstinate cases. E. E. H.

BEST, Dr. F. **Remarks on Hemianopia.** *v Graefe's Archiv für Ophthalmologie*, vol. 74.

THIS paper of Best's is in support of a paper by Behr and against the views of Lenz. Both the latter authors have written recently on this subject in *v. Graefe's Archiv.* The point argued about is as follows. It is well known that in some hemianopic fields the line of division is an exact vertical one, and in others it has a curve avoiding the macula region. This peculiarity appears to prove that the optic fibres travel differently in different parts of their course, and it is assumed that in the beginning of the optic tract the fibres from each half are exactly divided, so that an interruption here will cause a hemianopia with a vertical division. Later the macula fibres are divided so that from here to the cortex an interruption can no longer totally destroy one half of the field, but the macula is spared.

This question has also a physiological interest, for the disease might bring to light the physiological line of division which separates the course of the fibres of the two halves of the retina, and Hering has used the fact of the semi-decussation of the optic nerve as proof that our optical sensations of space are congenital and that there exists a congenital connection between corresponding points of the two retinæ, while others have held that the correspondence of the two retinæ are based upon individual experiences and practice. If therefore it can be shown that the hemianopia line of division corresponds to the physiological line of division this would be an additional proof of Hering's theory, and for this purpose only hemianopias with vertical lines can be used, and these are rare.

Best's case is as follows. A patient aged 19, who had always had good eyesight, fell out of a second floor window a distance of about 18 feet and lay unconscious, with bleeding from the ears, nose and mouth, apparently having fallen upon the right side of his face. He remained unconscious for 10 days, and on recovering found that he was blind in his left eye and with his right eye he could not see objects lying to his right and also that he was deaf on the left side.

Four months later he was taken into the eye department and the following condition was noted—V.: R. $= {}^{6}/_{10}$, L. amaurosis. The eyes appeared normal and their movements were normal. R. hemianopic pupil reaction which also produced a consensual movement in the left. L. no pupil reactions could be obtained. R. optic disc was pale on the temporal side. L. disc completely

white and atrophic. The field of vision showed a temporal hemianopia with a sharp border line passing through the fixation point. The extent of the retained field was normal for white and colours. In addition there was left deafness from destruction of the labyrinth.

In order to investigate the border line of the hemianopia further, the patient was placed 50 cm. away from a wall and a fixation point was marked level with his eyes, by this means the border line was found to be almost absolutely straight. On joining the upper and lower end points by a line drawn with a ruler, it was found that the points marking the border line did not vary from this at any point more than 2 mm., and this is quite sufficiently explained by alterations in the position of the head.

The second point brought out by these measurements was that the border line although straight was not absolutely vertical, but the upper end of the line was inclined to the right of the perpendicular about 2° 49′. A horizontal line through the fixation point appeared to the patient to be horizontal, but a vertical line had to be tilted about 2° to the right before it appeared vertical to the patient.

On attempting to divide horizontal lines in the middle the patient made the typical mistake, described by Kalmus and Liepmann of making the half lying on the side of the retained field too large, and in this patient the proportion between the left half and the right half was on the average 239 to 208, while the division of vertical lines was 125 upper half to 128 lower half.

Finally this patient was seen a year later when the condition was exactly the same.

The injury in this case, although not confirmed by section, was obviously an injury to the left optic tract, the left optic nerve and possibly a tear of the chiasma. The early onset of the optic atrophy is against any cortical cause and the other symptoms all point to a fracture of the base of the skull. Therefore, in this case at least, hemianopia due to involvement of the tract does not spare the macula and Best makes the rule general, basing his opinion on the work of Lenz who from a study of published cases decides that this is most probable. Obviously further cases are required before this can be taken for granted, although so carefully observed and reported a case as this one is of the utmost value.

As regards the inclination of the vertical border line, this

corresponds with the inclination of the physiological line of separation of the two halves of the retina, which according to Hering varies between 0 and $1\frac{1}{2}°$. It was impossible to determine accurately this physiological line in our patient because the other eye was completely blind, but an approximation could be obtained by drawing a horizontal line, which also appeared to the patient to be horizontal. On getting him to fix the right end of this line another line was drawn which appeared to him to be vertical. This line had an inclination of its upper end to the right of about 2°. From this it follows with a fair amount of probability that the hemianopic border line corresponds to the physiological line of division. It does not follow that in all cases this line will be an absolutely straight one, for individual variations occur which might make this line slightly curved or irregular and this fact must be remembered in making further investigations, and also that a visual acuity of somewhat more than 0·5 is possible even with a hemianopia going through the macula.

Behr is of opinion that the hemianopic pupil reaction can be used to determine the situation of the injury. It does not occur in affections of the occipital cortex, but does occur as long as the pupillary fibres accompany the optic fibres, that is to say in the optic tract, and this case gives confirmatory evidence of this point. The hemianopic pupil reaction is obtained perfectly easily in these cases without the use of any special apparatus and therefore the view that this reaction can never be obtained on account of the diffused light falling on all parts of the retina does not hold good.

In order to understand the occurrence of the faulty judgment of distances by the hemianopic eye, it is necessary to reproduce the deficiency in an experiment. If an attempt be made to divide a horizontal line by using only one half of one field of vision by fixing the eye on one end of the line and not allowing it to travel along its whole length, one will obtain results exactly similar to the hemianopic person. That is to say that objects lying peripherally look smaller than objects lying centrally and therefore the part of the line lying peripherally is made larger so as to make it appear equal to the portion lying in the region of central vision. If we consider the angles under which the different portions of such a bisected line are seen, we find that a line 240 mm. long at 250 mm. distance is divided into a central portion of 97 mm. and a peripheral portion of 143 mm. and that the visual angle of the central portion is 21° 12′ and

of the peripheral portion 22° 48′. That is to say a line bisected in indirect vision is cut so that the visual angle of the two portions is about the same. Exactly similar visual angles could only be obtained if the line was slightly curved so as to be concave towards the observer, and then only if no attempt at determination of depth could be made. Other explanations of this fact of false measurement by hemianopics have been given —for instance that it may be due to errors in judging of the movement of the eyeball, that this does not hold was shown by a case of Loeser's where there existed also an abducens paralysis, without any alteration in the measurement errors. Another explanation made it dependent on the difference of the extent of the field of vision in the different meridians with the consequently different amounts of foreshortening.

The conclusions which Best thinks himself justified in drawing from his investigations are as follows:—

(1) In tract hemianopias the border line runs vertically through the fixation point without avoiding the macula.

(2) This border line coincides with the physiological line of separation of the two halves of the retina.

(3) In tract hemianopia the hemianopic pupil reaction is obtained, and not in cortical hemianopias.

(4) The hemianopic error of measurement is also found in normal eyes in indirect vision. The apparent shortening of the periphery in indirect vision is due to the fact that judgment is based not upon the actual size but upon the relative visual angles. This however is compensated for if differences in depth can be appreciated.

These conclusions are obviously of great importance and before they can be accepted in their entirety many more cases must be reported, and it is to be hoped that any one meeting with cases of tract hemianopia will publish as full a report as possible. A. Levy.

Hayashi, M. **Experimental Investigation of the Infection-Liability of the Eye in Diabetes, and of the Bactericidal Effect of Diabetic Blood Serum upon Pus Formation.** (From the University Eye Clinic, Breslau) *v. Graefe's Archiv für Ophthalmologie*, Bd. 76, Heft. 1.

In a long and careful paper, Hayashi gives an account of researches undertaken by him with a view of obtaining experimental evidence upon the liability of the eye to infection during or after operation, in the subjects of diabetes mellitus.

Cataract being the most frequent and one of the most serious of the ocular complications of diabetes, and one which is remediable by surgical interference, it is of great practical importance to know to what extent the prognosis after operation is modified by the existence of glycosuria.

Since von Graefe, who believed flap extraction in diabetic cataract to be very unfavourable, many observers have studied and reported the results of operation upon diabetics. Among them Boucheron came to the conclusion that as diabetics were so much more prone to suppuration than healthy patients it would be advisable to give injections of anti-streptococcus serum before operating for cataract.

Hayashi gives a brief resumé of the opinions of authorities who have studied the question clinically.

He then reviews the literature of experimental work on this subject, especially in reference to the artificial production of glycosuria in animals, and upon the influence of glycosuria upon the pathogenicity of pus-producing organisms. Experimenters are all agreed that the existence of diabetes has a marked influence upon the activity of pyogenic microbes.

Hayashi's experiments were made upon rabbits rendered diabetic by the injection of amyl-nitrite, or adrenalin, and upon dogs treated by removal of the pancreas. Total extirpation of the pancreas, in the dog, is usually followed in a few hours by severe diabetes, which reaches its acme in one to two days and proves fatal in a few days or, rarely, in a few weeks. The clinical symptoms in dogs thus treated are similar in nearly all respects to those of diabetes in man.

In his infection experiments Hayashi used staphylococcus pyogenes albus and aureus. His experiments are recorded in considerable detail and in tabular form. Nothing would be gained by an attempt to epitomise his description, and those who are interested must have recourse to the original article.

The results and conclusions of the writer are briefly as follows:

The researches of Th. Smith, Grossmann and the writer have definitely shown that a sugar content of comparatively low grade (0·3 to 0·5 per cent.) such as is usual in the tissues in diabetes, is favourable to invasion by pyogenic micro-organisms and enhances the virulence of such organisms.

Experiments on animals rendered diabetic in the methods described above show that pus-producing cocci thrive better and gain in pathogenicity in their tissues than in those of healthy

animals of the same kind. In the diabetic animal a subcutaneous injection of a staphylococcus culture will lead to the formation of a large abscess, while in the normal control animal a similar injection is quickly absorbed.

The bactericidal power of blood serum in adrenalin-diabetes in rabbits and pancreas diabetes in dogs is markedly less than that of blood serum from healthy animals. In man, as the result of a few observations, the difference in the power of blood serum in diabetes and in health is less noticeable than in animals.

Hayashi's experiments show, as far as experiments can be conclusive as regards man, that the eye of a diabetic is decidedly more prone to infection during operation, than is the eye of a healthy person.

Although experimental results indicate that it is most desirable to obtain a complete absence of sugar in the urine before operation, the experience of operators tends to show that it is not always advantageous to adopt a rigorous anti-diabetic regimen with a view to the complete disappearance of glycosuria. The increased predisposition of diabetics to infective processes, and their diminished power of resistance to pathogenic micro-organisms clearly demonstrate the urgency of very strict asepsis in operations upon diabetics, and especially in extraction of cataract.

A very complete bibliography is appended to this interesting paper.

J. B. L.

Pearce, F. H., Rankine, R., and Ormond, A. W. **Notes on Twenty-eight cases of Mongolian Imbeciles, with special reference to their Ocular Condition.** *British Medical Journal*, July, 23rd, 1910.

Of these cases 20 were males and 8 females. The average age of death in imbeciles of the Mongolian type is computed by the authors to be between 14 years and 15 years. They point out that nearly 100 per cent. of deaths are due to tuberculosis.

Among their mental characteristics are noted: A strongly marked imitative faculty, and a fondness for music. They are inert and apathetic as a rule. They are very affectionate and fond of being noticed.

Among the physical characteristics the most prominent are: The shortness of stature, due to relative shortness of the

extremities. The brachycephalic skull and usually poorly developed occiput. The characteristic facies, broad squat nose, thick lips and usually prominent lower jaw, and interpalpebral fissure sloping up and out. Shortness of and incurving of the little finger. The skin is dry and rough. The voice has a guttural inflection and there is a tendency to "lalling," the patients being unable to pronounce certain consonants properly. The teeth, though not showing any originality in shape, are usually badly formed, loosely set in their sockets and irregular in their position. They are prone to decay. The eruption of the teeth seems to take place at normal periods. The palate is a contracted vault with the sides sloping more steeply in front so that an anterior plateau is formed.

The various characteristics are dealt with in a percentage table.

As regards the ocular conditions it is known that a large number have some eye defect, either squint, nystagmus, ectropion, or defective vision.

In this paper attention is drawn to the frequency with which a definite form of cataract is found. In 19 of the 28 cases lens opacities were present, and in 18 of the number the cataract was of a particular type. This form of cataract is seen fully developed in several of the older patients, and is present in what is probably an earlier and less mature form in some of the others.

Amongst the illustrations is one showing the lens opacities. There is an analytical table of the cases of cataract.

In the least marked varieties the opacities consist of small dots in the cortical portion of the lens deep to the capsule and nearer the anterior than the posterior surface. These dots are best seen by focal illumination. In the mature cases the opacities consist of two layers enclosing a clear nucleus.

The posterior lamella is concave forwards and corresponds with the curve of the posterior surface of the lens. The anterior lamella is much flatter and is situated about midway between the centre of the nucleus and the anterior surface of the lens. The opacities do not reach the equator in any direction. The lamellæ consist of numerous small discrete dots.

The posterior pole of the cataract which appears to correspond with the posterior pole of the lens is often marked by a star-shaped opacity. The anterior pole of the cataract which does not correspond with the anterior pole of the lens often has a similar opacity to mark its position.

The more fully developed cases might be described as lamellar cataract, the slighter as congenital "dot" cataract.

Very young Mongolian idiots do not exhibit this change. The fact that it is better marked in the older cases suggests that it is a late development.

It remains to be seen whether those cases which now have slight opacities will show an increased number of dots at a later date. It is the author's opinion that the cataract is both partial and progressive, and that it is developed as the result of changes taking place in the lens after its formation.

Though the teeth in these cases are defective they are not of the hypoplastic type.

It was impossible to get any reliable record of the visual acuity in these patients.

The ectropion found in many of these cases is due to a superficial contraction of the skin of the lower lid. The skin of the lid is rough glazed and dry. Marginal blepharitis is probably in the first instance the result of infection from the hands which are frequently used to rub the eyes, and is kept up by the ectropion, error of refraction, and dirty habits of the patient. The age of the youngest patient examined was 5 years and the oldest 43 years. The youngest patient showing cataract was 9 years of age. The oldest patient has a well developed cataract of the kind described.

Half of the number of patients examined have the interpalpebral fissure directed upwards and outwards.

J. F. Cunningham.

Hamburger (Berlin). **On the Circulation of the Intraocular Fluid.** *Klinische Monatsblätter für Augenheilkunde*, July, 1910.

In this paper the author, after a preliminary survey of the work of previous researchers, describes some experiments of his own with sulphate of indigo. This substance first used by Chronszcevsky, is the same as that used by Heidenhain in his work on secretion of the kidney. It is soluble up to 2 per cent. in water and insoluble in absolute alcohol. According to the author a satisfactory preparation is only to be obtained from Teuber of Breslau.

The 2 per cent. solution is injected directly into the circulation, 30 to 50 cc. being used for a rabbit of about four pounds

weight. If the aqueous does not immediately show a blue colour after puncture a sufficient quantity has not been injected. At the conclusion of the experiment the eye must be promptly opened and placed in absolute alcohol in order to precipitate the indigo *in situ*.

A typical experiment is as follows: The injection is made either into the ear vein or else the femoral. One eye is left uninjured, the other is punctured immediately the injection has been made. The eyes are enucleated at a stated interval after the last puncture.

(1) Condition of the punctured eye. If this is enucleated a few minutes after the puncture, and this is not to be done unless the aqueous is clearly stained blue, the vessel walls of the ciliary body will be found intensely stained with the reagent. The vessels of the iris are also stained but to a less extent. The longer the interval between puncture and enucleation the more will the stain in the ciliary body have faded, but that in the iris remains comparatively unaltered for a considerable period. In one experiment in which an hour and a half had been allowed to elapse the stain had entirely faded from the ciliary body, and although the iris vessel walls were still faintly stained, the greater part of the stain was precipitated in the substance of the iris, and chiefly in the anterior part of that structure.

2. Condition of the uninjured eye. If a very large dose of the solution is given both the ciliary body and the iris show staining in the vessel walls. It is however possible by careful graduation of the amount of solution used to get the staining confined to the iris. By still further reducing the dose no staining is found in the eye though the kidney vessels still show the colour.

In both eyes the epithelium of Descemet's membrane always stains. The author states in his explanation of this phenomenon that it is not possible to assume that the staining of the vessel walls can be due to the free circulation of the fluid in the vessels, and instances as a comparison the way in which the very vascular glomeruli of the kidneys remain unstained, and points out that this staining can only occur when the vessels allow the fluid to pass through their walls. He gives it as his opinion that in the normal state of the eye the ciliary body has little to do with the formation of the intraocular fluid, but that it is ready to discharge its contents after puncture "like a loaded gun." Hamburger sums up his conclusions as follows:

(1) That as a result of his experiments, and also of those of Ehrlich with fluorescin, it is impossible to demonstrate either microscopically or macroscopically in the living uninjured eye any transudation from the ciliary body, but only from the anterior surface of the iris and that therefore the hypothesis of Leber and his school on the method of the formation of the intraocular fluid falls to the ground.

(2) That this secretion from the anterior surface of the iris is probably, under normal conditions, immeasurably slow.

(3) That the hypothesis of a free circulation from behind the iris is untrue, and that there is really a physiological valve-like closure of the pupil.

(4) That the quantitative value arrived at by Leber's methods for the absorption of intraocular fluid are far too high.

(5) That the chief path of removal from the eye is not Schlemm's canal but the whole vascular network of the iris. The action of eserine on glaucoma is to be explained by the unfolding of the iris and not by the freeing of the angle of the anterior chamber; the reverse action of atropine in raising the pressure being explained in a similar way by the crowding up of the surface of the iris.

(6) That excretion from the eye is not as hitherto believed a physical process of filtration of mathematical regularity but a simpler if much slower process of absorption.

(7) That physiological aqueous is a very different fluid from that secreted after puncture and has little or nothing to do with the activity of the ciliary body.

(8) That the aqueous secreted after puncture comes almost entirely from the ciliary body.

(9) That the energy of the ciliary body is normally almost entirely a potential one, but under what conditions and how frequently this potential energy is converted into a kinetic one is as yet not understood.

Excellent drawings of the microscopic appearances of the experimental eyes accompany the paper, which is well worth reading in full. I am however inclined to think that the author's experimental work is hardly sufficiently strong to upset the previous work of Leber and the numerous researchers who have worked with his methods.

E. E. H.

Konoto J. **Cataract from Electrical Shock.** *Klinische Monatsblätter f. Augenheilkunde.* February, 1910.

The author of this paper is fortunate in having had personal experience of two cases of cataract resulting from electric shock. One of these he has already published in Japan, the second is the subject of his present communication. Electric cataract, he says, must be rare, as down to 1908 he has only traced references to five cases.*

In his own first case, of which he gives a summary, the injury was caused by direct contact of a live wire with the cornea. The cornea itself was injured and there was relatively rapid development of capsular cataract in a position corresponding with that of the corneal lesion. The cataract was removed later by another surgeon with a good result.

His second case is the first in which microscopic examination of the affected lens and capsule has been recorded.

The patient, a workman, aged 28, received a current of 11,000 volts through his body, one terminal being in his left hand and the other in contact with his forehead. He was rendered unconscious and remained so until the following day. When he recovered consciousness he observed some redness of the eyes. Vision began to fail in the left eye six months later, and in the right eye ten months after the accident.

Sixteen months after the accident the left eye was almost blind (V. = hand movements) with total cataract. There were some minute greyish dots on the anterior capsule. Vision in the right eye was still $^{6}/_{20}$ and the lens presented punctate capsular opacities like those in the left. Both lenses were extracted, the anterior capsule in the case of the right eye having first been removed by capsule forceps. The portion of capsule thus removed showed defective staining of the cell nuclei, and an appearance of clefts between the epithelial cells. The lens extracted from the left eye showed small spaces, chiefly round or oval, in the cortex, some of them filled with lightly stained masses. These were most abundant in the anterior cortex and at the equator. They were less abundant in the posterior part of the cortex, and absent from the nucleus.

Komoto concludes with some general remarks on the strength of the current necessary to produce electric cataract, on the date

* The subject has been more recently discussed by Van Liut in his small treatise "Accidents Oculaires provoques par l'Electricité." Brussels, 1909.

of the appearance of the cataract after the injury, on the form of the cataract, and on the symptoms and prognosis.

As regards the pathogenesis he favours the view that the opacity is caused by a katalytic action of the electric current on the capsule epithelium or lens fibres or both.

A. J. Ballantyne.

Rollet. **Treatment of Ptosis by an Open Method of Frontalis Blepharopexy.** *Revue Générale d'Ophtalmologie*, February, 1910.

Yet another ptosis operation. It might be described as a Panas's operation without the lid flaps passing under a bridge of skin.

A 12 mm. long horizontal incision is made on the upper lid about the level of the normal sulcus or midway between the brow and the lid edge. From the outer end of this an incision passes down and out nearly to the lid edge, and from the inner end one passes down and in nearly to the lid edge. All three incisions pass through skin and orbicularis muscle, and this trapezoidal flap is then dissected up. Then a horizontal or slightly arched incision just below the line of the shaved eyebrows is made. This reaches to the bone, cutting skin, muscles and fascia. It is considerably longer than the first incision on the two sketch diagrams which illustrate the article. Next, a vertical incision unites the middles of the two horizontal ones. This begins as superficial below but gets deeper as it passes up to meet the other at the bone.

The two lateral cutaneous folds, namely those between the two horizontal incisions, are dissected up and turned aside so that the lid flap can be pulled up to fill the space. Deep catgut sutures—vertical and horizontal—then unite the orbicularis palpebrarum muscle of this lid flap to the deep frontalis aponeurosis and muscle, which have been brought into better view by the use of retractor—while the skin sutures are of iron wire, or, better, of horsehair, and join the lid flap to the upper lip of the superior horizontal incision. The lateral flaps are cut off where redundant and sutures are applied.

By this open operation it is claimed that an exact myorrhaphy can be made—and a more natural appearance of the lid is obtained while the troublesome features of Panas's operation are avoided altogether. The upper horizontal incision is kept

quite below the follicles of the brows and so any scarring is much less conspicuous.

The author had a good cosmetic result in a boy of nine upon whom he did this operation.

W. C. Souter.

Terrien and Bourdier. **Lesions of the Optic Tracts in Epidemic Cerebro-Spinal Meningitis.** *Archives d'Ophtalmologie*, April, 1910.

Lesions of the optic tract are relatively of great frequence in epidemic cerebro-spinal meningitis. The authors in a previous paper (*Archives d'Ophtalmologie*, 1909, p. 301) described no less than 19 cases of such affections in 42 patients. Other authors have met with even a larger proportion.

The authors in a review of the literature of the subject state that the cases fall into two main groups, those in which actual lesions are found ophthalmoscopically and those in which the lesion is entirely one of function, the latter being attributed by some authors to retrobulbar neuritis and by others to a double cortical lesion.

Terrien and Bourdier succeeded in obtaining the optic nerves up to and including the chiasma together with the posterior parts of the globe from three cases in which the disease proved fatal in the first week and in which the sole sign of affection of the optic tracts, observed clinically, consisted in papillary hyperæmia. In all three cases the affection was most intense at the level of the optic canal.

A careful account is given of the microscopical anatomy of the affected parts and several pages are devoted to the much discussed question of the origin of the peculiar cells found in the space between the arachnoid and pial sheaths.

The authors draw the following conclusions from their observations:—

1. The meningeal infection spreads along the sheath of the optic nerves in the same way and at the same period as on the surface of the brain and spinal cord.

2. It is a local reaction which has been artificially separated from the general process which has involved all the coverings of the cerebro-spinal axis.

3. It begins by an inflammation of the arachnoid and pial sheaths which may go on to resolution or provoke more serious lesions in the parenchyma of the optic tracts.

4. The process which attacks the optic nerves is not a neuritis but a diffuse perineuritis, extending the whole length of the optic tracts and presenting various zones of intensity, the most intense being at the passage of the nerve through the canal. The nerve is generally normal, but in some cases suffers from a secondary interstitial neuritis leading to disappearance of the nerve bundles and optic atrophy.

This secondary development of an interstitial neuritis may explain those cases in which blindness has supervened without any ophthalmoscopic change during the period of convalescence.

The paper is accompanied by micro-photographs and a careful bibliography.

E. E. H.

BOOK NOTICES.

The Extra Pharmocopæia of Martindale and Westcott. 14th edition. Price 12s. net. With supplement, Organic Analysis Chart, by the first author. Price 3s. 6d. net. London, H. K. Lewis, 1910.

Only two years have elapsed since the last edition of this well known work. By altering the shape of the present edition and by the use of thinner paper it has been found possible to include a large quantity of new matter without making the volume at all unwieldy.

The new chapters added deal with lactic acid bacilli, organic acid compounds, ionic medication, and radium. Considerable additions have been found necessary to the chapters on vaccine and organic therapy. These chapters all form admirable epitomes of their respective subjects; they also contain full references to the original papers.

The idea of collecting together all the organic analysis tests and issuing these in a supplement is excellent, and we note that these tests have all been practically applied in Mr. Martindale's own laboratory.

The work of condensation has been admirably performed and there do not appear to be any omissions of importance.

The book is indispensable to every medical man.

HERZOG, Prof. Dr. HANS, (Berlin). **On the Nature and Origin of the Trachoma Organism, and its Apparent Derivation from Neisser's Gonococcus.** Urban and Schwarzenburg, Berlin and Vienna, 1910.

OF the precise value of this monograph of fifty pages only workers in the same field can form a clear idea. But little is yet known of the nature of the new trachoma bodies. The finding of morphologically identical "chlamydozoa" by several observers in blenorrhœa, both conjunctival and genital, has been the first step towards further understanding of these bodies. The typical cell-inclusions have been found mostly alone, but also associated with gonococci, from some of which successful cultures have been grown. Herzog insists upon the fact that apart from trachoma, with few exceptions, the only cases in which the characteristic formations have been found have been of gonorrhœal type. He argues for the bacterial nature of the granules, as against the protozoal.

In August, 1909, he noticed in smears from gonorrhœal conjunctivitis stained by Giemsa's method many gonococci in epithelial cells, closely grouped near the nuclei of the cells, and embedded in plastin masses, exactly as occurs with the trachoma granules. Since then he has worked on the preconceived idea of a close relationship between the gonococcus and the trachoma organism. He claims to have demonstrated in cultures of the gonococcus an involution form which he terms the micro-gonococcus, considerably reduced in size, measuring not more than $0{\cdot}2\,\mu$, rounded in shape, colouring with Giemsa's stain like the trachoma body, closely grooped in zooglœa mass, and showing dumb-bell forms. Thus the reproduction of the known characteristics of the trachoma body appears complete. (The observation of the dumb-bell form of the trachoma body has been considered to indicate a close relationship with protozoa).

Herzog has two very interesting clinical observations in support of his thesis. He reports an early case of trachoma showing, together with an unusual number of typical cell-inclusions, many cells containing paired organisms shaped and coloured (with Giemsa) exactly like gonococci, but smaller than usual. He regards them as possibly transition forms. Many of them were grouped at one side of the nucleus, embedded in plastin, like trachoma organisms. Others were scattered in pairs, in small clear spaces, in the protoplasm of the cell. The failure to grow gonococci from the case is attributed to defect in the culture medium. The second case was more remarkable.

It was a case of acute conjunctival blenorrhœa, showing at first only typical gonococci in profusion. After energetic treatment of the case for six days gonococci were found only in leucocytes, and not at all in epithelial cells. After another six days the gonococci had disappeared altogether, but numerous cell-inclusions were now for the first time found, exactly like typical trachoma bodies. Four weeks later the microscopical findings were negative, and the conjunctiva was almost normal in appearance. Herzog is firmly convinced that the trachoma organism is a special modification, a derivative of Neisser's gonococcus.

H. Herbert.

Heilborn. **The Importance of Eye Hygiene for the State with especial reference to the question of Defence.** S. Karger, Berlin, 1910.

Dr. Heilborn's book is written partly for the profession, and partly for the laity, and with this double object in view, he has succeeded admirably in giving a thoroughly useful and trustworthy account of myopia, and the means which we have at our disposal at present to control this disease.

The book is evidently the outcome of one man's very extensive experience.

For the purposes of review it will be best to carefully extract the last six pages of the book in which the author groups together the results of his examinations, and the opinions he has formulated on those results. Heilborn's cases number 11,000, and he classifies myopia into the three following groups:

(1) Functional myopia (school and work myopia) without congenital disposition.
(2) Functional myopia, with congenital disposition.
(3) Pernicious myopia.

The foundation of a successful control of myopia is the obligatory surveillance with full correction of myopes from the sixth to the twentieth year. This surveillance should fall upon the state, it would be easy to carry out, and the cost would not be excessive.

The public should be warned of the ultimate dangers of myopia, and of the necessity of having their glasses ordered by a physician.

It is wrong to say that school work is responsible altogether for the development of myopia: there is a pre-school myopia, a school myopia, and a post-school myopia, and the question of dwelling house is all important also.

The children of myopic parents should be examined during the first years of life.

In the control of school myopia the appointment of school ophthalmic surgeons is necessary, and an examination of the eyes of all scholars is to be obligatory.

Special classes should be held for sufferers from pernicious myopia, and Berlitz is recommended.

A myope should seek advice from an ophthalmic surgeon before choosing his profession.

In ability for military duty the following three points are to be determined:—

(1) The kind of myopia.
(2) The vision.
(3) The degree of myopia.

Heilborn recommends that the myopic limit for military duty be extended to $-8{\cdot}5$ D, if the vision with glasses is normal.

Opticians ought not to be allowed to prescribe concave glasses off their own bat.

School and military doctors should be thoroughly up in the diagnosis of trachoma.

Employers of labour should see that their labourers be provided with protective glasses, if indicated by the nature of their employment, and should be liable to be fined if they neglect this precaution: any workman obstinately refusing to wear such protective glasses should be dismissed.

Builders' labourers should have some instruction given them about the immediate treatment of injuries by lime.

In septic injuries, and especially in cases of ulcus serpens, Heilborn warmly advocates treatment with pyocyanese. The author raises numerous other points which need not be gone into here; the book itself is extremely instructive.

R. R. James.

THE OPERATIVE TREATMENT OF HIGH MYOPIA.*

By A. Hugh Thompson, M.D., B.C. (Cantab.).
Surgeon to the Western Ophthalmic Hospital, London.

1. Degree of Myopia Suitable for Operation.

When we have removed a cataractous lens from an eye previously emmetropic, we usually find that the patient takes a +12 glass for distant vision. If, however in a patient with 12 Dioptres of Myopia we were to remove the lens in the expectation of making him emmetropic we should make a great mistake. He would probably be hypermetropic to the extent of 4 or 5 D afterwards. One reason of this is that in a myopic eye the distance from the lens to the retina is greater than in an emmetropic eye and the greater this distance is, the greater the effect on the total refraction of removing the lens. Another is that the concave glass which corrects a patient's myopia is placed at a greater distance from his retina than the convex glass which corrects the hypermetropia of a patient who has had his lens removed for cataract, and the further off from the retina that a concave glass is placed the less is its effect in altering the refraction. For these two reasons the effect of removing the lens from a highly myopic eye is always much greater than 12 Dioptres. The actual amount of alteration in any particular case it is not possible to predict with any certainty, but from a survey of 22 eyes on which I have operated after taking careful notes of the refraction, 7 of them myopic primarily, 5 of them with cataract complicated with myopia, and who when first seen had the lenses sufficiently transparent for a

* A paper read at the Annual Meeting of the British Medical Association, 1910.

fairly accurate retinoscopy, I conclude that the average refraction in myopia after removal of the lens is half the previous myopia plus a figure which varies between 9 and 13 but which on the average is 10·5. Thus the degree of myopia which on the average may be expected to become emmetropia is −21 D, for $\frac{-21}{2} + 10{\cdot}5 =$ zero. We may, however, get emmetropia after needling the lens in myopia as low as −18 or as high as −26, and it must be remembered that in young patients where the myopia is increasing year by year, if we leave a previously myopic eye in a condition to need a low plus glass for distance it will tend to become emmetropic. Further, the divergence from myopia which may be expected after needling a myope of say −16 D is not the difference between 16 and 21 but only half this or +2·5 D. On the whole I think we may regard −16 D as a reasonable limit higher than which it is justifiable to operate, in cases otherwise suitable.

TABLE I. ALTERATION OF REFRACTION.

Myopia uncomplicated.	Before operation.	Afterwards.	Formula.
Berkshire	−18	+4	$\frac{M}{2} + 13$
Luck	−22	−1·5	$\frac{M}{2} + 9{\cdot}5$
Elston	−17	+1·5	$\frac{M}{2} + 10$
Mills	−16	+3	$\frac{M}{2} + 11$
Arken	−16·5	+1·25	$\frac{M}{2} + 9$
Bush, L.	−16·5	+1	$\frac{M}{2} + 9{\cdot}25$
Bush, R.	−14·5	+3·5	$\frac{M}{2} + 10{\cdot}75$
Hunt	−17·5	+1·5	$\frac{M}{2} + 9{\cdot}75$

Myopia uncomplicated.	Before operation.	Afterwards.	Formula.
Smith	−14	+2·5	$\frac{M}{2}+9·5$
Cheesman	−16	+3	$\frac{M}{2}+11$
Ball	−20	+3	$\frac{M}{2}+13$
Phillips	−19	+2·75	$\frac{M}{2}+11·25$
Egan	−18	+0·5	$\frac{M}{2}+9·5$
Taylor	−16	+1·5	$\frac{M}{2}+9·5$
Jaggard	−18	Em	$\frac{M}{2}+9$
Francis	−16	+2	$\frac{M}{2}+10$
Whitmore	−20	+0·5	$\frac{M}{2}+10·5$
Myopia with senile cataract.			
Heath	−17	+2·5	$\frac{M}{2}+11$
Ball	−9	+5	$\frac{M}{2}+9·5$
Fisher	−10	+6·5	$\frac{M}{2}+11·5$
Myopia with Lamellar cataract.			
Marks, R.	−6·75	+9	$\frac{M}{2}+12·25$
Marks, L.	−7·5	+8	$\frac{M}{2}+11·75$

Average formula for 22 eyes $\frac{M}{2}+10·5$

In cases of astigmatism the refraction given is the mean between that of the two meridia.

2. Age.

Of 19 patients on whom I have operated the youngest was 6, the oldest 25. Of 40 patients operated on by Mr. Lang at Moorfields between 1896 and 1901, during part of which time I was his clinical assistant, the youngest was only 3 years old, while there were only 3 of the 40 patients over 30. It is seldom advisable to operate beyond this age for two reasons, first that the lens matter does not absorb so readily after needling and we are more likely to have to extract with a possible loss of vitreous; secondly, that the myopia is far more likely to be complicated by advanced choroiditis or macular degeneration, conditions which are distinct contra-indications to the operation. The very young patients on the other hand usually do well. Mr. Lang's little patient of 3 had myopia of -16 D in 1898, and last year, 1909, he informs me he saw him again and found him with vision of $^{6}/_{12}$ in the operated eye with hypermetropia of $+1{\cdot}5$ D. In the unoperated eye the myopia had grown to -20 D. He was then 14 years old. Of my own cases the two little girls of 6 on whom I have operated have both done well. One of them is now 16 years old and uses her operated eye for all purposes. She has, however, macular changes 10 years after operation and visible in both eyes, so that while she at present sees $^{6}/_{18}$ her prospects for the future are doubtful. The macular changes, however, since they are present in both operated and unoperated eyes, cannot possibly be put down to the operation.

3. Growth of the Long Axis of the Eye after Operation.

In seven of my cases I have been able to make a comparison between the rate of growth in the long axis of the eye operated on and that of the fellow eye which

was not operated on. It must be remembered that the effect on the total refraction of growth in the long axis of an aphakic eye is only about half what it would be if the lens were intact. Hence on the supposition that removal of the lens has no effect one way or the other in altering the rate of growth in the long axis of the eye operated on, and that both eyes continue to be equally subject to this tendency, we should expect to find an increase in myopia or a diminution in hypermetropia in the aphakic eye just about half as much, measured in dioptres as the increase in myopia in the non-operated eye which took place in the same period. Roughly speaking this is just about what we do find, so that we may agree with previous investigators who have concluded that in itself the operation has no effect either one way or the other in either hastening or delaying the tendency of the axis of the eye to increase in length though this tendency has only about half the effect on refraction in the case of an aphakic eye to what it has in the case of an eye with the lens intact.

4. State of the Fundus.

In myopic eyes, a crescent, however large, so long as its margin is well defined, is no evidence of a tendency to choroiditis. An irregularly defined crescent, on the other hand, or irregular areas of choroidal atrophy outside the crescent, or any definite changes at the macula do show a tendency to disease, and so do vitreous opacities. These ought in my opinion to be contra-indications to operation although not necessarily absolute ones in cases where the changes are only slight. To operate on an eye which is very likely to go to the bad anyhow is certainly unwise, however, and it is quite possible that when an eye is in this condition the influence of operative procedures may hasten the tendency. A great many of the published cases in which detachment of the retina has occurred have been cases

TABLE II. GROWTH OF LONG AXIS OF EYEBALL.

			Rate per year				Rate per year
Berkshire.							
Operated eye	after operation	+5 D		Second eye	at time of operation	−18·5 D	
,,	9 years later	+0·5 D	0·5D	,,	9 years later	−24·5 D	0·66 D
Luck.							
,,	after operation	−2 D		,,	before operation	−19·5 D	
,,	5 years later	−3·5 D	0·3 D	,,	6 years later	−20·5 D	0·16 D
Elston.							
,,	after operation	+1·75 D		,,	before operation	−17 D	
,,	4 years later	emmetropic	0·4 D	,,	5 years later	−22 D	1·0 D
Mills.							
,,	after operation	+3·0 D		,,	before operation	−15 D	
,,	2½ years later	+2·0 D	0·4 D	,,	6 years later	−18 D	0·5 D
Arken.							
,,	after operation	+1·25 D		,,	before operation	−13·5 D	
,,	2 years later	emmetropic	0·6 D	,,	4½ years later	−16·5 D	0·66 D
Taylor.							
,,	after operation	+1·5 D		,,	after operation	− 9 D	
,,	1½ years later	+1·5 D	0 D	,,	1½ years later	− 9 D	0 D
Ball.							
,,	after operation	+3 D		,,	time of operation	−15 D	
,,	2 years later	+3 D	0 D	,,	2 years later	−19 D	2·0 D

Average for operated eye 0·31 D. Average for second eye 0·74 D.

with unhealthy fundi or vitreous opacities. On the other hand I do not think there is any evidence to show that the operation tends to cause choroiditis or macular disease in eyes which have previously been free from them. Highly myopic eyes can never be considered to be free from these dangers, but as far as my own experience goes it tends to show that in itself the operation has no influence one way or the other either in inducing or in preventing them. The following cases may be cited in this connection. Their number is of course far too small to draw any final argument from, but in as much as my own conclusion coincides with that of previous writers on the subject I think them worth recording.

Berkshire. Right lens needled, æt. 6, both maculæ then being healthy. Æt. 16, macular changes in both eyes but vision of operated eye still good.

Arken. Æt. 25. Left lens needled, both maculæ being healthy. Æt. 29. Slight macular change in right (unoperated) eye but vision for near in this eye still good.

Cheesman. Left lens needled, æt. 9, both maculæ being healthy. Æt. 12, both maculæ remain healthy. The mother of this patient æt. 41, is herself a high myope and has an advanced degree of macular choroiditis in both eyes.

Taylor. Left lens needled, æt. 22, and good vision resulted. Eight months later a macular hæmorrhage occurred in the operated eye making vision very bad. It subsequently, however, improved to $^{6}/_{18}$.

This last case may be put against that of Arken in which the macular change occurred in the unoperated eye. In Berkshire it occurred in both, and in Cheesman in neither in spite of an hereditary tendency, so that taking the four cases together the influence of the operation appears to be nil.

5. Condition of the Second Eye.

In most cases of high myopia the two eyes are approximately equal, and it is generally wisest to choose the one in which the myopia is highest for operation. In two of my cases the myopia was very unequal, the myopia in the second eye being in one case −11·5 against −20, and in the other −4·5 against −17·5. In this sort of case the patient appreciates the benefit he gets from the operation provided that it enables him to see fairly well at a distance with the operated eye without any glass, even though the vision of the second eye with a glass may be somewhat better. In cases on the other hand where the second eye is emmetropic or nearly so, there is really nothing to be gained from operation at all. Further, in cases where the fundus of the second eye is seriously diseased, and more especially if there is a detachment of the retina, the chances of both eyes behaving in the same way are so great that I do not think that an operation ought to be performed without very special reasons indeed.

6. Operative Procedure.

There are three possible methods of dealing operatively with the lens in young myopes:—

1. Repeated small needlings, until the whole of the lens matter is absorbed. This is a tedious method as the number of needlings may have to be considerable and the duration of the treatment correspondingly prolonged.

2. One free needling calculated to cause rapid imbibition of aqueous by the lens and consequent swelling of the lens matter. If this method is adopted it is in almost but not quite all cases necessary to perform a second operation in from 3 to 10 days' time to evacuate the lens matter artificially. This is the method that I have adopted in all but one of my cases. In many cases, when the whole remaining lens matter is absorbed, there is a partially opaque posterior capsule left which requires needling.

3. The third method is linear extraction of the lens without a preliminary needling at all. To my mind the great objection to this procedure is the danger of vitreous loss. I have only adopted it in one case when there was congenital dislocation of the lens and where I found it impossible to needle the lens effectually. I did in fact lose a little vitreous in this case, but fortunately no detachment of the retina has followed.

The following table (III.) shows the number of opera-

TABLE III. OPERATIVE PROCEDURES.

	Needling.	Evacuation.	Adhesions.	Capsule.	Late membrane.	Total.
Burnett	2	1	—	2	—	5
Berkshire	1	1	1	—	1	4
Luck	1	1	—	—	—	2
Elston	1	2	—	—	1	4
Mills	1	1	—	1	—	3
Arken	2	—	—	—	—	2
Bush (L. eye)	3	1	2	—	1	7
Bush (R. eye)	1	2	—	—	1	4
Hunt	1	1	—	—	—	2
Smith	1	1	—	1	—	3
Cheesman	3	—	—	—	—	3
Egan	1	1	—	1	1	4
Taylor	1	1	—	1	—	3
Ball	1	1	—	1	—	3
Newton	2	—	—	—	—	2
Francis	1	—	—	1	—	2
Jaggard	1	1	—	1	—	3
Phillips	1	1	—	1	—	3
Petty	2	extraction	—	—	—	3
Whitmore	1	2	—	—	—	3
						65
				Average		3·25

tions in my own cases. It will be seen I have had to repeat the primary needling in 6 cases. In 4 cases I have been able to dispense with the artificial evacuation, but on the other hand in 3 cases I have had to repeat it a second time. In two cases there has been adhesion of lens matter to the scar of the evacuation incision in the cornea and these have required division. In 8 cases it was necessary to do a needling of the posterior capsule before the patient had good sight, and in 5 cases after the lapse of a year or two during which the patient enjoyed good sight a secondary membrane formed which again required needling. These were, in all but one instance, cases in which there had previously not been a needling of the posterior capsule.

Altogether the average number of operations necessary in this treatment works out at 3·25 per eye operated on.

7. Visual Results.

Table IV. shows that of my 20 eyes the result of operation has been, so far as I have been able to follow them up, to improve the distant vision in all but 3 cases. Of these 3, one, Burnett, was a case which I should not now consider suitable for operation because there were macular changes in both eyes to start with. It was, moreover, my first case; every operation was followed by cyclitis, and the best attainable vision which before operation had been $^{2}/_{60}$ was reduced to hand-movements afterwards. Another case—Mills—was a success at first. Three years after operation the corrected vision was $^{6}/_{12}$ and Jaeger 1, and it was not until 5 years after operation that the sight of the eye failed. I discovered the cause to be a thick crop of "K.P." which may or may not have had something to do with the operation 5 years before. The Field is defective down and in, so that there is in all probability a detachment of the retina. The third case (Taylor) when last seen saw nearly but not quite as well as she had done with the myopia

Table IV. Vision After Operation.

	Year of operation.	Sex.	Eye.	Age.	Corrected vision before operation.	First year.	Latest note: Without glass.	Latest note: With glass.	For near uses: operated eye.	For near uses: unoperated eye.	Remarks.
Burnett ...	1899	F.	L.	24	$\frac{2}{60}$	Hand Movements.	—	—	—	—	Cyclitic membrane.
Berkshire...	1900	F.	R.	6	$\frac{6}{60}$	$\frac{6}{60} + 4\frac{6}{36}$	1910 $\frac{6}{18}$	—	1	—	Macular changes in both eyes.
Luck	1903	F.	R.	17	$\frac{6}{36}$ 1l.	$\frac{6}{36}\ \frac{-1\cdot0}{-1\cdot0}$ cyl. 1 $\frac{6}{12}$	1909 $\frac{6}{60}$	$\frac{-3\cdot0}{-1\cdot0}$ cyl. 1 $\frac{6}{18}$	1		—
Elston	1904	F.	R.	17	$\frac{6}{18}$	$\frac{6}{24} + 1\cdot5\ \frac{6}{18}$	1909 $\frac{6}{12}$	—	—	1	—
Mills	1904	F.	L.	12	$\frac{6}{36}$	$\frac{6}{24} + 3\cdot0\ \frac{6}{18}$	1910	Hand movements	—	—	—
Arken	1904	F.	L.	25	$\frac{6}{24}$	$\frac{6}{18} + 2\cdot5$ cyl. $- \frac{6}{12}$	1908 $\frac{6}{12}$	—	—	1	—
Bush	1904	F.	L.	16	$\frac{9}{18}$ 2l.	$\frac{6}{18}$	1910 $\frac{6}{24} + 1\cdot0$ cyl. $- \frac{6}{18}$		1	—	Used Left for near before Right was operated on.
"	1907	—	R.	19	$\frac{6}{24}$	$\frac{6}{36} + 3\cdot5\ \frac{6}{12}$	—	$\frac{6}{24} + 3\cdot0\ \frac{6}{12}$	—	—	
Hunt	1905	F.	L.	15	$\frac{6}{60}$	$\frac{6}{36} + 1\cdot5\ \frac{6}{18}$	—	—	—	1	—
Smith	1906	F.	R.	19	$\frac{6}{18}$	$\frac{6}{60} + 2\cdot5\ \frac{6}{18}$	—	—	—	1	—
Cheesman..	1906	F.	L.	9	$\frac{6}{36}$	$\frac{6}{36}$	1908	$+ 3\cdot0\ \frac{6}{12}$	1	—	—
Egan	1907	F.	R.	23	$\frac{6}{36}$ 1l.	$\frac{6}{36}$	1909 $\frac{6}{36}$	—	—	—	Corneal nebulæ.
Taylor	1907	F.	L.	22	$\frac{6}{18}$	$\frac{6}{12} + 1\cdot5\ \frac{6}{9}$	1909 $\frac{6}{24} + 1\cdot5\ \frac{6}{18}$		—	1	Macular hæmorrhage which has disappeared.
Ball	1907	M.	R.	18	$\frac{6}{18}$ 1l.	$\frac{6}{36} + 3\cdot0\ \frac{6}{18}$ 1l.	1909 $\frac{6}{24} + 3\cdot0\ \frac{6}{18}$		—	1	—
Newton ...	1908	F.	R.	18	$\frac{3}{60}$	$\frac{6}{60}$	—	—	—	1	Corneal nebulæ, old Int. Keratitis.
Francis ...	1908	F.	L.	6	—	Counts letters of $\frac{6}{6}$	1910 $\frac{6}{60} + \frac{1\cdot5}{+4\cdot0}$ cyl. 1		—	—	
Jaggard ...	1908	F.	R.	21	$\frac{6}{24}$	$\frac{6}{24}$	—	—	—	—	—
Phillips ...	1908	F.	R.	17	$\frac{9}{18}$	$\frac{6}{36} + 2\cdot5\ \frac{6}{18}$	—	—	—	—	—
Petty	1909	F.	R.	13	$\frac{6}{24}$	$\frac{+5\cdot5}{+1\cdot7}$ cyl. 1 $\frac{6}{12}$	—	—	1	—	Congen. dislocation both lenses.
Whitmore..	1910	M.	R.	22	$\frac{6}{60}$	$\frac{6}{18}$	—	—	—	1	—

corrected before operation. For a time she had seen much better, $^{6}/_{9}$ and Jaeger 1, but 8 months after the primary needling she had a macular hæmorrhage which reduced her vision very much for a time. I have already referred to this case in another section of my paper.

Of the remaining 17 eyes operated on, on the last occasion on which they were seen—in 10 cases the distant vision without a glass was either equal to or better than what it had previously been with a correcting glass; in the remaining 7 it was equal or better with the help of a low plus glass,—in some cases very considerably better. In all these cases the patients themselves have been pleased with the result.

With regard to near vision, I have found that in 5 cases the patients preferred to use their operated eye for all purposes with or without a glass; in 8 cases, however, the patient preferred to use the unoperated eye for near work. This is a point which must be borne in mind if it is ever a question of operating on the second eye.

8. Question of Operating on the Second Eye.

In any case this should certainly be deferred for two years after completing the operation on the first, and if the second eye is useful for near work it should of course be left as it is. I have myself only operated on the second eye in one case, and I should not do so again without very strong reasons because on the whole, even in well selected cases there must be a certain amount of risk attached to the operation. Though from the patient's point of view it may be well worth while to undergo this for the first eye for the sake of the great improvement of vision which may fairly be expected, in the case of the second eye, if the first eye has done well the further improvement to be expected can only be comparatively slight; if it has done badly it is *prima facie* evidence that the risk attending operation on the second eye is greater than usual. A case has been recorded of

double detachment of the retina after double operation for myopia.

9. Possible Causes of Failure.

Cases may do badly either as the direct result of the operative procedure, or from causes entirely unconnected with it. The first class of failure includes: (1) cases of infection. Hypopyon or even panophthalmitis may follow from this as from other operations on the eye-ball. (2) Secondary glaucoma either from failure to let out the lens matter soon enough after a needling or at a later period from causes which are obscure. (3) Cyclitis leading to a thick cyclitic membrane as in my first case.

The second class of failures includes eyes that go wrong in consequence of macular degeneration, extensive choroiditis or hæmorrhages. These are incidents liable to occur in these highly myopic eyes at any time and do not appear to be more frequent in eyes that have been operated on than in eyes that have not.

There is still one cause of failure which is so important that I will treat it separately; I mean Detachment of the Retina. This is also an incident in the course of high myopia, and a certain number of cases which have occurred after operation would have happened to the same eyes even if no operation had been performed. Whether my own case occurring 5 years after operation comes into this category I cannot say. What proportion of eyes with myopia of −14 D or over ever get detachment of the Retina is entirely unknown. Hippel found 53 out of 842 eyes with myopia of presumably this amount or 6·3 per cent. with detached retina, and compares this percentage with 25 cases found in 263 operated eyes or 9·5 per cent., but the figures do not appear to be comparable because the percentage in each case must depend very largely on the length of period during which the patients were followed up. If a large number of high myopes were followed up during their whole lives

the proportion of them who suffer from detachment would probably prove to be considerably more than 6·3 per cent. A better way of getting at the truth appears to me to be to watch a large number of cases of myopia that have been operated on and compare the number of detachments that are noted as having taken place during the first year after operation with those that take place in subsequent years.

In a series of 11 detachments found after operation at Giessen[1] 4 took place in the first year after operation and not more than 1 in any subsequent year. Similarly, analyzing some figures giving statistics of operations at Leipzig,[2] comparing the number of detachments after operation found during any year with the number of operated eyes remaining under observation during that year I found that in the first year 7 detachments out of 338 makes the proportion 1 :48. In the second year 3 out of 263 makes the proportion 1 :87, or not much more than half, and the same proportion holds for succeeding years. This, I think is positive evidence that the operation does predispose to detachment during the first year and negative evidence that it does not do so to any appreciable extent after the termination of the first year.

How far can the danger be averted by a careful selection of cases and by a suitable method of operating? From the published cases it can be shown that cases with vitreous opacities or choroiditis do not do so well as those with healthy fundi. Six out of 11 of the Giessen cases of detachment had vitreous opacities before operation. As to the second point, in reading the published accounts of cases in which detachment has occurred I find a loss of vitreous noted in an unduly large proportion. Of the Giessen cases there were 5 in which detachment occurred during the first year. In 3 of these there had been loss of vitreous. At Leipzig there were 7 cases in which the

1. Imai reviewed in *Ophthalmic Review* for 1909, p 228.
2. Hoppner reviewed in *Ophthalmic Review* for 1909, p. 228.

same accident occurred during the first year. In 3 of these also, vitreous was lost at the operation, so that out of these 12 cases vitreous was lost in 6, or just one half. I think we ought to recognize that in highly myopic eyes a loss of vitreous at an operation definitely increases the chances of a subsequent detachment. For this reason I think that in most cases it is very undesirable to attempt to remove the whole lens at once by a linear extraction, and that in evacuating the lens matter after a needling we should be content with getting as much away as will come easily, leaving the rest to be absorbed, or if necessary evacuated again should the tension rise.

A CASE OF HEMIANOPIA.

By R. R. James, F.R.C.S.

Assistant Ophthalmic Surgeon to St. George's Hospital.

Hemianopia occurring as an isolated complication of head injury is of great rarity, and this fact has induced me to publish the notes of a case of homonymous hemianopia which I first saw on September 11th, 1909, and which appears to me to have a great deal in favour of its having been caused by the injury, although of course I cannot adduce any positive proof that such is the case, as the patient is still alive.

The question of head injury as a cause for hemianopia either as an isolated phenomenon, or combined with evidence of injury to other structures at the base of the skull is one which is almost entirely neglected by such of the English and American text-books of ophthalmology which I have had the opportunity of consulting, while only very scanty reference indeed is made in text-books of neurology to this subject. English works on

general surgery neglect it in like manner, and even the classical article on "Injuries to the Head" by the late Sir Prescott Hewitt in Holmes and Hulke's "System of Surgery," than which, I suppose, no better account of



head injuries has ever yet been written, makes no mention of hemianopia.

My case is as follows:—

A healthy looking female, aged 58, came to my out-patient department on the date mentioned complaining that since an accident which she had received two months

earlier in the year, she had experienced difficulty in seeing things situated on her right-hand side. This trouble was apparently first noticed when she began to get about again after her injury.

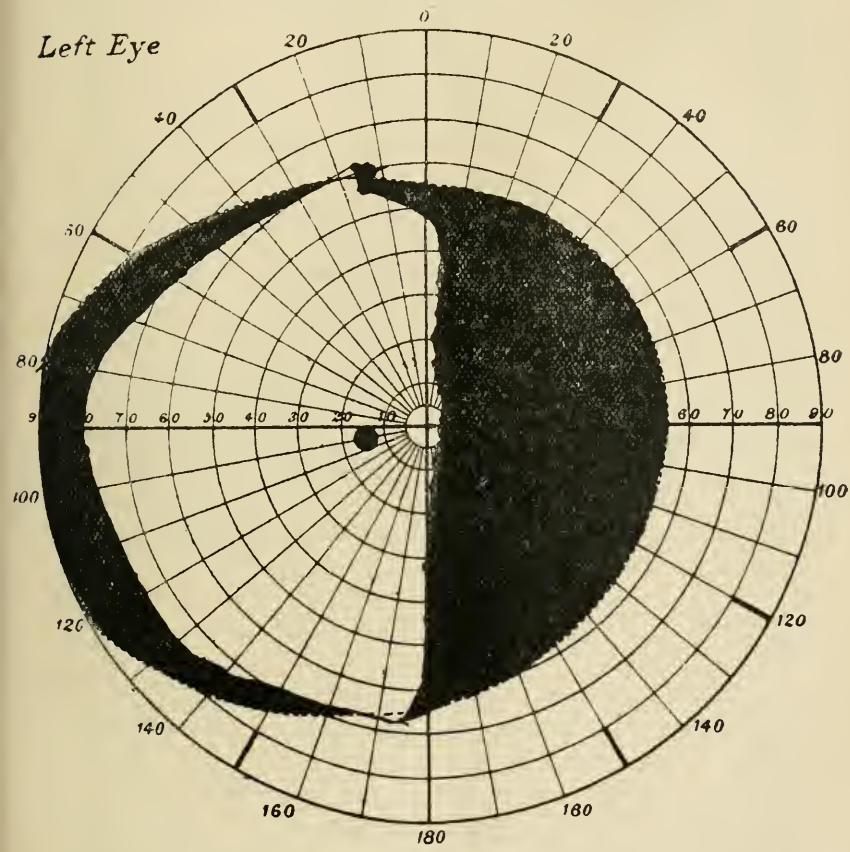

The history of the accident was as follows:—a tram collided with an omnibus, and the latter was upset, the passengers on the roof being thrown into the road, my patient alighting on her right hand and right side of the head; she was taken to one of the larger hospitals, and detained for some time in the receiving room, while her

cut head was sewn up, and her Colles' fracture of the right forearm put up on the usual splints. She was then sent home in a cab. Feeling sick while in the cab she asked her friends to call in her own doctor when they reached home, and on this gentleman's arrival, he found the patient unconscious. He advised her removal to the Westminster Hospital, where she was admitted suffering from fractured base, with bleeding from the nose and right ear, and considerable ecchymosis round the right eye. She lay unconscious in hospital for five days and then slowly recovered. She attended my out-patient department on September 11th, as the Westminster Hospital department was closed for repairs.

When I first saw the patient, I found a healthy looking woman, whose eyes were rather prominent; she had a freshly healed wound about 1 inch in length over the external angular process of the frontal bone on the right side, extending inwards above the right eyebrow, the skin was quite supple and was not attached to the bone beneath. I made a note that the left pupil was a shade larger than the right, that the pupil reactions and the intraocular tension were normal.

$$\frac{\text{R.V. } \frac{6}{6} \text{ Hm. } 0{\cdot}5}{\text{L.V. } \frac{6}{6} \text{ Hm. } 0{\cdot}5} + 3{\cdot}5 \text{ sph.} = \text{Sn. } 0{\cdot}4 \text{ very slowly, fundus normal}$$

Right-sided homonymous hemianopia, the division line avoiding the macula, as shewn in the accompanying fields. Wernické's reaction not present.

Slight general contraction of the field on both sides.

Dr. Golla kindly examined her general condition for me, and reported that he could find nothing else the matter with her, and that her blood pressure was not unduly high.

I saw the patient occasionally during the next few months, and examined her carefully again on September 30th, 1910. Her condition presented no change, the fields were unaltered; the fundus normal. She was able

to divide straight lines with very fair accuracy, not making the mistake described by Liepmann, of making the half lying on the side of the retained field too large.

Scattered through the English journals are one or two references to cases which have some bearing on the subject in hand, and I have given at the end of this paper references to such descriptions as I have been able to unearth. References to thirty-one cases of hemianopia following on head injury are to be found in Wilbrand and Saenger's "Neurologie des Auges," vol. iii, part 2, in that part of the volume entitled "Plötzliche erblindung nach traumen." Of these cases seven are examples of crossed hemianopia, while the remaining are homonymous. In every case the injury has been either a fissured fracture or a depressed fracture of some part of the vault, frequently situated in the occipital or parieto-occipital region, or else a fractured base. In two cases the hemianopia was transitory, but the majority are examples of very severe head injury, many of them compound depressed fractures exposing brain substance, with subsequent hernia cerebri, intra-cerebral or intra-cranial abscess formation, and in one case was found post mortem three years later a blood cyst in the arachnoid space at the posterior pole of the skull. Most of the cases were complicated by evidence of injury to some other structure at the base of the skull, such as loss of smell, deafness, or oculo-motor palsy, or abduceus paralysis.

In my own case the injury must have affected some part of the optical fibres behind the corpora quadrigemina, and most likely I think the occipital lobe itself, for one knows how often in fractured skull that part of the brain immediately opposite the seat of fracture, shows hæmorrhages and lacerations.

As I have said, it is impossible to prove with certainty that the hemianopia was due to the accident, it may have been a coincidence, or it may have been an example

of "cause and effect." My own opinion is that we ought to give the accident the benefit of the doubt.

REFERENCE.

Hartridge. Westminster Hospital Reports, vol. 12.
Harman. *Lancet*, May 16th, 1903.
Wilbrand and Saenger. *Neurologie des Auges*, vol. iii, part 2.

MINERS' NYSTAGMUS AND FORMIC ACID.

By DR. M. OHLEMANN.
Late Medical Officer of Health, Wiesbaden.

IN the August number of the *Ophthalmic Review*, p. 229, Dr. A. S. Percival published some observations on the treatment of miners' nystagmus by formic acid; he prescribed this drug in consequence of its employment in the treatment of paralysis agitans and kindred disorders. He reports encouraging results even in patients who continued their work underground; in one case in which nystagmus had prevented work for 18 months, treatment by formic acid led to rapid improvement so that in 3 weeks the nystagmus was elicited only on looking upwards.

I should like to add some observations on this subject, from my experience in the mining districts of Bothum, Westphalia. In this region the number of cases of nystagmus, among miners, is very large; fresh cases are seen almost every day. I chose 12 cases; three who had suffered from nystagmus for more than 2 years, three less than 2 years, the others of recent origin. All the men were off work, and I treated them all with formic acid, in doses similar to those mentioned by Dr. Percival, for a period of three weeks. This treatment was entirely unsuccessful in every instance. One patient alone said he thought his eyes were better, but my belief is that the

improvement was due to the rest he had had; his case was the most recent. In all cases in which improvement occurs, underground work is given up, the patients have a complete rest, and afterwards are employed in work above ground.

In examining patients in this stage (after a complete cessation of mining work) the nystagmus may not be noticeable except when the eyes are directed upwards, and sometimes only in a darkened room.

After a rest of varying duration depending on the length of time the disease has been present, the age and strength of the patient, and perhaps his habits as to alcohol and tobacco, some patients are able to resume work underground. Generally, however, a return to work in the mine is followed by a relapse of the disease. I have also tried treatment by strychnia but without success. My belief is that no drug has yet been shown to be capable of curing the condition, and that rest is the real cause of the improvement noted in many cases.

REVIEWS.

BRIBACH, E. **On the Central Canal of the Vitreous.** *v. Graefe's Archiv f. Ophthalmologie*, vol. LXXVI., pt. 1.

Two methods have hitherto been described, by which the existence of the central canal of the vitreous may be demonstrated. Stilling removes the vitreous and lens intact from the eyeball, places them in a porcelain dish, incises the anterior capsule of the lens and removes the latter. Water is then placed in the dish and the vitreous turned over so that its retinal surface projects above the level of the water. If a drop of a carmine solution is now placed on the exposed surface of the vitreous it runs into the vitreous canal either spontaneously or after a little manipulation of the organ. Wolfrum's method is to bisect the eyeball in the equator or in a plane parallel to it, and to drop a blue aniline solution upon the cut surface. Stilling, in his investigation of thousands of eyes of the ox, pig, sheep, horse and man, found that a central canal could always be demonstrated except when a persistent hyaloid artery was

present. His results were confirmed by Schaff. Wolfrum found the canal in a much smaller percentage of cases and concludes that its presence is not a constant occurrence in fully developed eyes. He thinks that the technique of Stilling's method of preparation produces an apparent canal by stretching and separating the axial fibres of the vitreous.

Bribach has investigated 250 eyes of the pig, ox and sheep, as well as a few human eyes, by a method which he thinks is less open to the suspicion of producing artefacts than those already described. Preparation of the eyeball is carried out in physiological salt solution. The sclera is carefully divided by a circular incision round the equator. The posterior portion of the sclera is then removed with the exception of a ring 4 mm. broad round the optic nerve entrance. The choroid is next removed over the same extent, without disturbing the retina. The author now cuts off, by a single snip of the scissors, the optic nerve entrance along with the attached piece of choroid, thus detaching them, with as little disturbance as possible, from the retina and vitreous. The solution in the vessel is now reduced until the posterior pole of the preparation just projects above its surface, and some hæmatoxylin solution is dropped on to it from a pipette. As a rule the stain runs at once into the canal as far as the posterior lens capsule on its nasal side. If this does not occur a little to and fro movement of the vessel, or dropping water on the peripheral part of the vitreous, will at once produce the effect. By tilting the vitreous on one side the coloured fluid can be readily run out of the canal again. The canal filled itself in this way as far forward as the posterior lens capsule, in about 95 per cent. of pig and sheep eyes, and in about 70 per cent. of ox eyes. The same occurred in 5 out of 8 human eyes similarly treated, in the other 3 the canal extended 4 mm. forward from the papilla. The cases in which it was not possible to demonstrate the presence of a central canal were those in which a persistent hyaloid artery was present. The canal always passed forward to terminate at the posterior capsule of the lens, midway between the centre and the margin, on the nasal side. Its form is fairly constant. In the sheep it is narrow and cylindrical, but in the pig, and ox, and in man, it has a funnel shape tapering often to a very fine channel as it passes forward. The author describes another experiment to demonstrate the difference between the central canal and an artificially produced channel in the vitreous.

After cutting off the optic nerve entrance as before described, but with the vitreous lying on a glass plate instead of in the salt solution, he drops fluorescein solution upon the posterior pole of the vitreous. This spreads itself over the surface, but the opening of the canal is represented by a colourless spot, from which a clear fluid exudes. If punctures are made in the vitreous with a needle or other object, no such clear spot appears, but the fluorescein solution passes into the opening.

The author is convinced that we are here dealing with an actual canal in the vitreous and not, as Wolfrum thinks, an artefact.

The article is illustrated by four stereoscopic photographs, which show very clearly the structure in question, in the eye of the pig, sheep, ox, and human subject.

A. J. Ballantyne.

---

de Schweinitz (Philadelphia). **Some Observations of the Ocular Manifestations of Sinus Disease.** *Trans. American Ophthal. Society*, 1910.

In this paper de Schweinitz does not allude to what may be called the gross ocular or orbital manifestations of nasal accessory sinus disease—*e.g.*, orbital cellulitis—but records cases showing certain manifestations which, while they are common enough in various types of sinus affection, are not infrequently misinterpreted.

1. *Recurrent or Fugitive Œdema and Ecchymosis of the Eyelids.* This manifestation, which varies from a slight œdema of the lid and flushing of the skin to a marked œdematous swelling of a red colour, is usually associated with intense headache. It differs from the œdema of the lids, so conspicuously present in acute ethmoiditis, antral and frontal sinus disease, in that it comes and goes: the attacks are separated by days, weeks, or months of entire or comparative comfort. It is a typical recurrent or fugitive œdema and may be the only notable symptom of the affection. In some cases, instead of the œdema, an appearance develops which is very suggestive of *ecchymosis* of the lid, which like the œdema recurs from time to time. de Schweinitz reports a case of this kind in a female æt. 55, who had long been subject to attacks of "black eye." Examination revealed a small polyp at the opening of the naso-frontal duct, and the existence of frontal sinus and antral disease. Permanent cure followed operative treatment. The author has

seen a number of somewhat similar cases, in which the usual symptoms were moderate œdema of the eyelid, associated with intense eye pain and supra-orbital neuralgia; all his patients stated positively that their discomfort was induced or aggravated by use of the eyes, and for that reason they consulted an oculist.

de Schweinitz suggests that in a certain number of the familiar cases of "fugitive œdema" of eyelids associated with headache, unsuspected sinus disease may be the real etiological factor. It would be well at least to include a thorough investigation of the sinuses, in the examination of every such case.

2. *Fugitive Episcleral Congestion.* As is well known the term *Episcleritis periodica fugax* was applied by Fuchs to a variety of relapsing episcleritis, characterised by the appearance of patches of dusky episcleral injection or œdema, lasting a few days, and reappearing at intervals of several weeks or months. The same affection was described by Swan M. Burnett under the name of *Vasomotor dilatation of the vessels*, and by Jonathan Hutchinson as *Hot eye.* With this disease gout or rheumatism are usually associated.

There is a manifestation of sinus disease which is not unlike this. It is a form of episcleral congestion with dilated and tortuous subconjunctival vessels, the area having a violaceous tint. The patch of congestion is not bleached by adrenalin. Like the fugitive œdema already referred to this episcleral congestion comes and goes, and differs from ordinary episcleritis in the deeper hue of the dilated and tortuous vessels and in the association of violent headache. Cases of this kind may be easily mistaken, even by careful observers, for ordinary types of episcleritis and consequently the search for sinus disease may be omitted.

3. *Some Unusual Forms of Scotoma as the Result of Sinus Disease.* The occurrence of optic neuritis, neuro-retinitis, and thrombosis of retinal vessels as an indication and as a result of sinusitis is well known. It is also common knowledge that disease of sinuses may cause retrobulbar neuritis, with its well known symptoms of obscuration of vision, beginning in the central field and rapidly progressing to complete or nearly complete blindness with at first little or even no ophthalmos-

copic appearance of disease, and with pain on movement of the eyeball.

It is not this class of case that the author includes under his third heading, but that to which much attention has been paid recently, notably by Jessop, Fuchs, Posey and others, and in which, either with or without limitation of the peripheral visual field, there has been a scotoma. The scotoma may be for colour only, or for white, while the ophthalmoscopic examination is practically negative, or may show slight blurring of the margins of the disc and pallor of its temporal part.

de Schweinitz reports a very instructive case of this kind: A young woman, after a number of attacks of fugacious episcleral congestion over the external recti, with intense headache, was seen by him during the height of one of these attacks with vision $^{6}/_{36}$ in each eye, unimproved by glasses. There were no abnormal appearances in the fundi. No constitutional derangement could be detected. Vision became more impaired, and there were found a delicate ring scotoma surrounding the fixation point in the left field, and a triangular paracentral scotoma in the right field. The patient had been under treatment for mastoiditis some years previously, but no operation had been performed. Careful intranasal examination failed to show any definite lesion indicative of sinus disease, and x-ray examination gave no further help. Catheterization of the sphenoid gave the first definite evidence of sinus disease, a small quantity of pus being withdrawn from the left sphenoidal sinus. Vision became further reduced, and the scotomata increased in size and became more central, extending chiefly temporal-wards from the fixation point (shown in charts in the original paper). Active treatment, which included washing out the sphenoidal sinus at stated intervals, was followed by some relief of symptoms and by slight improvement in vision; the scotomata became less absolute.

After some months, in which there was general improvement, vision rose to $^{6}/_{60}$, but there was a large oval central scotoma in each eye, extending further to the temporal side than elsewhere, and not unlike the scotoma of toxic amblyopia. The scotoma was present for red and green, but the perception of white light over the area seemed to be normal. Headache had disappeared, and the attacks of intense episcleral congestion had ceased.

A year later the vision had risen to $^{6}/_{25}$, but a slight relative

scotoma for red and green was still present. At no time was there any definite change in the optic disc or retina, but the retinal veins appeared somewhat fuller than normal.

That the conditions described were really due in part, if not wholly, to disease of sphenoid sinus seems definitely proved by the results of treatment by irrigation of the sinus, together with residence in a warm climate.

A recent paper on "Affections of the Optic Nerve in Sinus Disease," by de Kleijn, appeared in abstract in the October number of the *Ophthalmic Review*; in it the author laid stress upon perimetric observations of the blind spot as affording valuable indications as to diagnosis and treatment in cases of sinus disease.

J. B. L.

MORAX. **Ocular and periocular Metastases in Staphylococcus infections.** *Annales d'Oculistique*, July, 1910.

THIS is a long and interesting paper which contains references to the literature as well as a detailed account of a case which was gone into most carefully from all sides by the author.

In metastases of the eye due to the staphylococcus aureus the primary affection is often almost trifling, *e.g.*, wounds of the fingers, although whitlows, pyelo-nephritis and uterine infection after retained placenta have been recorded as causes. Grave general signs are usually absent and the temperature may rise slowly to 38·5°C. or may resemble that of intermittent urinary fever, in one case the metastases taking place after four days of apyrexia. Usually there is less temperature than in streptococcus or in pneumococcus infections. The ocular or peri-ocular involvement may be the first sign of a general infection, and this may occur as early as the seventh or as late as the twenty-fifth day after the original infection. Liebrecht's case of a young man with hyperpyrexia and a frontal sinus infection complicated by endocarditis and by renal and hepatic abscesses —where, after death, a small abscess was found in the choroid— is put aside by Morax as not belonging to the clinical group under consideration. Morax gives three groups of cases:—

1. *Intraocular Cases*—metastatic retinitis or choroido-retinitis. Brief notes are given of Axenfeld's case of circumscribed abscess of choroid between equator and limbus; of the very interesting case of Holmes Spicer where the metastasis was

visible ophthalmoscopically but where the diagnosis of staphylococcus had to be made on morphological grounds only; and of de Collombo's and Müller's case after uterine infection, where, after seven weeks of irido-cyclitis, a circumscribed patch of choroido-retinitis could be seen near the papilla. As this case cleared up the diagnosis could be made only from the bacteriological examination of the blood and of the uterine discharge.

2. *Extraocular*—in two sub-groups. The first includes episcleral affections and tenonitis. These are not very frequent. Dupuy-Dutemps' case of isolated anterior scleral abscess subsiding without further complications is unique in Morax's experience. Tenonitis is characterised by painful progressive exophthalmos with chemosis, and immobility of globe with the appearance after some weeks of pus beneath the bulbar conjunctiva near the muscle insertions. The cases recorded by Natanson, Adler and Rollet are briefly referred to, in each of which the evacuation of pus from beneath the bulbar conjunctiva relieved the proptosis.

Then follows a long account of the author's own case—that of a man of 22, who, ten days after a slight septic wound of his left hand, came under observation for painful proptosis of his right eye on December 8, 1908. Pain in the eye and swelling of the lid caused him to consult a doctor, who suspected sinus mischief and treated accordingly. After opening, the palmar abscess healed up readily.

The proptosis was irreducible and pressure caused pain, but the anterior part of the eye showed no signs of inflammation. Marked immobility of globe; orbital margins normal; nose and sinuses normal. Unequal pupils, reactions normal. Ophthalmological examination: media clear, right eye some neuritis. R.V. $= {}^{5}/_{15}$, L.V. $= {}^{5}/_{5}$, fields full. Manifest diplopia. No fever. Lues and tubercle were considered but were put aside. Patient was admitted for further observation. The exophthalmos steadily increased; chemosis of bulbar conjunctiva became more and more marked as well as œdema of lids. Vision gradually deteriorated. On Dec. 13th blood-count gave 86 per cent. of polymorphonuclear leucocytes; two days later sinuses were normal still. Next day exploratory orbital puncture gave negative results. Given iodide of potash. On 19th globe immobile—blood-count gave 76 per cent. of polymorphonuclears.

Lumbar puncture gave no lymphocytosis. On 21st more pain, especially on lifting upper lid—given chloroform and orbital exploration was done after orbitotomy—orbital walls healthy, but at infero-nasal quadrant of globe was found a purple-yellowish area, from which a good deal of pus was removed for examination. On the 26th December hypopyon ulcer of cornea and more proptosis—enucleation next day. Small pocket of pus over superior rectus—orbital walls normal. Good recovery.

Full details are given of the bacteriological results and the histological examination of the globe is fully described. The superficial scleral layers at upper inner part of globe, and back to optic nerve, showed an infiltration with polymorphonuclear cells. No solution of continuity in sclerotic—but signs of stasis in episcleral vessels.

The localised lesion in these cases may be anterior or posterior and it may occur after very insignificant wounds. In Morax's case the blood-count was the only feature against a chronic affection.

The second sub-group contains orbital abscess and orbital periostitis cases. The author's own two cases of orbital periostitis are referred to and the recent case of Wirth's—a girl of 14 who, fifteen days after a whitlow, developed retrobulbar pain, then a painless proptosis. Eight days after orbital symptoms began, the exophthalmos had increased and there was some pain on movement. Vision and fundus normal. About the fourteenth day movements became more limited, V. $= {}^{5}/_{36}$, with a central scotoma and fundus changes resembling those of embolism of central artery. On the sixteenth day slight chemosis of bulbar conjunctiva at outer side, whence pus containing staphylococcus aureus was got by orbital puncture. Orbitotomy done. Proptosis did not begin to diminish till eighteen days later, and vision slowly returned. Five weeks after operation the cure was complete.

Morax would recognise a special clinical picture for the staphylococcus infection, in that such is characterised essentially by relatively circumscribed lesions (intraocular or periocular abscesses) which either burst externally or become absorbed *in situ*; the evolution of the disease is peculiar, too, for it is not a rapid extension to the different members and the intraocular media of a suppurative process such as one gets with streptococcus or pneumococcus, but on the contrary, its onset may be

almost unnoticed, while its extension is slow and limited, some weeks generally elapsing between the first symptoms indicative of an ocular or periocular affection and the appearance on the surface of pus needing removal.

W. C. Souter.

Ophthalmic Year Book. Edited by E. Jackson, T. B. Schneideman, and W. Zentmayer. Herrick Book and Stationery Co., Denver, Colorado, U.S.A.

A change has taken place in the editorial staff of this invaluable annual record of ophthalmic literature. Dr. G. E. de Schweinitz has no longer been able to spare time for the exhausting work required for this digest and his place has been taken by Dr. W. Zentmayer. We are unable to see that the book has in any way deteriorated, and references to our past reviews of the issues of previous years will shew that this is no mean compliment to the new editorial management.

The obituary list with which the book begins is we regret to see an exceptionally long one.

Ophthalmic literature has so enormously increased of late years that it is impossible for the conscientious ophthalmic surgeon to keep abreast of even the more practical clinical part without the aid of some such critical digest as the Year book affords. The ophthalmic surgeon who takes up this book, we venture to predict, will be considerably surprised at the amount of suggestive and important literature he has overlooked.

Oxford Ophthalmological Congress.

The Congress was opened this year with a genial address by Professor Osler. Advance in knowledge was brought about, he said, by three types of mind.

The myopic mind of the narrow specialist ever peering into minutiæ and plodding along in detail.

The hypermetropic mind, such as that of Darwin's embracing vast generalities.

The emmetropic mind correcting finally the mistakes of both. (In this class we must doubtless insert our kindly witty Professor.)

Of the other lectures two call for special comment.

Professor Arthur Thomson, while displaying some wonderfully executed stereoscopic photographs of the structure of the eye, dwelt much on the formation of the angle of the anterior chamber. He considered the old view of the angle as a plain acute angle as incorrect; rather, that just in front of the root of the iris was a small recess into which the iris was folded, on dilatation of the pupil, as a curtain is draped back beside a window.

Even when folded into this recess, he thought that usually a small channel was left behind for filtering purposes. Traction of the iris, such as caused by myotics, obliterated this recess.

Mr. Priestley Smith objected strongly to this new view although supported by such perfect specimens. He pointed out that these specimens were post mortem, and the cornea swells up in a few hours after death, producing this very deceptive appearance which does not exist during life or in eyes which are frozen immediately after removal.

A very interesting lecture was delivered on the second day of the Congress by Professor Poulton on the general resemblance between human vision and that of birds, as indirectly shewn by the mimicry of butterflies in East Africa.

Quite the most valuable address, however, was Mr. Priestley Smith's "Glaucoma Problems." He reproduced much that was old, but necessary to remember at this critical time. In regard to chronic glaucoma he thought that in some form or other the new filtering operations had come to stay, and that they marked a new era in a successful resistance to this dire disease. He emphasised very strongly the need of a scotometer for the early diagnosis of this complaint, and advocated its extensive use with old people.

A number of operations were performed by noted surgeons, with varying success, at the eye hospital before the Congress. It is difficult to understand what useful purpose these operations serve. In spite of a large specially erected stand only a very few could catch a glimpse: while the excitement was not beneficial to operator or patient. The repeated demonstrations on pigs' eyes are far more profitable.

There was a good display of optical instruments and apparatus with some novelties. Professor Remy with a small pocket diploscope was illustrating his theory on "Why the sky is blue." The sky is blue, he thinks, from the retinal fatigue caused by

abundance of light. If we descend into a well, and look up, the sky is white; from our standpoint on the earth it is blue; and if we ascend above the clouds, either from a mountain or a balloon, it becomes almost black. No doubt the colour specialists will have something to say on this theory.

P. C. Bardsley.

Berlin Ophthalmological Society.

14th July, 1910.

Report by Dr. Curt Adam.

Köllner: *Wilbrand's Prism-phenomenon in Hemianopsia.* The author discussed the value of this test in assisting to localise the lesion in cases otherwise obscure. The point of the test consists in this, that when the higher centres are uninjured there is a subconscious movement of adjustment, even though the image of the object with which the test is made is caused to fall upon the blind half of the retina. The test is applied thus: In a case of left homonymous hemianopsia one eye—say the right—is kept closed, and a spot is kept constantly fixed by the left eye. Suddenly in front of this eye there is slipped a prism with its apex outwards, so that the image is caused to fall upon the blind half of the retina. If the higher centres are intact the eye executes a movement of adjustment to the prism so that the image may again fall upon the macula. There are two sources of fallacy, namely, (1) that the patient may by experience have learned, so to speak, to look for lost objects in his hemianopic or lost field and (2) that the macula may still be retained and the image may therefore not fall actually on a blind area, for this would require a more powerful prism. Köllner has investigated nine cases by means of the prism test and has only found it fail once. If at the same moment of introducing the prism one removes the test object altogether, the movement of adjustment takes place just the same,—a proof that this owes its occurrence to experience and not to any impression upon the blind retina produced by the image of the object. The author therefore has no high opinion of the diagnostic value of the test. Schwarz's suggestion to place a prism before one eye alone and observe the fusion-correction, is

not a success as on account of the retention of the macula too powerful a prism is required.

Adam: *Glioma*. The author dealt with the subject statistically, giving an account of all the cases in which enucleation had been performed on account of glioma during the last twenty years in the University Eye Hospital in Berlin. There was a total of 47 cases out of 275,000 patients, or a percentage among eye cases of 0·017 per cent. Eighty per cent. of the patients were under three years of age and 93 per cent. under four. In four instances out of the 47 the condition was bilateral and in three there was a history of the disease in members of the family born earlier. Of the children 44 could be traced subsequently, and enquiries pointed to three conclusions: (*a*) that if enucleation is performed before the coats of the eye have given way, while yet the disease is at least apparently confined within the globe itself, the prognosis is very favourable, but not at all so when once the coats of the eye have given way. (*b*) Should recurrence take place locally the case is hopeless. (*c*) In the first two stages (*i.e.*, before perforation has occurred) enucleation with section of the nerve well back is the proper operation, but exenteration of the orbit is required when the third stage has been entered upon.

W. G. S.

GLAUCOMA PROBLEMS.

By Priestley Smith.

(*Continued from page* 296.)

So far there is no real difficulty. The causes of the tension are easily defined and are probably no longer in dispute. The same may perhaps be said of the secondary glaucoma which sometimes complicates anterior synechia following wound or perforating ulcer of the cornea. But when we come to primary glaucoma and the forms which nearly resemble it the case is different. The causes are difficult to discover, they are still to some extent uncertain, and they are much disputed. Before attacking the problem let me remind you of an experiment which throws some light upon it.

Take the two eyes of a freshly killed sheep or pig. Inject them wth a coloured watery solution in the manner shown in Figure 9. In the one let the pressure be 30 cm. in both chambers—the normal pressure. In the other let the aqueous pressure be 30 cm., the vitreous pressure 35 cm. The result will be strikingly different in the two eyes.

The first, in a few minutes, will show a complete injection of the episcleral veins, and the fluid will soon begin to escape from their divided ends. The iris will be completely hidden. The fluid escapes freely because it has access to the filtration angle. The second, even after several hours, will show no injection and no escape of the coloured fluid at any part of the eye. The iris will be hidden by the fluid in a zone surrounding the pupil, but elsewhere will be visibly in contact with the cornea. Filtration from this eye is arrested because the angle of the chamber is closed.

For further proof of this, freeze the two eyes while the

injection is going on, bisect them, and examine the condition of the anterior chamber in both. In the one, the chamber is of normal depth and the angle open; in the other it is shallow and the angle closed. In the latter the small preponderance of pressure in the vitreous

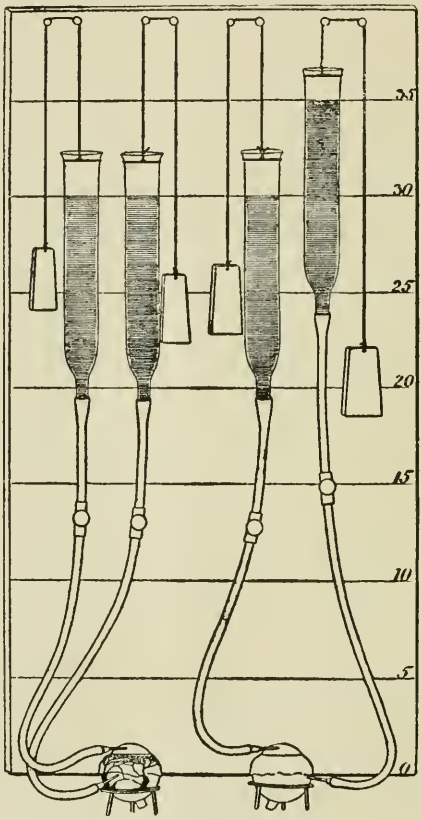

Fig. 9.

has had the remarkable effect of arresting filtration from the eye. By further experiment it is easy to prove that a still smaller preponderance is sufficient to retard it.

Experimentally, then, we can obstruct the filtration angle by displacing the lens, ciliary processes, and iris

towards the cornea. This is important, for a similar displacement occurs in certain forms of glaucoma.

The secondary glaucoma of choroidal tumour is one of these. Clinically we see the anterior chamber become shallow just before, or simultaneously with, the the onset of high tension. In the hardened and bisected eye we find the filtration angle closed. The base of the iris is in apposition with the cribriform ligament and to some extent with the cornea—adherent if the glaucomatous attack has been intense and prolonged, non-adherent if mild and recent. The manner in which the closure has been brought about is obvious in some cases but not in all. It deserves most careful study for it helps to explain the more mysterious origin of acute primary glaucoma. It should be studied in the divided eye while it is still frozen, *i.e.*, before the parts concerned have altered their relative positions, as well as more deliberately in mounted specimens and photographs.

In tumour-glaucoma the intruder on the contents of the globe lies not in the vitreous, as in the foregoing experiment, but beneath the retina. The outbreak is not determined by the volume of the tumour, for a small tumour may excite a violent attack, while an eye removed during the pre-glaucomatous stage may contain a much larger one; it is determined by the volume of the subretinal exudate. This proceeds from the capillaries of the choroid in the vicinity of the tumour, and is formed very slowly. In the case represented in Fig. 12, for example, detachment of the retina began more than 17 months before the outbreak of the glaucoma. As its volume increases that of the vitreous body diminishes by like amount, the vitreous fluid gradually escaping by way of the aqueous chamber (see p. 292). When little remains of the vitreous but its stroma, and the inverted retina has been driven inward upon itself and forward against the lens and ciliary body, these latter structures also are necessarily driven forward.

Then the glaucomatous attack begins. It is commonly acute, and severe; it is always unremitting. When the tumour is hidden by turbidity of the media the condition may closely simulate a primary glaucoma.

Figure 10a shows a case which was mistaken for a primary glaucoma in the absolute stage until the eye was opened. It presents a striking picture of high pressure in the hinder segment of the globe. The albuminous fluid beneath the inverted retina has driven the lens, ciliary processes, and iris forward to the utmost limit, and has squeezed them into an abnormal shape. Figure 10b shows more clearly how the flattened ciliary processes are pressed against the base of the iris. In this case the complete coagulation of the exudate has kept all the parts in their abnormal positions even after division of the eye.

Figure 11a shows how, where there is no solid exudate to fix them, the parts tend to separate when the internal pressure is relaxed. The over-stretched retina has receded from the ciliary body and the lens; the lens has receded a little; on the right side the iris has receded with the lens, on the left it has remained slightly adherent to the cornea. Figures 11b and 11c show the abnormal shape and position of the ciliary body and iris still more clearly.

Figure 12 shows the lens and ciliary processes at some distance from the displaced and adherent iris. The part which they have played during the attack is not immediately apparent, but when we compare this picture with the two foregoing cases, and note that the lens was seen to be close to the cornea at the time of excision, there can be little doubt that the manner of the closure was the same as in the others.

Figure 13 shows a condition which I believe to be very unusual. The anterior chamber, far from being shallow, is extraordinarily deep, and is filled with a solid coagulum like that beneath the retina. The lens is displaced

10 a.

10 b.

Fig. 10 a. Sarcoma of choroid. Intense secondary glaucoma. Male (Bellamy); age 63—Formalin.—Retina, lens, ciliary processes, and iris driven forward by sub-retinal exudation. Exudate highly albuminous—coagulated.

Fig. 10 b. From same specimen. Ciliary region at left side. Ciliary processes squeezed between retina and iris; iris pressed against cornea; shape of lens altered by pressure. (See p. 356.)

11 a.

11 b.

11 c

Fig. 11 a. Sarcoma of Choroid. Secondary glaucoma after use of homatropine: eserin used later. Excision on the 6th day. Female; age 42.—Mueller's fluid; ring section mounted in glycerin jelly.

Fig. 11 b. From ciliary region at right side of same eye.

Fig. 11 c. The same: left side. (See p. 356.)

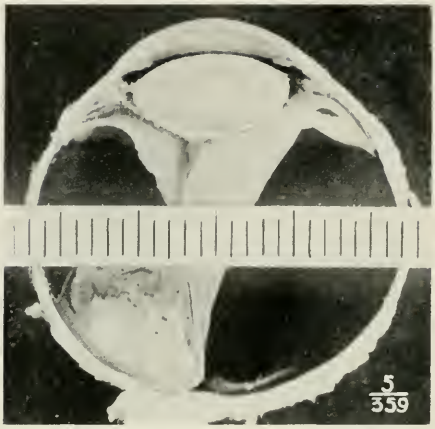

12.

13.

Fig. 12. Sarcoma of choroid. Secondary glaucoma. Female; age 60. —Mueller's fluid. (See p. 355–6.)
The fellow eye was treated 7 years later for simple chronic glaucoma.
Fig. 13. Sarcoma of choroid. Secondary glaucoma. Female; age 56. —Formalin. (See p. 356.)

far back and a little to one side. The root of the iris is adherent just as in the previous example, but the rest of it slopes backward to the lens. The condition is explained when we see that the retina, hyaloid, and zonule are torn through at the right side and have allowed fluid from behind the retina to enter the aqueous chamber. Here, as in the previous cases, the parts in question have been driven forward by the subretinal effusion, and the filtration angle has been closed thereby, but the retina, stretched beyond its limit of elasticity, has given way, the fluid imprisoned behind it has gushed forward, and the displaced parts, released from the pressure which had driven them forward, have receded to the unusual position in which they are seen. A violent exacerbation of the glaucoma with great swelling of lids and conjunctiva occurred the day before the eye was removed.

These examples show that in the glaucoma which complicates choroidal tumour filtration from the eye is arrested in a manner much resembling the experimental proceeding already described, and will help to elucidate the more difficult problem which follows.

Acute primary glaucoma bears, in certain of its features, a close resemblance to tumour-glaucoma. The anterior chamber is usually shallow—in some cases, as every operator knows, so shallow that the knife will hardly pass between iris and cornea. How far this is a pre-existing and pre-disposing condition, how far a part of the attack, as in tumour-glaucoma, is an important question, but it can be discussed more profitably later on. In the bisected eye we find the filtration angle compressed or closed, the iris base in apposition with the opposite wall if the case is recent, adherent to it if it is of longer duration—as in tumour-glaucoma. In recent cases we can see, I think, that the iris base has been pushed forward by the ciliary processes; in older cases this is sometimes less obvious.

So far the resemblance to tumour-glaucoma is striking, but here it ends. We find no solid growth or voluminous exudate to account for the displacement; we find only a well marked swelling of the ciliary processes and iris, a condition not usually found in tumour-glaucoma.

The nature of the initial disturbance is peculiarly difficult to investigate. In the living eye the condition of the filtration angle cannot be estimated from the visible depth of the chamber. A chamber of normal depth in the region of the pupil may be closed at the periphery, and one which is extremely shallow may have an open angle. This will be seen in some of the photographs. Further, we can seldom study the early stage of the disease under the microscope. We usually save the eye by iridectomy, and even if we fail, and it comes to excision after all, it is then no trustworthy witness as to the nature of the initial disturbance. Only when the chance of saving the eye is very small, and is outweighed by the need for certain and lasting relief from pain, do we immediately excise it.

Figures 14a, b, c, show the filtration angle of an eye removed on the 10th day of an acute attack. The eye was previously useless through senile cataract, the fellow eye was good, the patient old and feeble. In all sections the iris-base appears to have been tilted and pushed forward by the swollen ciliary processes. In many the choroidal end of the ciliary body is drawn away from the sclera—by traction of the zonule—and at first sight the displacement of the iris might be attributed entirely to tilting of the ciliary body, but a comparison of these sections with others similarly made from healthy eyes (Figs. 1a, b, c, 2a, b, c) and with the subsequent figures in the glaucoma series (15a, b, c, and 16) will dispel the idea. In some sections (Fig. 14a, c) a small open channel is visible at the extreme limit of the filtration angle: the iris comes first in contact with the



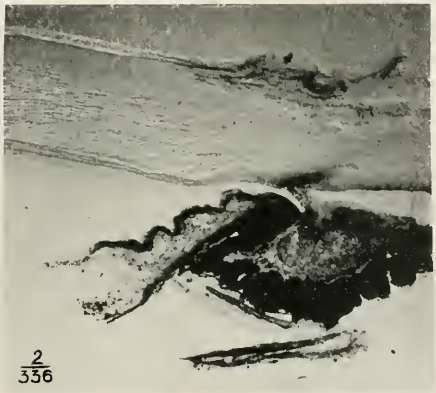

14 a, b, c.

Figs. 14 a, b, c. Acute primary glaucoma—with senile cataract. Excision on 10th day. Anterior chamber very shallow: pupil dilated and irresponsive to eserin; T + 3; V = 0; pain and injection. Female; age 74. Mueller's fluid; glycerin jelly; sections not stained. (See p. 358.)

15 a

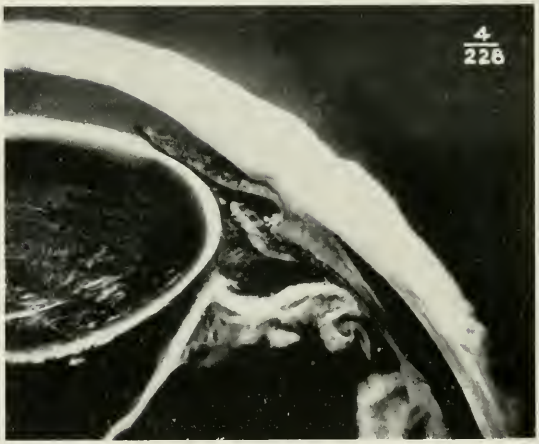

15 b.

Fig. 15 a. Acute primary glaucoma. Excision on 23rd day. Pupil of medium size; circular; eccentric. Blood on surface of iris. Male; age 63; alcoholism; bronchitis.—Mueller's fluid; ring section in glycerin jelly.—(See p. 359.)

Dimensions of this eye:—Cornea; horizon.-diam., 10·5 mm. Globe; horizon., 23 mm., antero-posterior, 23 mm.

Fig. 15 b. From same specimen as Fig. 15 a, more magnified, and with dark background.

opposing surface not quite at its root where it is thin, but a little further forward where it is thicker.[1] The presence of such a channel at the outset of an acute glaucoma may have some importance in relation to the action of iridectomy.

Figures 15a, b, c, are from a case of longer duration—23 days—but still recent and of great intensity. The iris and ciliary processes are swollen, and their veins visibly loaded with blood. Their shape and position are significant of forward displacement by pressure from behind. The globe is of exceptionally small size.

Figure 16 is from a case of much longer duration. Here again there is intense vascular congestion. The pointed shape of the swollen ciliary process shows that it has wedged itself forward between the periphery of the lens and the base of the iris. The iris has formed a solid adhesion with the cribriform ligament and cornea.

These specimens appear to show that in primary acute glaucoma the filtration angle is closed by the pressure of the swollen ciliary processes, and they suggest that the initial disturbance is an internal congestion of the eye.[2] Following up this clue, let us consider what conditions are capable of causing such congestion, and compare them with those under which acute glaucoma commonly occurs.

The most potent cause of congestion in an organ or vascular area is obstruction of the efferent veins. In the case of the eye, experiments have proved that ligature

1. This observation has been confirmed by Fuchs. See *Ophthalmoscope*. October. 1908, p. 742. Also by Birnbacher, *Beitrag zur Anat. des Glauc. acut.* Graz: Leuschner and Lubenski. 1890, pp. 24 and 25.

2. If this conclusion is correct, the credit belongs to Adolph Weber. He asserted it in 1876.—"Die Ursache des Glaucom's," *von Graefe's Archiv.*, xxii, 1. It is not universally accepted. Thomson Henderson maintains that "it is not the iris which is pushed forward by the ciliary processes, but, on the other hand, it is the ciliary processes which are dragged forward by the iris."—*Ophthalmoscope*, October, 1908, p. 755.

of the vortex veins outside the sclera causes intense congestion of the uveal tract, with swelling of the processes and iris, exudation of serum and corpuscles, shallow chamber, and very high tension—in short an artificial glaucoma of great intensity. This is an illustration of what complete obstruction of the veins can do, but it is nothing more. In actual glaucoma the veins are not ligatured nor are they even blocked by thrombi as some writers have suggested; the congestion certainly arises in some more ordinary way.

The venous system as a whole contains more blood when the heart is inefficient. Each contraction of the heart drives a certain quantity of blood into the arteries and the ensuing dilation admits an equal quantity from the veins. An inefficient heart drives out less, and admits less, than it should. The arteries, being less forcibly distended, assume a smaller calibre, by reason of their elasticity, and the flaccid veins, especially the larger trunks, are filled out by the surplus blood. Thus it comes about that the total quantity in the arterial system is smaller, that in the venous system greater, than when the heart acts well.

Again, the venous system is liable to become overfull in sedentary persons and those confined to bed, for muscular inactivity not only slows the circulation but withholds from the venous currents the direct assistance which intermittent muscular contraction gives. On the other hand, violent muscular effort, while it lasts, congests the veins—by compressing them, by embarrassing the heart, and by fixing the chest wall and thereby disturbing respiration.

Congestion in the region of the head and neck is often obviously due to disturbance of respiration. Normal inspiration, by inducing negative pressure in the thorax, slightly aids the venous return; normal expiration slightly opposes it. During violent or prolonged expiratory effort, as in coughing or trumpet playing, one

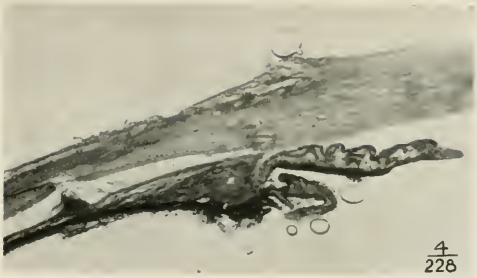

15 c.

16.

17.

Fig. 15 c. Thin section from same eye as Figs. 15 a, b. (See p. 359.)

Fig. 16. Acute primary glaucoma. Excision about 12 months after the attack which blinded the eye. V = 0: T + 3. Female: age 66.—Mueller's fluid; glycerin jelly. (See p. 359.)

Fig. 17. Relative sizes of average healthy lens at 25 and 65 years of age. (See p. 364.) The antero-posterior diameter is here shown too large in proportion to the transverse. The relation between the sectional areas is correct. (See footnote, p. 364.)

may see the throat thicken, the face grow purple, the temporal veins enlarge, the eyes protrude.

Again, localised congestion in various regions, and notably in the head, is often largely due to vaso-motor action. The vaso-motor system, when acting normally, apportions the supply of blood variously to different organs according to their varying needs. Thus, to the brain it allots a full supply for strenuous mental effort, less for tranquility, still less for sleep. To the stomach, more when a meal has to be digested, less when the demand for gastric juice is over. To the skin, more when it is exposed to external heat and must perspire to keep down body temperature, less when loss of temperature through external cold is to be avoided. But when the nerve-apparatus is exhausted and irritable these fluctuations are apt to become excessive. For example, a tired man takes an ample meal, seats himself at the fireside, and begins to read. Before he has mastered the first page he is fast asleep. The warmth and food have called the blood to the skin and stomach, the vaso-motor apparatus has yielded too easily, and has depleted the brain in doing so. Or—to reverse the picture—he sits long and late at his writing table, his mind intently at work, goes to bed with feet cold and head hot, and lies awake for hours because the arterioles of his brain fail to contract and those of his feet fail to dilate.

The tendency to congestion is of course particularly great when several of these influences act together, as, for example, when a man whose circulation is habitually sluggish is over-worked, chilled, and at the same time subjected to some exceptional mental anxiety. It must be remembered also that repeated functional disturbance of the circulation leads sooner or later to permanent change in the calibre and elasticity of the vessels.

Now let us glance at the conditions which commonly precede or attend the onset of acute glaucoma.

The acute attack is commonly preceded by certain warning symptoms—the well known mists and rainbows—repeated again and again over months or even years. Their evanescence points to a transitory vascular disturbance as the likely cause. The circumstances under which they come and go are highly significant. From one patient or another we learn that they appear when he is weary, chilled, or hungry, and disappear when he is rested, warmed, or fed; that they are most frequent during times of overwork, and vanish altogether during holiday; that they are made worse by worry and loss of sleep, and are cut short by a nap even though it last only a few minutes.

Some attacks arrive unheralded by mists or rainbows, and these too can usually be traced to some depressing illness such as influenza, to some period of worry or extra work, or to some more obvious cause of vascular disturbance such as a chill or a stoppage of the bowels.

The clinical facts, then, no less than the pathological, seem to show that the usual starting point of an acute primary glaucoma is *congestion of the uveal tract*. But not every congestive attack is followed by glaucoma. A congestion which does not obstruct the filtration angle, may, nevertheless, raise the chamber pressure in some degree, cause photopsia, and perhaps suffice to induce mists and rainbows, but it will not start a glaucomatous attack. The congestion which establishes an acute glaucoma appears always to obstruct the escape of the aqueous in addition to raising the pressure of the blood.

Another starting point, less common but not less certain, is *dilation of the pupil*. A drop of atropine solution applied to the conjunctiva will sometimes light up an acute glaucoma in an eye which has previously shown no sign of disease. The curtains of a window gather themselves into thickened bundles as they are drawn apart. The curtain of the eye thickens in like

manner as the pupil enlarges, and, when the chamber is shallow, may come into contact with the cornea near to its periphery and thus block the filtration angle.[3] Contraction of the pupil by eserine will usually undo the mischief, and it is noteworthy that morphia and sleep, which greatly aid in the subduing of a recent attack, are both contractors of the pupil.

Given an obstruction of the filtration angle, whether by swelling of the processes or by thickening of the iris, the progress from bad to worse is easy to understand. The escape of the aqueous is hindered; the chamber pressure rises and tends to compress the veins of the uveal tract and retina especially near to their points of exit; the venous pressure rises (see p. 293) and leads to further swelling of the processes and iris, and further compression of the angle of the chamber. As less fluid leaves the eye so less enters it. It stagnates more and more. Its pressure approximates to that of the blood. Its constitution becomes altered by exudation of serum. A vicious circle is thus established in which congestion causes blocking of the outlet and the blocking increases the congestion.

But this explanation of the origin of acute glaucoma is obviously incomplete. Feeble circulation, chill, mental strain, and so forth are common troubles; acute glaucoma is comparatively rare. Wherein lies the special liability of the unfortunates?

The lens is to some extent responsible. We have seen it encroach on the anterior chamber by advancing. It does the same by enlarging. We see it enlarge in the course of a day or two after an injury, and induce glaucoma by so doing. We know that it enlarges in

3. The idea that dilation of the pupil induces glaucoma by closing the crypts and thus preventing absorption of the aqueous by the iris can only be admitted, I think, with great reserve, for nearly all young eyes and very many old ones will bear wide dilation of the pupil without showing any discoverable rise of tension.

the course of years by reason of its natural growth: between the 25th and 65th years of life, its diameters, increase by about one-tenth, its volume by about one-third (Fig. 17).[5] As it grows larger the free space which surrounds it grows smaller,—the anterior chamber shallower, the circumlental space narrower. This must entail an increasing risk to the patency of the filtration angle when the processes and iris swell or thicken—in other words an increasing liability to glaucoma. As a fact, we know that the liability to primary glaucoma does steadily increase with increasing age, *i.e.*, with the enlargement of the lens.[6]

Again, it is proved that eyes of subnormal size, which may be known clinically by the smallness of the cornea, are more liable to glaucoma than those of average dimensions. These small eyes are ill-developed as regards the tunics, but not always so as regards the lens; in some of them the lens is large in proportion to the globe. This question of structural disproportion needs further investigation. It will probably be found to distinguish a considerable group of cases from the rest; perhaps to give a useful indication as to probable curability.[7]

5. Transactions, Ophthalmological Society of United Kingdom, vol. 3, p. 79.

6. Transactions, Ophthalmological Society of United Kingdom, vol. 6, p. 294.

7. If the question of structural disproportion is to be carried further by means of hardened specimens, a present source of error must be eliminated. Until 1894, when Leber introduced formalin for the purpose (Trans. Internat. Ophth. Cong., Edin., p. 132), my specimens were hardened in Mueller's fluid; since then in formalin solution. Lately I have made comparative tests, not yet completed, of the action of these two fluids on the lens. They both alter its size and shape, and differently. This will probably explain the fact pointed out by Thomson Henderson (*Ophthalmoscope*, October, 1908, p. 753) that Mueller's fluid tends to detach the ciliary body from the sclera, while formalin does not. It vitiates in

Certain systemic changes, also, *e.g.*, arterio-sclerosis, augmented blood pressure, tendency to œdema and to hæmorrhage, involve a liability to glaucoma. These, however, seem to be associated rather with the chronic non-congestive form, and with atypical acute attacks, than with typical acute glaucoma—that, namely, which begins with mists and rainbows and is permanently banished by a timely iridectomy.

(*To be continued.*)

---

some degree the series of photographs published by myself in a previous work (Figs. 53 to 64, "Pathology of Glaucoma," Churchill, 1891). It does not touch my work on the growth of the crystalline lens, for, in that investigation, only fresh lenses were used. The result of the recent tests will be published shortly. We need a hardening agent which will not affect the size or shape of the lens. But the best way, though a laborious one, to investigate the varying relation of lens to globe would be to weigh the eyeball immediately after excision, and then at once to open it and weigh the lens, in a series of cases.

REVIEWS.

STEDMAN BULL. (New York). **The postoperative history of eighteen cases of magnetic bodies removed by the giant magnet.** *Medical Record,* August 27, 1910.

THIS paper was read before the American Ophthalmological Society in May of this year. It is of great value in so far as it deals only with the history of those cases that could be successfully followed to the bitter end. It only deals with cases in which the foreign body was located with the help of a skiagram, and in all except one successfully removed by the giant magnet (Haab). The extraction was made through the original wound in seven cases and through a new wound in ten. The foreign body was located in the vitreous in eight cases and in the fundus in ten cases. An iridectomy was done at the time of extraction in seven cases. A cataract subsequently developed in eight cases, phthisis bulbi in six, and sympathetic uveitis in eight cases. An enucleation was necessary in ten cases. There was immediate useful vision after the

removal of the foreign body in two cases. Permanent useful vision was not gained in any case.

From a careful consideration of these cases and also of a large number of others that have been published Stedman Bull reaches the following gloomy conclusions.

(1) The foreign body should be located and an attempt made for its extraction as soon as possible after the accident in order to lessen the risk of infection.

(2) When the wound of entrance is in the anterior segment of the eye, and the foreign body has been located in the vitreous or fundus, no attempt should be made to draw it forward by the Haab magnet through the wound of entrance. It seems far wiser to make an incision through the sclera at the nearest point to the foreign body and extract it by means of the small magnet.

(3) These eyes are all suffering from the shock of the original accident, and we have not properly appreciated the severity of the second shock of applying the giant magnet, and forcibly drawing the foreign body through the delicate tissues already seriously injured.

(4) These eyes are all in a dangerous condition, and the prognosis must always be unfavourable, with the great danger of the development of sympathetic uveitis.

(5) If infection has already begun the eye should be enucleated at once.

(6) While the prognosis is always very grave, it is better when the foreign body is in the vitreous than when it is in the retina or ciliary body.

(7) Great care should be exercised in the application of the giant magnet, for more injury may be done by the fragment of iron or steel being drawn through the tissues by the magnet than was caused by the original accident.

(8) If the attempted extraction fail, it is better to enucleate the eye at once.

(9) Even after a successful extraction, useful vision will be permanently lost in the majority of cases, and enucleation will be necessary in order to save the fellow eye. The danger of sympathetic inflammation is ever present, and a general insidious uveitis may develop months and even years afterwards and extend to the fellow eye.

If we compare this list with the Moorfields statistics as compiled by Goulden (Royal London Ophthalmic Hospital Reports, vol. 17) we are inclined to think that Bull has been

somewhat unfortunate in his results. He does not draw attention to the great importance of the condition of the lens, though he mentions that the lens shewed opacity in eight of his cases. In ten of the cases the foreign body had reached the eye by a scleral wound, and as Goulden points out these are the cases that give the ultimate worst results.

E. E. H.

SALUS (Prague). **About Glaucoma secondary to swelling of the Lens in cases of Senile Cataract, and its treatment.** *Klinische Monatsblätter für Augenheilkunde*, vol. 48, August.

THIS paper deals with five cases of glaucoma arising in the stage of intumescence of senile cataract, and one case of glaucoma secondary to cataract in a subluxated lens. The cases are from Elschnig's clinic, and have occurred during the last three years.

The cases themselves need no comment, save to note the fact of three of them occurring in glass-blowers and one in a stoker. Salus calls attention also to three other cases of this condition in glass-blowers, which have been published by Bayers, and thinks that those compelled to work in the immediate neighbourhood of powerful heat are necessarily more susceptible to rapid swelling of the lens, and the observations of Hirschberg on the prevalence of cataract in tropical countries seem to lend support to this view.

As far as treatment is concerned one cannot do better than quote Salus' conclusions which are as follows.

If by means of instillation of miotics the tension can be reduced to normal, and the anterior chamber is sufficiently deep, immediate extraction either by the simple or combined method is indicated, if the glaucoma has existed only a short while. Should the anterior chamber remain shallow, and the tension raised, a posterior scleral puncture followed by an extraction should be performed. Salus is in entire agreement with the principles laid down by Arlt and Czermak, that in cataract complicated by glaucoma, the glaucoma must be dealt with before the extraction is undertaken.

R. R. JAMES.

SCHIECK. **The meaning of typical degenerative spots in the Macula region in Albuminuric Retinitis.** *Klinische Monatsblätter f. Augenheilkunde*, vol. XLVIII, part X.

THIS paper from the Göttingen clinic deals with twelve cases of changes in the fundus similar to those of albuminuric retinitis, without any evidence of kidney disease being present.

The cases are arranged in 3 groups as follows:—

(A.) Star figure at the macula without any other evidence of disease in the fundus, with normal urine. This group is subdivided into two classes according as the star figure was one sided or both sided.

(B.) Albuminuric-like macula changes in severe retinal and optic nerve disease.

(C.) Macula changes like those of albuminuric retinitis, in optic neuritis without nephritis.

Group A. Subdivision (1) is composed of two cases, the first that of a miner aged 26 years who showed a typical star figure at one macula, with one fine hæmorrhage, and who one year later still showed the macula star. The second case is that of a boy 16 years old, at whose macula on the left side there was a typical brilliant white star figure. There was no evidence of any other disease in his body.

Subdivision (2) also consists of two cases, the first a female aged 19 years, with a great white splash figure with radiating white streaks, on both sides, with vision of fingers at 4 metres in one eye, and very greatly reduced in the other eye. The second, a man aged 40 years, referred from the medical clinic, with Korsakoff's disease, who showed typical albuminuria-like changes on both sides, and whose fundus appeared normal on both sides one year later.

Group B. is composed of four cases, the first a female aged 24 years who for eighteen months had complained of headache and giddiness, and who was found to have a mass of exudate on the right papilla, with an incomplete star at the macula. The vision was hand movements, the left eye normal, urine normal, and no evidence of any other disease; a year later the macula star had disappeared; four years after the only evidences that remained of past disease were traces of the remains of exudation along the vessels, and vision had risen to fingers at 5 metres.

The second a boy of 18 years of age, with incomplete star. The third a girl of 9 years of age, with marked optic neuritis on one side, a white spot just external to the papilla, a greyish exudate along the vessels, and a slight neuritis on the other side; a fortnight later a star had appeared on the most affected side, and shortly after a similar star had made its appearance on the other side. Three months later the eye with most changes originally had cleared up completely, and vision was normal, the other side showed a slight degree of post-neuritic atrophy.

Case 4, an acpuired syphilitic, aged 26 years, who found his sight suddenly deteriorated while he was suffering from a severe cold in the head. This fundus showed a severe unilateral optic neuritis, with central scotoma for colours and white. Shortly afterwards a star developed at the macula, a trace of albumen was found in his urine, which the physicians put down to his treatment by inunction, which was accordingly omitted, when the retrobulbar neuritis quickly cleared up.

Group C. is also composed of 4 cases, the first an old man aged 66 with unilateral neuritis and fine hæmorrhage, and white spots at the macula, without albumen in the urine, and who ended in post-neuritic atrophy; the second, a man aged 32 years, supposed to have a cerebral tumour, with right VIth palsy, and right sided hemianopia, double optic neuritis, 4 D swelling, and a star at the right macula. A year later the disc was still swollen, the star had disappeared, the external rectus palsy was cured, but the hemianopia persisted. The third case that of a 17 year old girl, with double VIth palsy, double optic neuritis, and spots at each macula. The neurologists in this case suspected a tumour of the pons, and the case was lost sight of. The last case is that of a child of 6 years of age, with slight optic neuritis, typical star at each macula, and a discharge from the ear, for which he was transferred to the ear clinic.

It will be seen that with the exception of two cases the ages of these cases are on the right side of 35 years, and that most of the cases of Group C. can be looked upon as suspicious of cerebral tumour or abscess.

The author discusses the formation of the star-shaped figure at the macula. This paper would have been of more value had he given us notes on the arterial blood pressure in each case.

R. R. James.

CHESNEAU (Nantes). **Acute unilateral Ophthalmomalacia and Enophthalmos in a case of Graves's disease.** *Annales d'Oculistique*, May, 1910.

THE case here recorded exhibited a very unusual complication of Graves's disease. It is as follows: A married woman, whose previous history is unimportant, developed in her forty-sixth year typical symptoms of exophthalmic goitre, which were speedily relieved by the administration of salicylate of soda. Three years later (in 1901) the tachycardia returned, the proptosis was considerable, and the vision of both eyes was impaired by the presence of incipient nuclear cataract. In 1908 her condition was practically unchanged, and continued so until the beginning of this year when she was suddenly seized with weakness in the legs, intense vertigo, while a dense mist obscured intermittently the sight of her right eye; she noticed too that this eye became diminished in size and very quickly sank back into the orbit. She was seen two days later by the author who observed that the right eye had not only returned to its normal position but even appeared retracted into the orbit, while the palpebral fissure was distinctly contracted. Its tension had fallen so considerably that it felt quite flabby, although it still retained its spherical shape. The pupil was smaller than that of the other eye, but the difference was not so great that one could speak of miosis on this side: it reacted only consensually to light. The vision was reduced to hand-movements: the presence of the cataract rendered an ophthalmoscopic examination impossible, nor could a red reflex be obtained from the fundus by transmitted light. In the case of the left eye the exophthalmos continued as before while the tension remained normal: the pupil was dilated and reacted normally to light. On both sides the iris was markedly tremulous.

Under the use of electrical treatment the tension of the right eye was improved, but remained slightly subnormal, and when the treatment was stopped it collapsed again very rapidly. From that time it has continued in this very soft condition: the position of the globe and the width of the palpebral fissure are normal. The pupil does not react to light, it measures $2\frac{1}{2}$ mm. and responds slightly to pilocarpine and atropine. The sensibility of the skin and cornea is normal: there is no hyperæmia of the conjunctiva and no difference in colour between the two sides of the face.

The author refers shortly to a series of five cases collected

from the literature by Sattler in the Graefe-Saemisch Handbuch, where the signs of irritation or paralysis of the cervical sympathetic were manifested, but in none of these was the same collapse of the globe exhibited as is shown accompanied by contraction of the pupil and disappearance of the exophthalmos in this case.

In commenting on this sudden disappearance of the proptosis after some ten years Chesneau goes on to consider the possible causes of exophthalmos and while admitting the action of the suspensory ligaments of the eye in drawing it forwards as affording at least a partial explanation of this condition he finds another factor in the view expressed by Dianoux, according to which the ligamentous expansions of the recti muscles play the most important part. Besides their normal action as check-ligaments they contain numerous smooth muscle fibres and one can understand that the action of these fibres under stimulation of the sympathetic (like Müller's muscle) may be to force the eye forwards and being kept in a state of tonic contraction through continued irritation of the sympathetic they maintain the proptosis: while in this case, through paralysis of the sympathetic, the muscular fibres of these ligaments lose their tonicity and thus allow the eyeball to be drawn backwards by the recti muscles and other tissues of the orbit.

T. S.

Fritsch, H., Hofstätter, A., Lindner, K. **Experimental Studies on the Trachoma Question.** *v. Graefe's Archiv für Ophth.*, LXXVI, 3.

This is an account of an important research upon the nature of the cases of ophthalmia neonatorum in which cell-inclusions have been found, morphologically identical with trachoma bodies. The cell-inclusions have been found in these cases mostly alone, but occasionally associated with gonococci.

Nine experimental inoculations of discharge from various sources were made upon the conjunctiva of baboons, and one upon the conjunctiva of a macacus. These experiments were in continuation of a similar successful one performed by Lindner upon a macacus, reported elsewhere. Successful inoculations were made, not only from infants' eyes affected with gonococcus-free blenorrhœa, but also from the vagina of the mother of one of these infants, and from a male urethra presenting a definite type of gonococcus-free inflammation. This Wälsch type

of urethritis is of chronic course, with grey mucoid discharge, and resistent to treatment. The discharge from each of these three sources contained the same typical cell-enclosures, as well as free "initial forms," indistinguishable from those found in trachoma. By the inoculations a characteristic conjunctivitis was set up in the baboon's eyes, which could be transferred from one animal to another. These experimental conjunctival inflammations fall into two groups. There is a purulent type with acute onset, an incubation period of 3–5 days, and a relatively short duration of three weeks, ending in a free formation of lymph follicles. This form of conjunctivitis results from infection with secretion from the so-called "inclusion blenorrhœa" of infants.

The second type commonly sets in later, after 7–11 days' incubation; is more chronic, lasting several months, and produces much more prominent granulations. Such cases result from material taken directly from the adult genital tract. The cell-inclusions may not be found in the discharge from the infected conjunctivæ till after the height of the attack has passed.

The identical morphological findings in the secretion from the three human sources, the transference of the infection in each case to apes, with the same findings, and the further transference of the disease from animal to animal, make it certain that we are dealing with one and the same virus in man, woman and child. The authors are unable to distinguish the conjunctival changes produced in the baboons' eyes from those which follow the inoculation of trachomatous material. They even go so far as to express their opinion that the virus in the cases now dealt with is actually that of trachoma.

H. Herbert.

Lindner, K. **The Free Initial Form of the Prowazek Cell-Inclusion.** *v. Graefe's Archiv für Ophthal.*, LXXVI, 3.

Lindner wrote last year (*Wien. klin. Wochenshr.*, Nr. 49, 1909) upon the early developmental phase of the trachoma body, describing it as it occurs both in the cell-inclusions and free in the secretion. The present paper describes more fully the "initial bodies" and the part they play in the cell-enclosures.

By the study of the trachoma body in sections of tissue a somewhat different picture is obtained from that shown in smear preparations. The difference applies especially to the

early blue substance, the first evidence of infection in an epithelial cell, which substance has been regarded as a plastin mass or reaction product. In sections the affected cells show at first sharply-defined rounded blue bodies, of the size of cocci, or occasionally much smaller. These lie from the beginning mostly in a clear space in the protoplasm, where they multiply into a rounded heap. The centre of this group of "initial bodies" soon changes into a mass of finely granular or honeycomb structure, containing the well-known small red granules evenly distributed through it. This central mass with its red granules increases in size at the expense of the early blue structures, so that the latter may often be seen forming a single encircling row. Later the initial bodies become still more separated, and may occasionally disappear completely.

These initial structures cannot be cell-formations, reacting to the trachoma poison, because they are found also between the cells and lying free in the secretion. Their parasitic nature is attested also by their coccal appearance and by their mode of division. They are not well seen in the cells of smear preparations because they are evidently soft delicate structures, easily influenced by mechanical conditions. Smears, however, are suited for the examination of the free bodies, in which the mode of division is best seen. Many of the dividing forms stain only peripherally and have clear centres. From the primary discoid form, seen as a ring, there is gradual elongation with bipolar staining, giving at first a diplococcal appearance and later the form of a short rod, which becomes constricted laterally to give a biscuit shape, before division into two circular forms, each with peripheral colouring at first crescentic (partial), later completely enclosing.

The initial bodies differ from cocci in dissolving readily in a 10 per cent. solution of tauro-cholate of soda.

Lindner believes that the red granules, the "elementary bodies," which replace the initial bodies throughout the cell-inclusion except quite at the periphery, develop in the protoplasm of the initial bodies. The latter degenerate in the centre of the mass from insufficient nourishment, and the smaller red bodies represent a more resistent phase of the organism. He does not find evidence of any multiplication of the elementary granules, apart from breaking down, and has not seen the dumb-bell forms which have been described. He thinks the latter may have been remains of initial bodies. The red elementary granules are not seen anywhere except in the cell-

inclusions. Halberstädter and v. Prowazek have recently confirmed Lindner's earlier observations on the initial bodies and their relationship to the elementary bodies. H. HERBERT.

BEATSON HIRD, R. **Optic Neuritis in relation to intra-cranial Growth and its treatment.** *The Birmingham Medical Review,* April, 1910.

IN this paper, read before the Birmingham University Medical Society, the author gives a brief summary of the current views on this subject. As far as theory of causation is concerned he favours the mechanical one, giving as his reasons the absence of any clinical signs of neuritis, and the fact that relief of the intracranial pressure is rapidly followed by the subsidence of the so-called neuritis. He points out that early failure of vision before any signs of neuritis are present may occur as a result of distension of the third ventricle pressing directly on the chiasma. The fact that as a rule neuritis is apparent before any loss of vision is in favour of the condition being an œdema in the early stages, the fibres being compressed and atrophy setting in as a consequence. The limitations of the colour field described by Bordley and Cushing (reviewed in this journal May, 1910) are alluded to, and the figures given by these authors are quoted. Beatson Hird on the whole tends to side with the view that the neuritis begins earlier and is more severe on the same side as the tumour, although admitting that exceptions do occur. He concludes as follows:—

1. The type of optic neuritis met with in intra-cranial growth is especially characterised by swelling, and has a typical appearance.

2. In all cases where intracranial disease is suspected, the discs should be examined and the fields taken.

3. In comparing the neuritis of one side with that of the other, the age must be considered as well as the swelling.

4. If this is done much reliance can be placed on the homolateral theory.

5. There is no doubt that the neuritis is dependent on increased intra-cranial pressure.

6. Operation should take place, therefore, early before vision is affected.

The paper does not pretend to contain any original matter but to be a brief account of the present state of our knowledge of this subject, and as such serves its purpose admirably.

E. E. H.

DEUTSCHMANN. **About some unusual reflex Phenomena.** *Beiträgezur Augenheilkunde*, part 75.

THE author briefly summarises the varieties of paradoxical pupil reactions, as described by Piltz in the *Neurologische Centralblatt* for 1902.

(1) The paradoxical accommodation reaction.
(2) The apparent paradoxical light reaction.
(3) The true paradoxical light reaction.

He goes on to say that the paradoxical accommodation reaction is frequently found in functional disorders of the central nervous system, that the apparent paradoxical light reaction is only observed in cases where iridectomy has been performed, and that the true light reaction is a very rare occurrence, and after excluding all known sources of error, such as the reaction due to warmth, to hippus, to sympathetic reaction, and to orbicularis reaction, the only known cases are those of

(1) Morselli, in paralytic dementia;
(2) Bechterew, in cerebral syphilis;
(3) Leitz, in tuberculous meningitis;
(4) Silex, in shock after accidents:
(5) Deutschmann, in syphilitic optic atrophy;

and that it almost without exception indicates a severe organic disease of the central nervous system.

Deutschmann's first case is as follows: A female, aged 69, came towards the end of November, 1909, complaining of failure of vision in the right eye, which came on suddenly 9 days before, being preceded by a flickering sensation. She had had no catarrh, no headache, and no sickness, and felt in other respects quite well. The urine was normal. The eye was white, and free from photophobia, there was no proptosis, no pain on movement, but slight sensation of fullness when the eye was pressed back into the orbit. The pupillary reactions were normal, and the vision, bare perception of light. Ophthalmoscopically a severe neuritis, with some involvement of the neighbouring retina was found, the retinal vessels showed the "nipping" of veins seen in arterio-sclerosis, the circulation in them was going on, and there were no hæmorrhages. The left eye showed an early senile cataract, and the vessels were arterio-sclerotic. The patient was admitted, and an examination of the neighbouring sinuses having proved negative, was treated with injections of D serum. Five days later it was noted that when the left eye was shaded the right pupil dilated,

when the source of light was removed the right pupil contracted momentarily and then dilated again to its former size. The reaction occurred immediately the source of light was removed, and it lasted for three days, although the vision was improving every day; after this a gradual improvement took place, the vision improved, and the normal pupil light reaction returned.

Deutschmann summarises the differences between this case and that of Piltz as follows:—

(1) In Piltz' case the paradoxical reaction was lasting; in his own transitory.

(2) In Piltz' case the reaction was symmetrical; in his own one-sided.

(3) In Piltz' case the reaction could be brought about consensually, and in his own this was not the case.

Deutschmann's second case is that of a man of 42 years of age, whose vision had failed three days before. The left pupil was semidilated, and reactionless, both to light and convergence, and consensually; the external rectus was paralysed. Vision in each eye with $-0{\cdot}5$ sph. normal, colour sensation normal, fundus normal. Diplopia of a transitory nature for the past year. Syphilis 15 years previously. No knee jerk present. The following curious reaction was also present: On exposing the left eye to light there was a momentary well marked raising of the lower lid, while the upper lid remained stationary. The same happened though not to such a well marked degree on the right side, and it came off also consensually; it was obtained in daylight, but was far more marked in stronger artificial light; it did not occur during accommodation.

Deutschmann is unaware of any similar case in the literature, and points out that it cannot be inserted into that class of case where associated movements of the lids occur with changes in the width of the pupil, for in this case the width of the left pupil never varied; it never reacted at all. The reflex must depend on that zygomatic twig from the facial which innervates the orbicularis of the under lid. R. R. James.

Löwenstein, Arnold (Prague). **On the Bacteriology of Corneal Ulcers.** *Klinische Monatsblätter für Augenheilkunde*, August, 1910.

The rôle of the pneumococcus in the production of hypopyon ulcer has been established by the work of many, but the author suggests that variation in the frequency of infective causes

may be found for corneal ulcers, even as it appears to be for conjunctivitis.

In England and America the Koch-Weeks bacillus is a very frequent cause of conjunctivitis, whilst in Germany it is less common. Of 600 cases of conjunctivitis, Löwenstein found that bacillus only once. It is rarely found in Western Germany and still less often in Central and Eastern Germany.

In the exciting causes of corneal ulcers he finds a relative excessive preponderance of one organism.

Of 131 cases seen in two years, the bacterial findings, by smear and culture, proved to be as follows:—

70	cases	pneumococcus (3 mixed with diplobacillus).
21	,,	diplobacillus.
1	,,	streptococcus.
1	,,	bacillus fluorescens.
1	,,	bac. pyocyaneous.
1	,,	an actinomycosis.

In 36 cases no organisms other than staphylococci and xerosis bacilli were found.

On the clinical appearances of pneumococcal infections he notes that almost always the ulcer was a typical ulcus serpens. The diagnosis of the organism was best made by smears made from material removed from the edge of the ulcer. Smear preparations were frequently more characteristic than cultures, for in fluid media the polymorphism of the organism was marked, a whole series of farms from diplococci to streptococci being frequently present. The distinctive hæmolysis reaction described by Schottmüller (*Münch. med. Wochenschr.*, 1903, No. 21, v. 22) did not prove satisfactory in his hands.

He notes also that in several cases pneumococci that produced most distinctive corneal ulcers in man did not prove noxious to animals.

The sex and occupation of patients appear as follows. Women 22, men 48. Of all only 15 were under 45 years of age. 24 were coal or stone workers, 2 iron workers, 10 followed injuries from twigs, 7 from corn or grass blades. In only 18 was there no history of injury. Notwithstanding this it was evident that injury did not play a principal part in the causation seeing how common was injury in younger subjects without serious sequelæ.

Infection of the lacrimal sac was always looked for, but it was only manifest in 13 cases. The presence of the pneumococcus in the healthy conjunctival sacs of the labouring classes of Prague was found to be abnormally frequent: as many as 30 per cent. harboured pneumococci or streptococci.

These findings indicated that neither injury nor organism together, but some third factor—a reduced tissue resistance—was necessary to the production of the ulcer.

For the most part these ulcers were treated with the galvanocautery, the application being made to the spreading edge. Several cases were treated by puncturing the anterior chamber and extracting the coagulum. In one case the operation was performed seventeen times, the eye was saved, and after iridectomy fingers could be counted at 3 metres.

Iridectomy was performed for secondary glaucoma or more frequently, for optical purposes in 45 cases. Nine eyes were a total loss.

Six of the author's cases were in children, but the symptoms were not found to be of a more severe character than in adults; in this the observations differ from those recorded by Fuchs.

Of diplo-bacillary ulcers, it is noted that on certain counts a clinical distinction can be made from the pneumococcal ulcer. The diplo-bacillary ulcer is shallower, has a uniformly rounded margin, the edge is not excavated, and it has a yellowish colour; the floor is covered with debris. In 21 cases only five persons were younger than 45 years. Eight only had a traumatic history. Once the lacrimal sac was infected and the discharge therefrom showed many pneumococci whilst the ulcer smear was as rich in diplobacilli.

In the treatment of these ulcers it was found that oxycyanide of mercury 1 in 5000 and zinc sulphate 1 in 100 were equally efficacious. Since the bactericidal powers of these solutions is feeble, it is concluded success arises from their reaction on the tissues.

The paper concludes with lengthy reports of the four cases in which the rare organisms, streptococcus, B. fluorescens, B. pyocyaneus, and an actinomyosis were found as the apparently infecting agents.

N. Bishop Harman.

Noe Scalinci (Naples). **Parinaud's Conjunctivitis.** *La Clinica Oculistica*, 1909, p. 3739.

It is twenty years ago since Parinaud first described the peculiar form of conjunctivitis which is now always known by his name, and whose origin he attributed to some infection from the lower animals; since his original publication something like sixty cases have been described by various observers in various countries. As knowledge of the disease has increased it has become more difficult to maintain the theory of its causation first advanced by Parinaud, as seems to have been urged for the first time by Gifford; it is only fair to say, however, that a few observers cordially agree with Parinaud, and have in a number of cases brought forward facts which go to corroborate the original explanation, though in Scalinci's opinion these "facts" are not particularly convincing,—suggesting coincidence rather than an actual causal relation.

In one of the recorded cases examination failed to show any organisms, in at least one other the tubercle bacillus was to be found; in others staphylococci have been found, in one pseudo-diphtheritic bacillus, and in one a bacillus related to that of fowl-cholera. In regard to this however, it is right to mention that conjunctival inoculation of the organism and its introduction into the scarified cornea of a guinea-pig produced nothing even suggestive of the disease.

After discussing briefly the chief facts in all the recently published cases of Parinaud's disease Scalinci describes a case which he has himself observed.

The patient was a little girl of six, who was brought to him in the end of December, 1908, the left eye having been inflamed then for nearly three weeks. The first thing the mother had noticed was a swelling near the inner canthus with a little œdema of the lids, resembling an ordinary hordeolum. No suppuration occurred however, but the upper lid became rapidly swollen, red and œdematous; the pre-auricular and submaxillary glands became enlarged at this stage. There was no pain whatever, either of the lids or the glands, but the little patient was rather out of sorts and off her food. The only suggestive point in the history was that in the previous August the girl had been living in the country and had run about among the poultry; she had been among neither horses nor cattle, however.

On inspection the lower palpebral conjunctiva was found to

be strongly hyperæmic and to present a few rounded red nodules, all of which lay to the temporal end of lid and cul de sac. The upper lid was heavy and had some degree of ptosis, but appeared normal; it could not be everted, but under it at the upper outer part of the ocular conjunctiva there was discovered on lifting up the lid a single nodule of the size of a pea. On palpation there was found thickening of the whole outer two-thirds of the lids which were elastic and firm, almost hard. The skin over the swollen glands was not reddened, and there was no tenderness on palpation. Under mercury lotion, xeroform ointment and protargol the condition greatly improved in a few weeks. It was then that it became possible to see and to identify the papillary excrescences which are a characteristic of the disease,—growing from the tarsal conjunctiva, from a pin's head to a grape stone in size. The thickening of the lids broke up, so to speak, at certain points, giving an impression to the finger like that from a colony of chalazia. The general aspect was not unlike that of a moderate degree of trachoma.

Towards the middle of February the swollen glands began to lose their hardness, and before the end of the month, there being fluctuation, an incision was made; the discharge, taken under the strictest precautions, was tested with tubes of broth and agar. Similar inoculation tests of the conjunctival surface were also made, and a morsel of conjunctival tissue excised for examination. The local conditions had improved to a high degree when the case was lost sight of.

The three cardinal points of Parinaud's conjunctivitis were thus all present in this case, the unilaterality, the characteristic efflorescences in the palpebral conjunctiva along with integrity of the cornea, and the adenitis on the side of the affected eye.

The morsel of conjunctival and other tissue excercised as stated above showed what always is to be found, namely, papillary hypertrophy and severe inflammation of the tarsus with destruction of certain of its elements. From the discharge from certain of the little nodules of the conjunctiva Scalinci was able to identify streptococcus and staphylococcus pyogenes aureus, and also from the conjunctival surface; in the tissue itself no organisms could be found.

Scalinci offers some observations upon the clinical and other aspects of the case which he has described and of which we have noted the essential points. So far as the ordinary exam-

ination of the patient is concerned the appearance which struck him most was the infiltration of the outer two-thirds of the lids; it felt almost as though a plate of metal of triangular form had been let into the tissues: this seems to be far from a usual condition of the lids in this disease; it is possible that the youth of the patient may have had some influence in this relation. Another matter which particularly struck him was the existence of a nodule in the bulbar conjunctiva as noted above, this also is quite a novelty in cases of this form of malady, but fortunately the nodule gradually disappeared while the patient was still attending hospital. As regards the bacteriology it is doubtful if the discovery of the streptococcus and the staphylococcus takes us very far towards the complete understanding of the disease. It is difficult to suppose that either of these could be the cause of a unilateral disease, considering the ease with which these microbes can be conveyed to the other eye, while Parinaud's disease is essentially unilateral; but if we assume that for some unknown reason the organisms had penetrated more deeply than usual into the tissues we may perhaps have a clue to the solution of this difficulty and to that of the occurence of the lymphadenitis also. In conclusion Scalinci advocates a change of nomenclature to Parinaud's *disease*, indicating that in the syndrome or group of symptoms we have something more than a mere conjunctivitis with peculiarities. The value of the paper is much enhanced by the beautifully executed illustrations of the pathology. W.G.S.

THE OPHTHALMOLOGICAL SOCIETY OF THE UNITED KINGDOM.

Thursday, October 20th, 1910.

Dr. G. A. Berry, *President, in the Chair.*

A Case of Peripheral and Central Bulging of the Cornea.—Mr. Markus.

He thought the condition was due to a progressive degeneration first at the periphery and later extending to the central regions. He also showed a case of unilateral retraction of the upper lid and von Graefe's sign.

A Case of Endothelioma of the Lacrimal Gland.—Mr. C. Blair.

The patient had been shewn in June last, subsequent partial excision and microscopy had indicated the growth was not malignant. The whole growth was excised 4 months ago and so far there was no recurrence.

Pathological Features of a Case of Marginal Keratectasia formerly shown by Mr. J. H. Fisher.—Mr. George Coats.

The essential changes were loss of the superficial lamellæ in the

affected periphery and replacement by loose granulation tissue Descemet's membrane was grossly hypertrophied, but its poor quality was indicated by numerous split flattened ones with new hyaline material.

The condition had been variously considered degenerative and inflammatory. Mr. Coats concluded that a combination of these two explanations was the correct view—*i.e.*, products of degeneration set up a low form of inflammation, or a low form of inflammation induced degeneration.

Mr. Treacher Collins thought the splits in Descemet's membrane and the œdematous epithelioma indicated leakage of aqueous in such cases.

Mr. Markus thought the case he had shown this evening, where there was a very large area of cornea involved without inflammatory symptoms, showed that degeneration was the primary factor.

Mr. Fisher said, in dealing with the case, the pathological features of which had been described by Mr. Coates, he had incised the bulging cornea and excised the thinned tissue with scissors. Healing was exceedingly slow, but ultimately the anterior chamber formed and vision now was $^{6}/_{12}$. He thought the thickening of Descemet's membrane was compensatory.

An Unusual Instance of Colloid Excrescences of the Membrane of Bruch. —Mr. George Coats.

The eye was from a patient, æt. 58, who had achondroplasia and double glaucoma. In the right eye the media were clear, the fundus was seen strewn with flat, scaly, irregular, white and grey areas, with a slightly wavy surface, and with a distinct glitter on moving the light. The borders were sinuous and rimmed with pigment. The choroid was degenerate. The left eye was blind with the retina detached, so it was excised. Sections show that the areas were due to an aberrant type of colloid excrescences of the membrane of Bruch. The ordinary round nodules were seen, and in addition flakes and spongeworks of colloid. In this eye it was noteworthy that the corneo-iridic angle was quite free and there was no apparent obstruction to drainage. He thought the glaucoma possibly due to a disproportional quantity or altered quality of the secretion.

N. Bishop Harman.

Clinical Evening, November 10th, 1909.

Mr. Hartridge *in the Chair.*

Sympathetic Ophthalmitis with Recovery.—Mr. G. Winfield Roll.

The patient was a boy aged 14 whose right eye was severely cut by broken china. He was not seen until eight days after the accident. A wide iridectomy was performed to relieve the prolapse. The other eye became soft, K.P. and posterior synechiæ appeared, but the process suddenly ceased under the influence of atropine and hot bathing. Both eyes are now quiet.

Atypical Coloboma of the Iris and Lens with Persistent Mesoblastic Strand.—Mr. George Coats.

Boy, æt. 12, left eye normal, right eye slightly small, with coloboma of the iris outwards and downwards, the superficial layers of the iris appear deficient in other parts.

Corresponding with the coloboma is a notch in the lens equator, and projecting to reach this notch is a triangular patch of fibrous tissue springing from the ciliary body. The zonula is present at the site of the coloboma, but its fibres are altered in direction and those reaching the lens notch spring fan-shaped from the fibrous patch. The fundus shows a coloboma of the choroid. Coats held this case supported the theory of Hess that colobomata of the iris and lens were caused by undue prominence and persistence of a strand of fibrovascular capsule which prevented growth of the iris. He showed sections of eyes in which this aberrant band could be traced, plainly obstructing the iris.

A Case of Recurrent Melanotic Sarcoma of the Conjunctiva shown in November, 1903.—Mr. W. H. Jessop.

The growth was excised in 1903, but since that date there had been appearance of several pigment patches in the conjunctiva. These had been excised and sections showed a malignant character. Recently a definite though small tumour had grown. He proposed to watch the cases still further before resorting to exenteration.

A Case of Solitary Tubercle of the Choroid shown in May, 1903.—Mr. W. H. Jessop.

The young lady had severe choroidal and scleral tubercle; the diagnosis had been established by bacteriology and inoculation. Now recovery was almost complete the traces of 'obsolescent' tubercle were just like the early scarring of retinitis proliferans and singularly free from pigment. Vision was $^{6}/_{12}$.

Kerato-irido-cyclitis in a Man at. 22.—Mr. John Hern.

The disease was considered not due to syphilis, but its exact nature was not determined. It ran a very severe course which was only checked by the performance of peritomy.

A Simple Projection Polariscope for Use in Testing Colour Perception. Mr. J. H. Tomlinson.

The spectrum in single or multiple lines was projected upon a screen, the whole or parts of one or several spectra could be shown for naming or matching, or the adjustment of the band could be left to the patient who might be required to measure off any definite colour. A patient with tetrachromic perception was shown and tested before the audience.

A New Instrument designed to facilitate Herbert's Operation for Sclerotomy.—Mr. N. Bishop Harman.

He described this as "Twin Scissors," the scissors made two parallel

cuts in any tissue placed between its blades, each cut was 4 mm. in length and separated by 3 mm. In operating a flap of conjunctiva was turned forward, the anterior chamber entered through a scleral cut made by a keratome; then the male, a longer blade of the twin scissor, was passed under the sclera, pressure of the handles brought down the parallel female blades and the two lateral cuts of Herbert's tenotomy were made simultaneously.

Four eyes had been operated with the scissors. One a woman of 64 years was shown, in both of her eyes there was ample filtration at the site of the operation.

Three Cases where there had been Serious Damage to Sight following Hæmorrhage.—Mr. R. Foster Moore.

In each case the vessels of the fundus were thin and thready and the optic discs pale.

One case, a male æt. 41, suffered from bleeding piles and had become seriously anæmic. Red corpuscles 3,900,000, hæmoglobin 40 per cent., R.V. fingers, L. $^{3}/_{60}$, with central scotomata. Hæmorrhage had been stopped by operation with improvement in general condition. Red corpuscles 6,200,000, hæmoglobin 106 per cent.

Another case, a woman æt. 34, lost much blood through a miscarriage. Vision failed in 10 days; for 14 days she had no p.l. Recovery then set in and R.V. = hand movements, L.V. $^{6}/_{18}$.

The third case was a woman æt. 53 suffering from hæmatemesis. 15 hours after the bleeding the left sight went; 3 days later she was totally blind. After four months the only vision recovered was one very small area of the temporal field of the right eye.

A Case of Neoplasm involving the Iris.—Mr. F. A. Juler.

The patient, a woman æt. 39, had recently noticed her left eye change. A brown mass involving the iris and rising up behind it into the pupil was found on examination. It had been punctured lest it might be cystic, but it proved to be solid. It was proposed to remove the eye.

A Case of Injury to the Eye with Hyphæmia persisting 9 months.—Mr. Frank Hewkley.

The eye had a cataractous calcareous lens and adherent iris. T. minus. No p.l.

Fibrous mass at the Disc with Substitution of Normal Retinal Vessels by Cilio-Retinal Vessels.—Mr. Cruise.

He thought the condition due to a subhyaloid hæmorrhage at the site of the disc. The fibrous mass was shrunken and organised blood clot and the pressure of this had been followed by enlargement of the cilio-retinal vessels. There was a history of injury.

Mr. Coats agreed with this explanation. Mr. Mayou concluded that the condition was a congenital malformation and that the injury was an unrelated coincidence.

N. Bishop Harman.

SERIAL

RE
1
C43
v.29

The Ophthalmic review

GERSTS